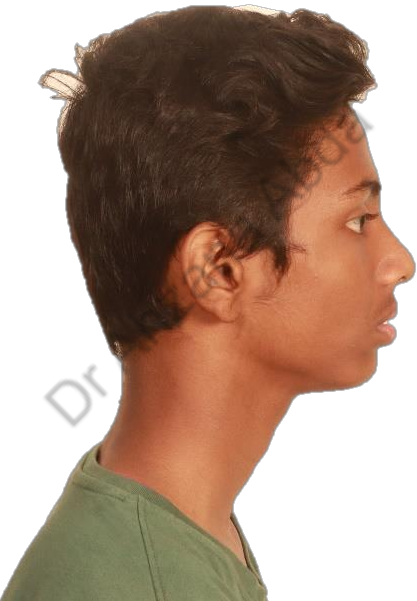

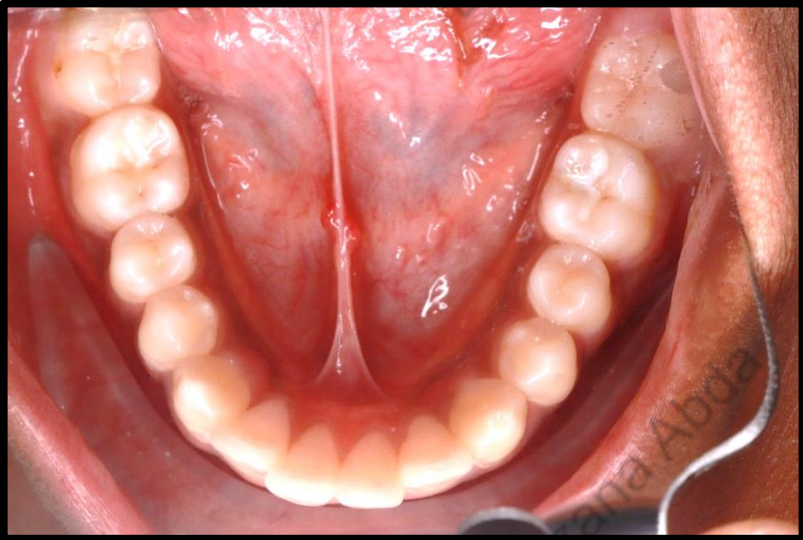
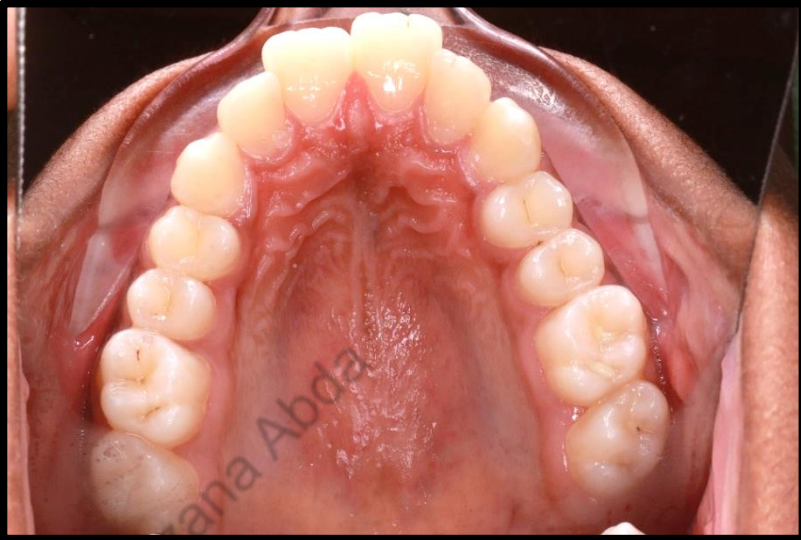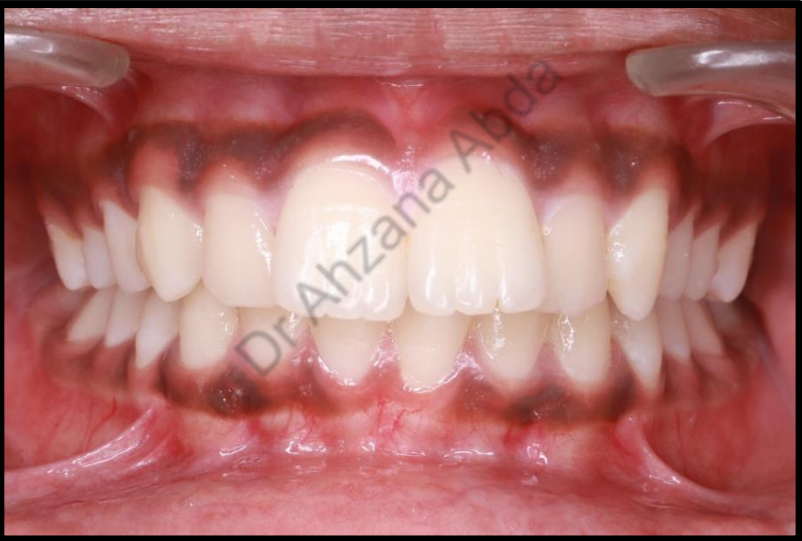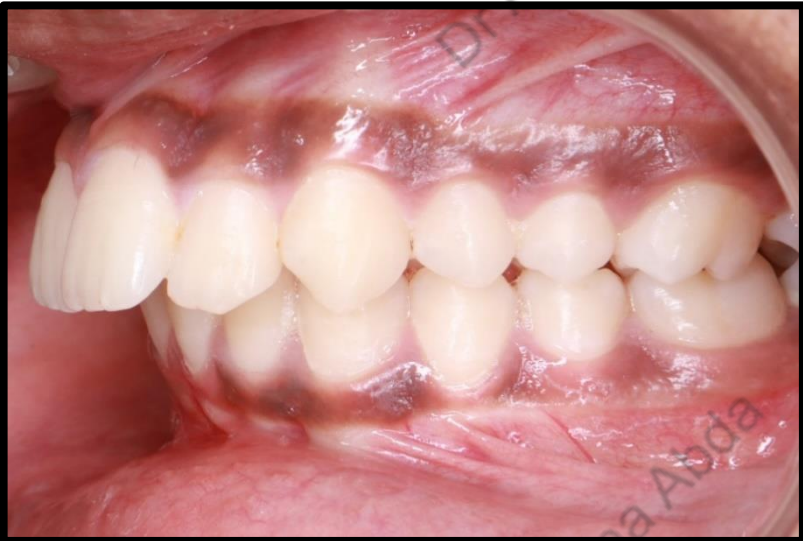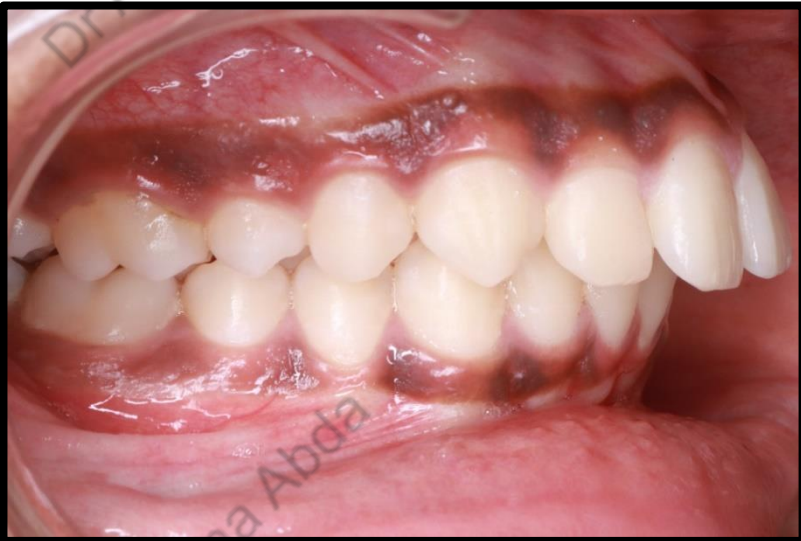# CASE I

**SWAYAM 15/M**

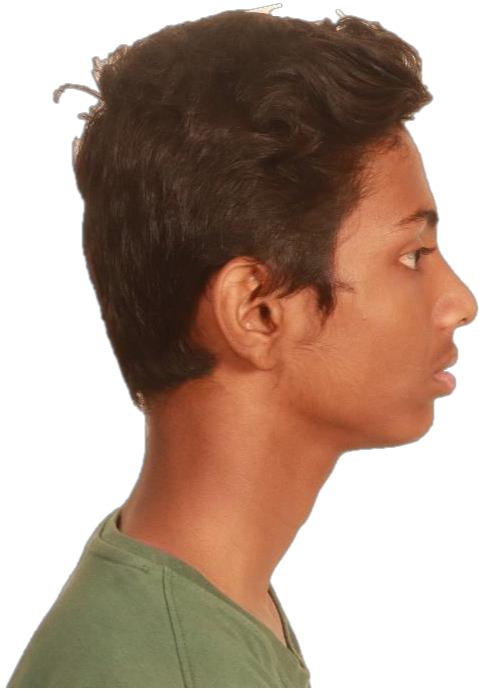**PRE TREATMENT EXTRAORAL**



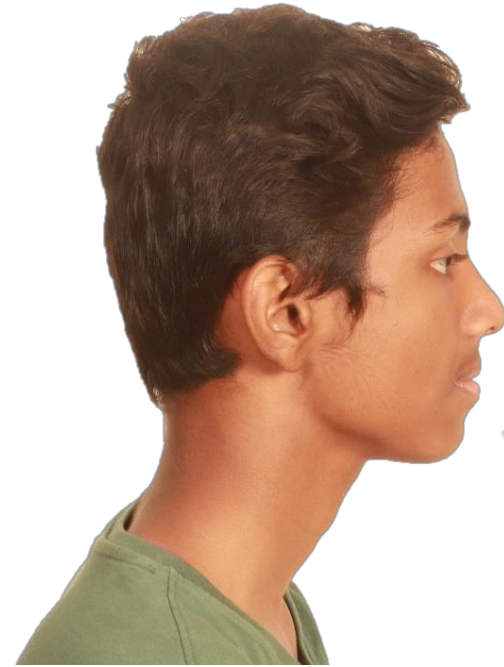**PRE TREATMENT INTRAORAL**



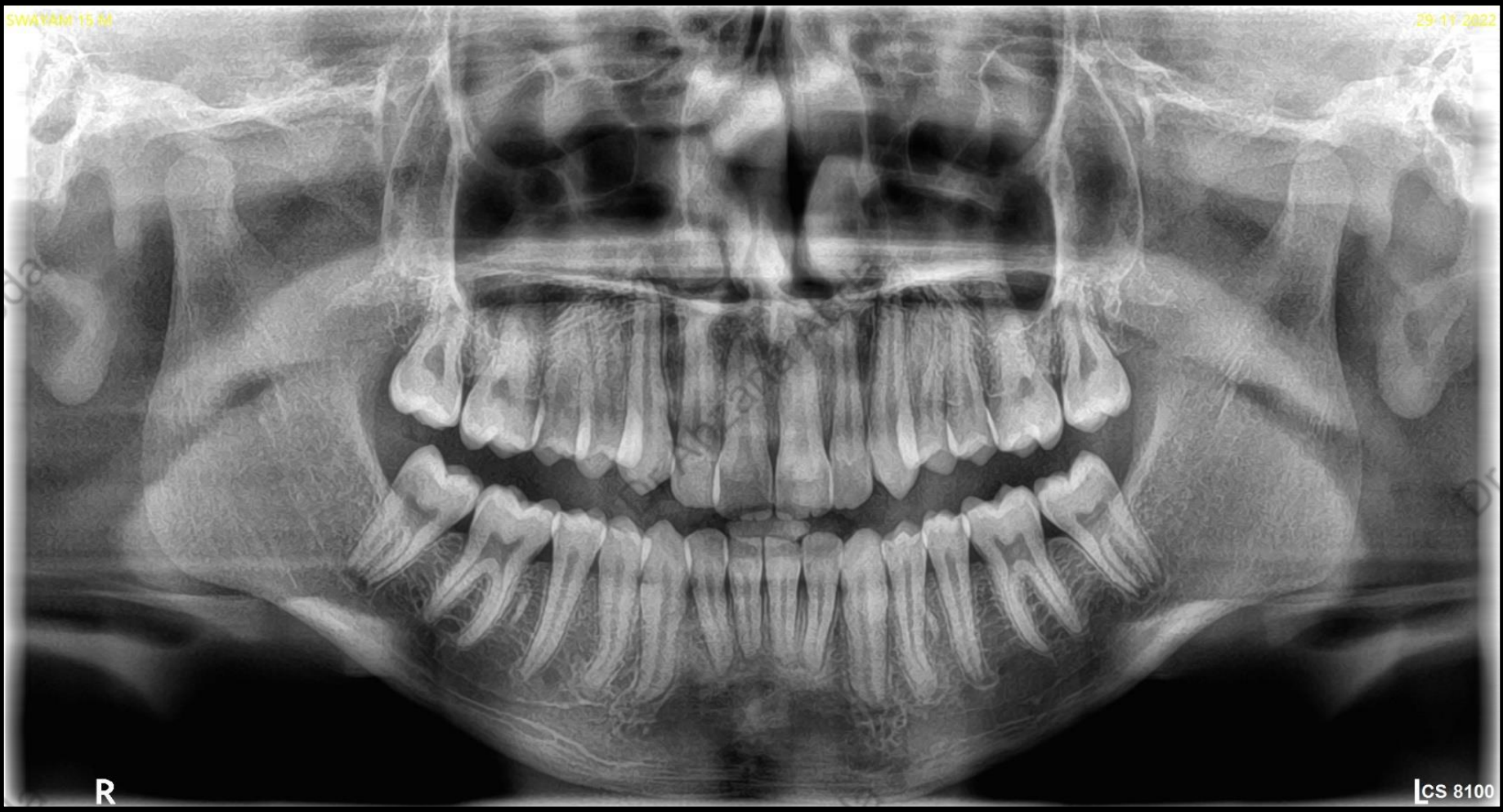**PROFILE**



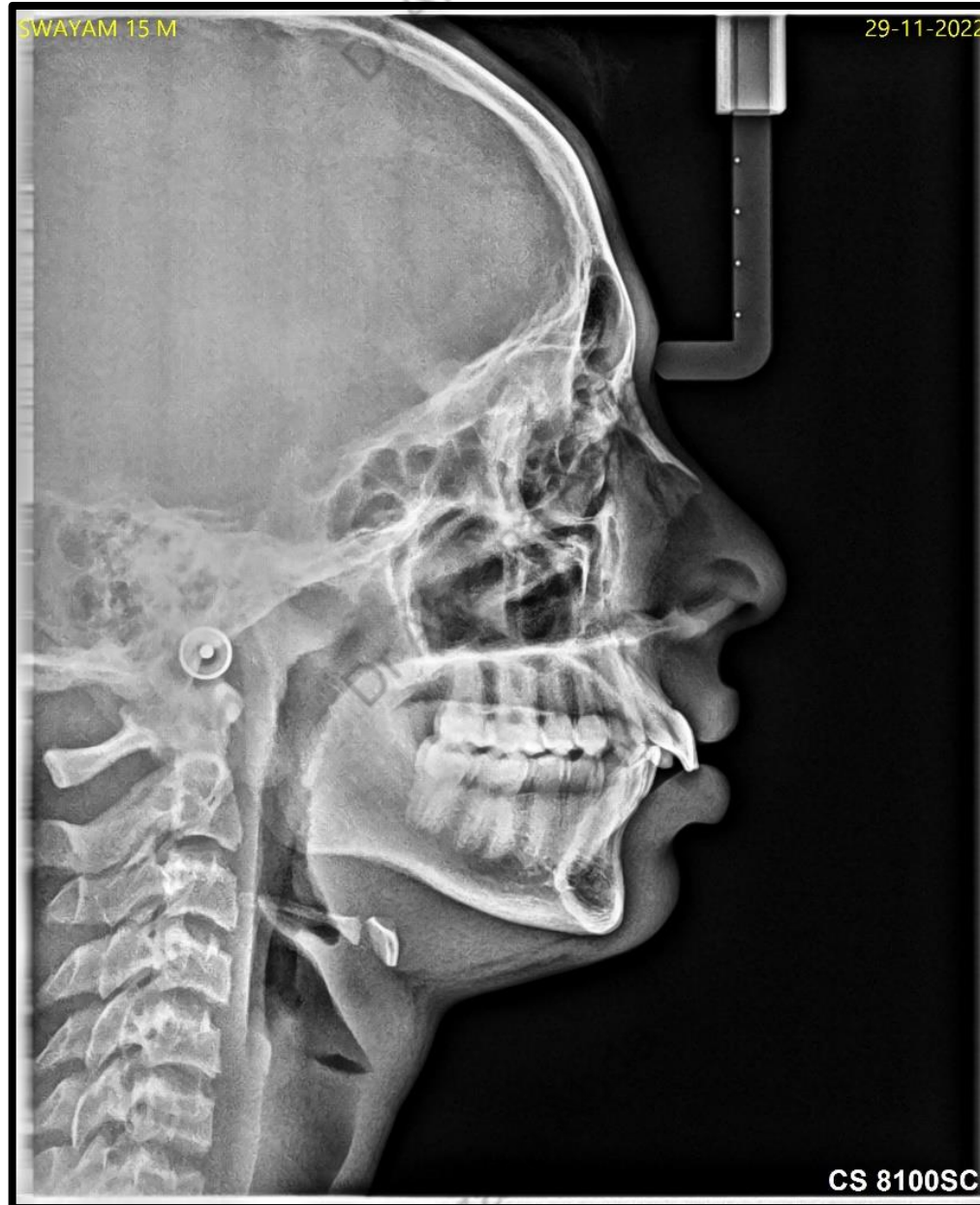
**VTO**



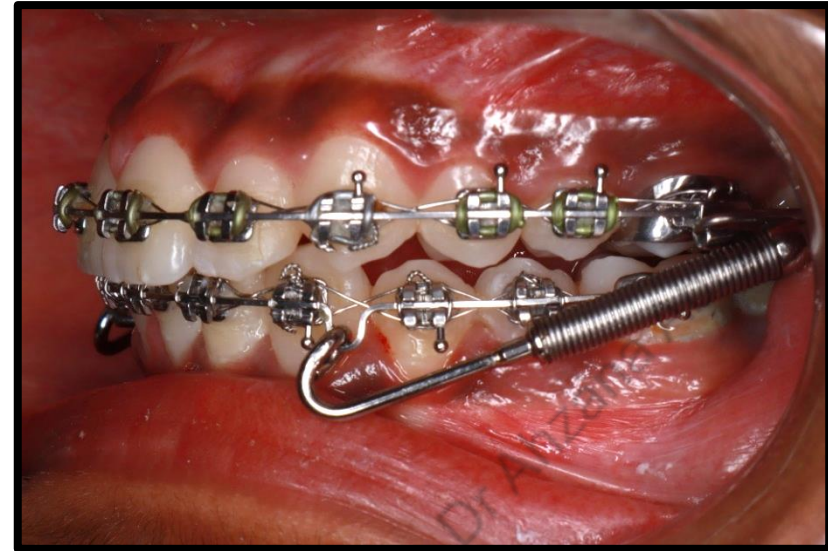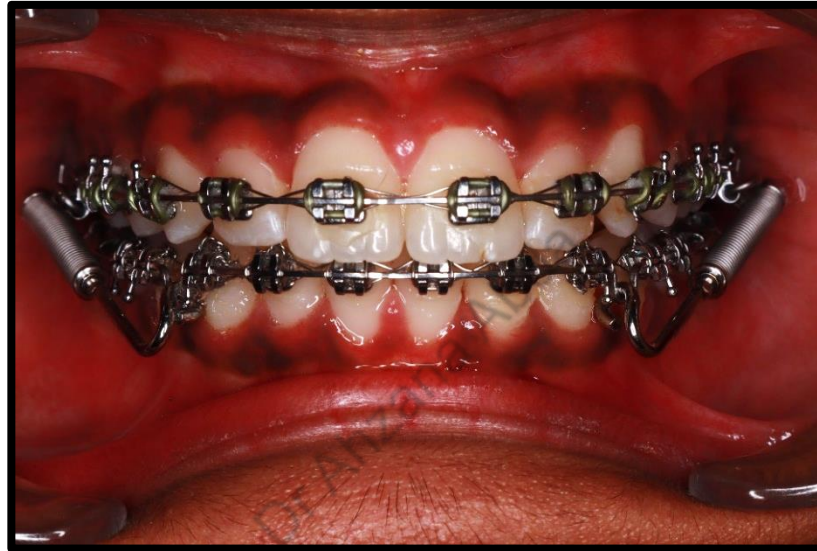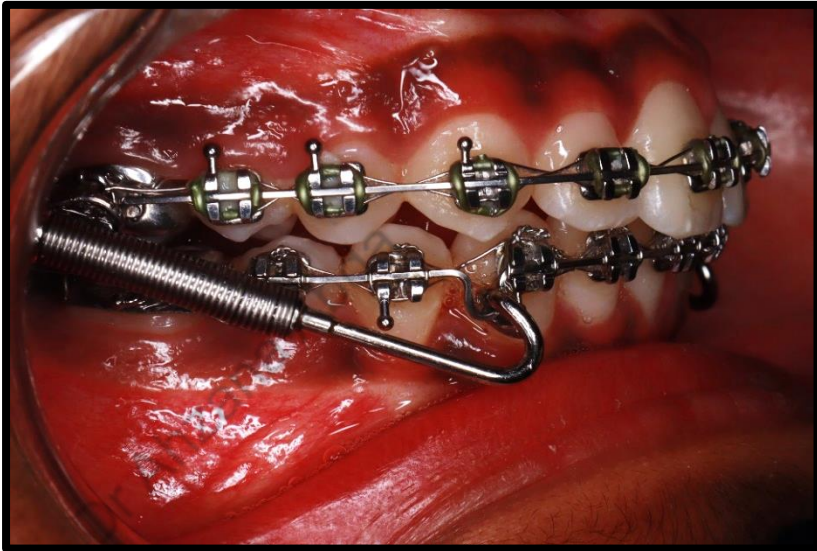**PRE TREATMENT OPG**



# PRE TREATMENT LATERAL CEPHALOGRAM



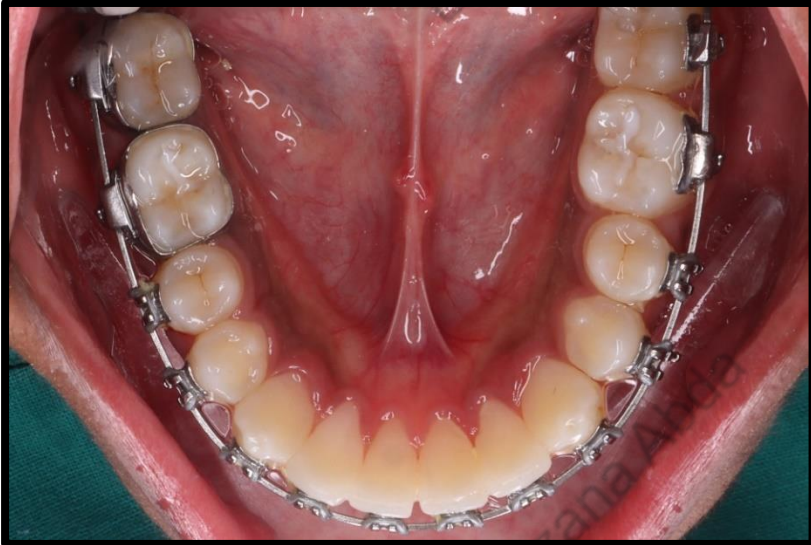
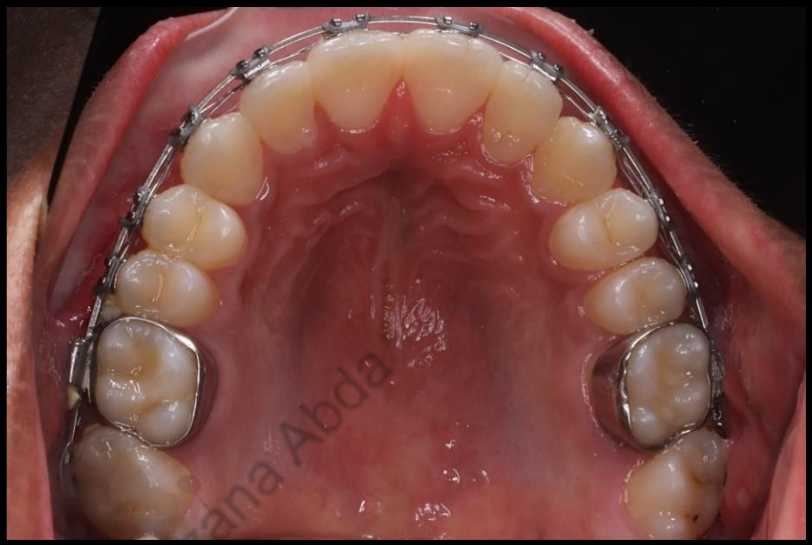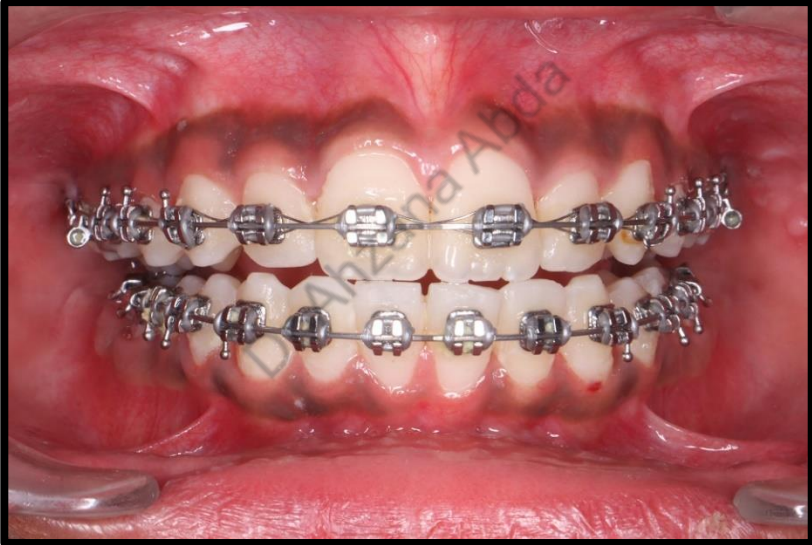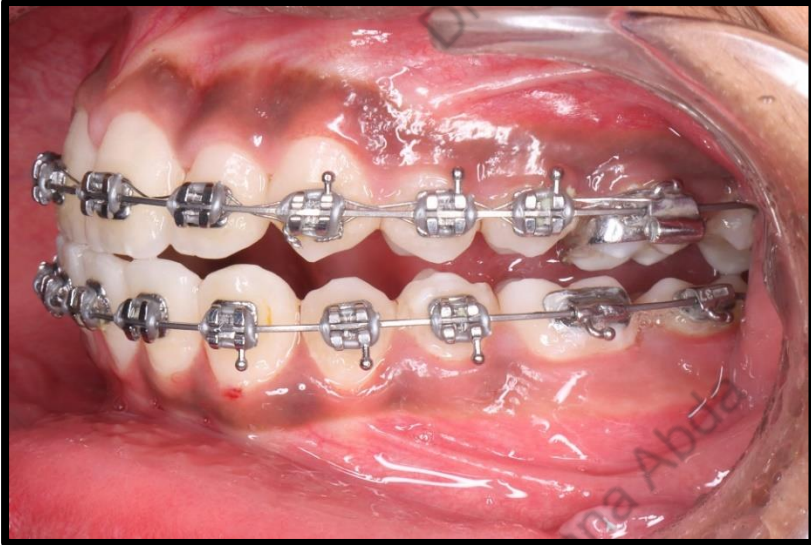
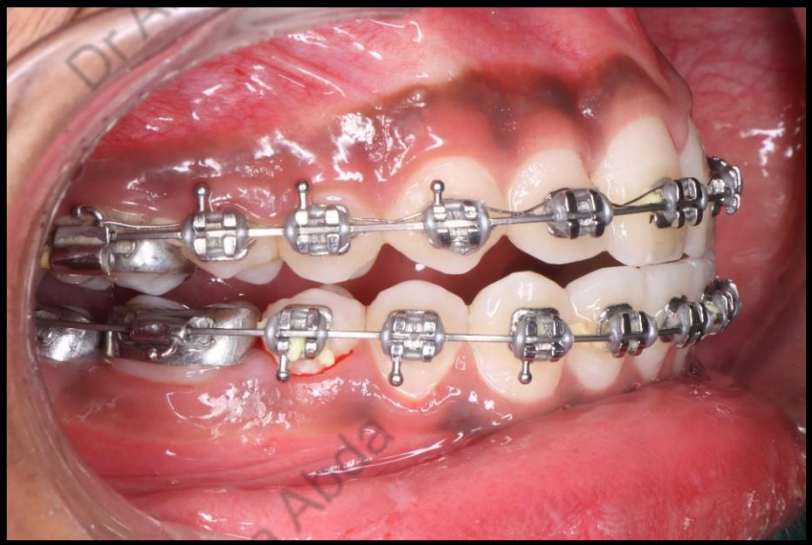
# FORSUS PLACEMENT



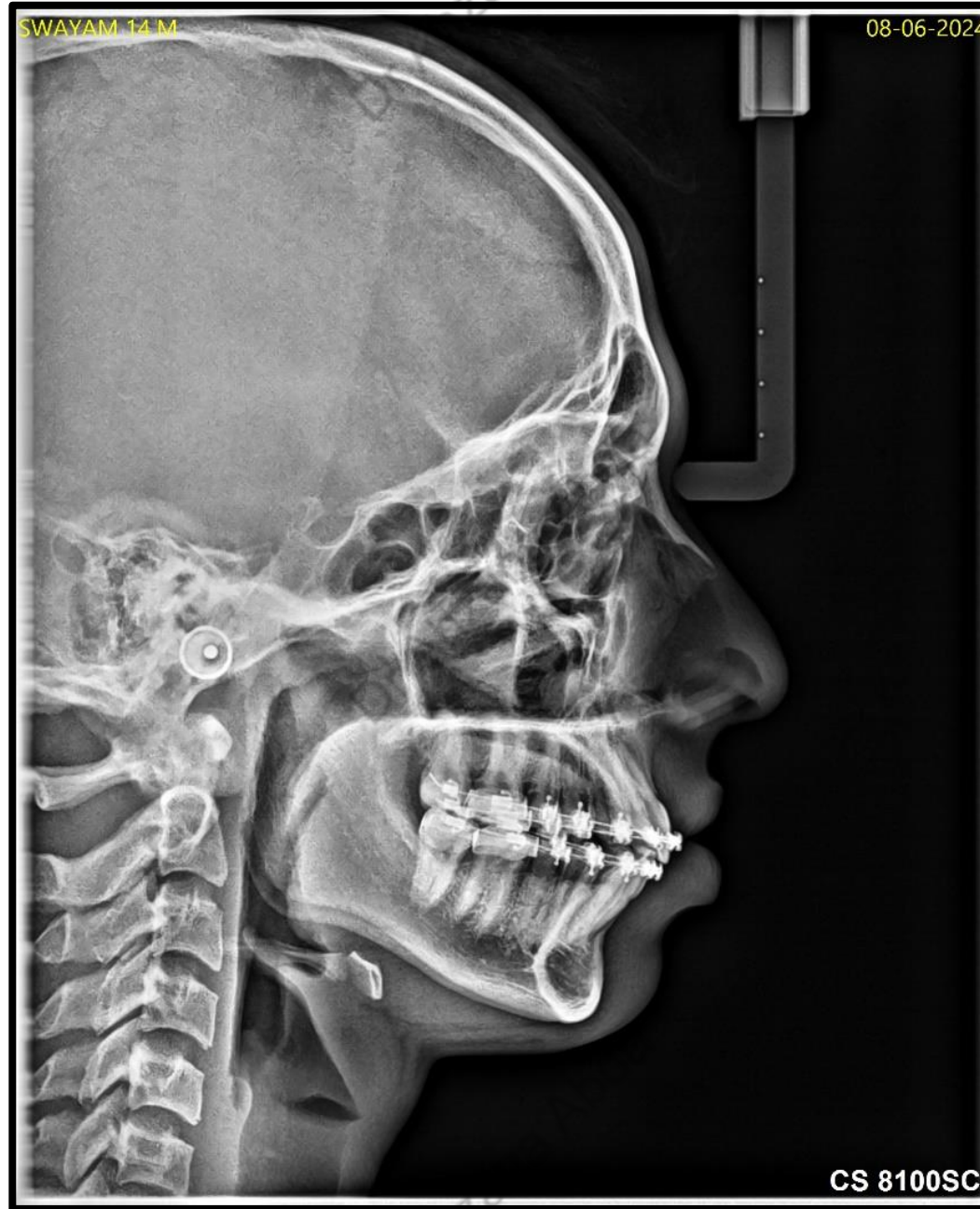
**POST-FORSUS EXTRAORAL**



**POST –FORSUS INTRAORAL**



# POST-FORSUS LATERAL CEPH

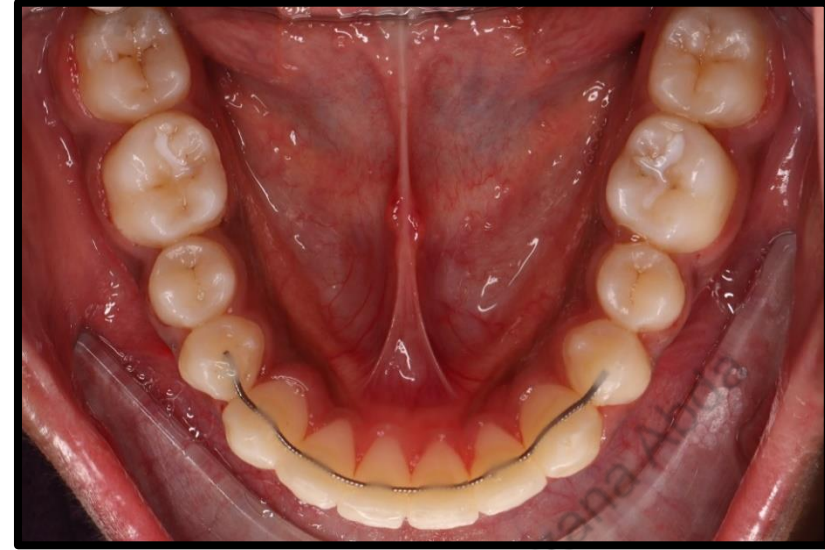
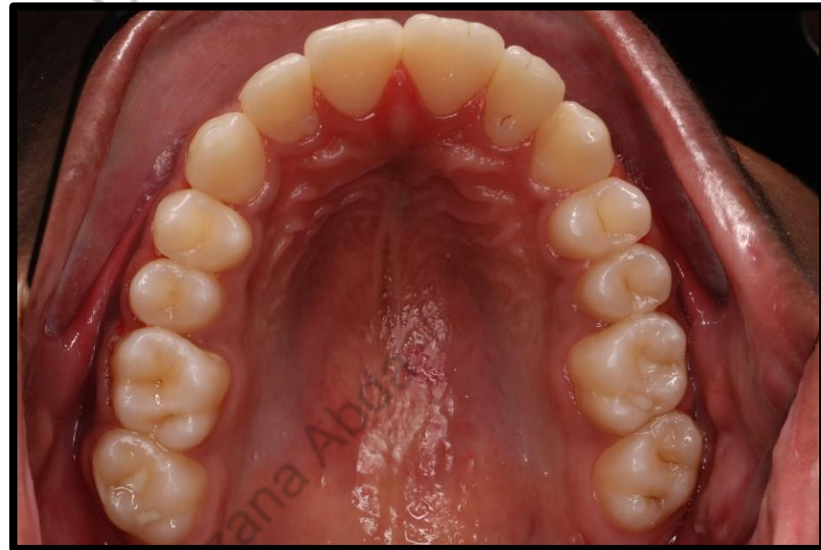
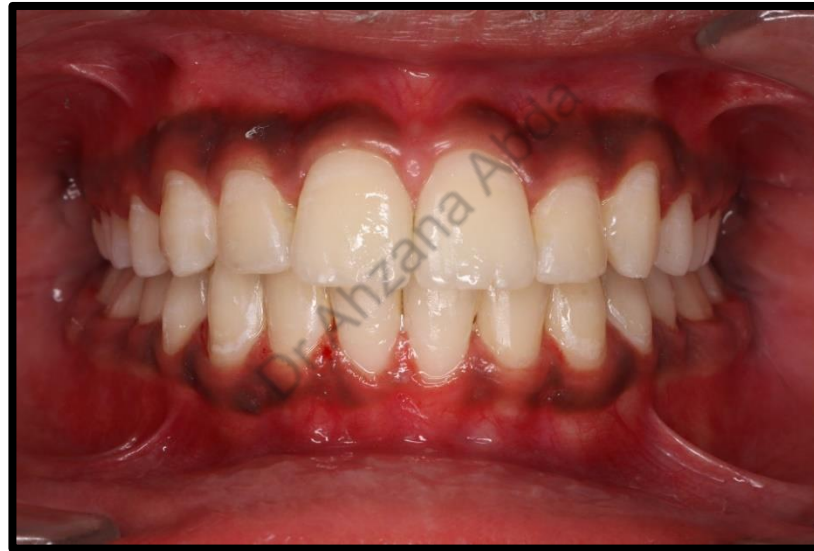
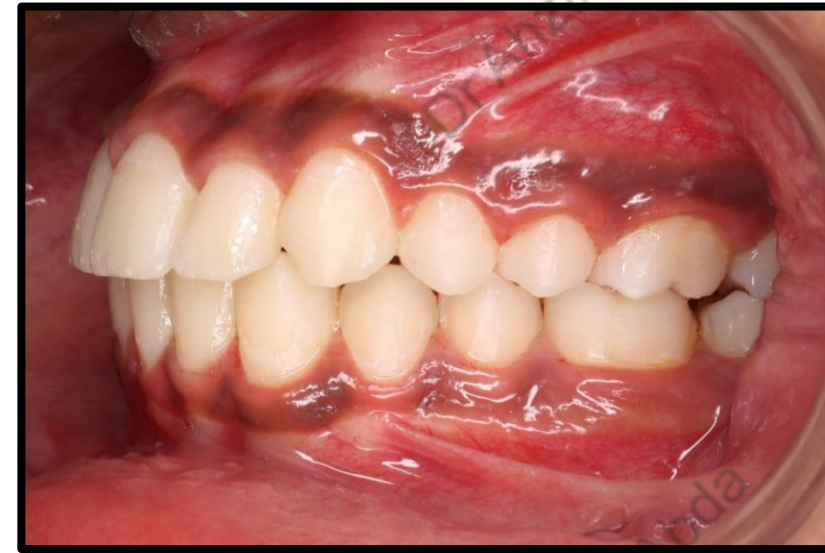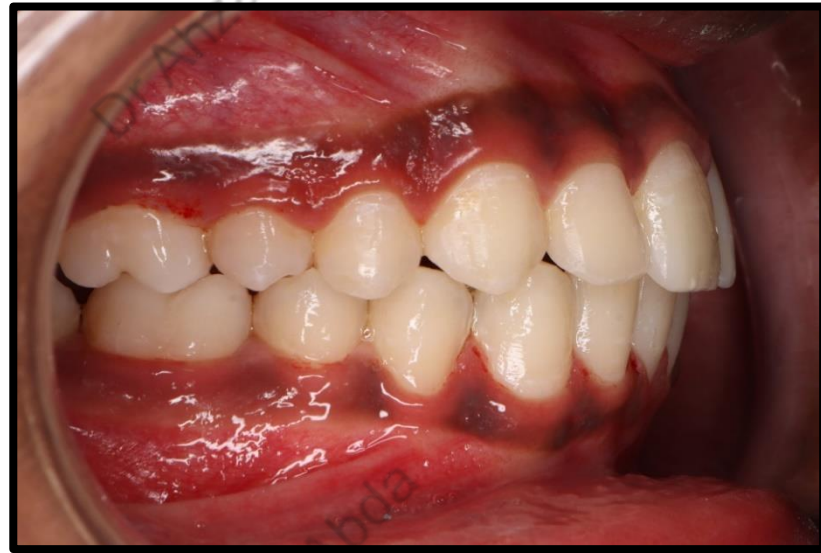CS 8100SC

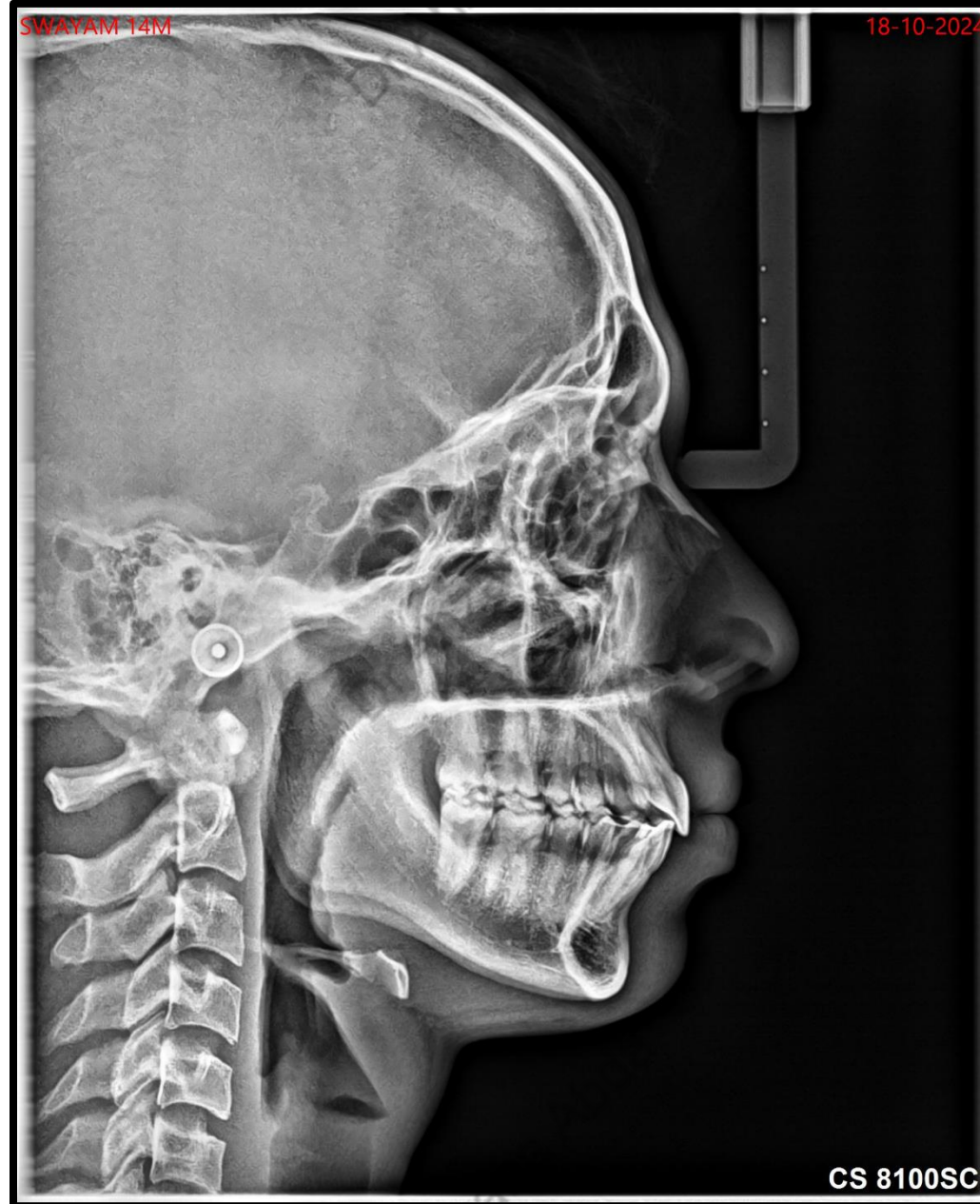**POST EXTRAORAL**



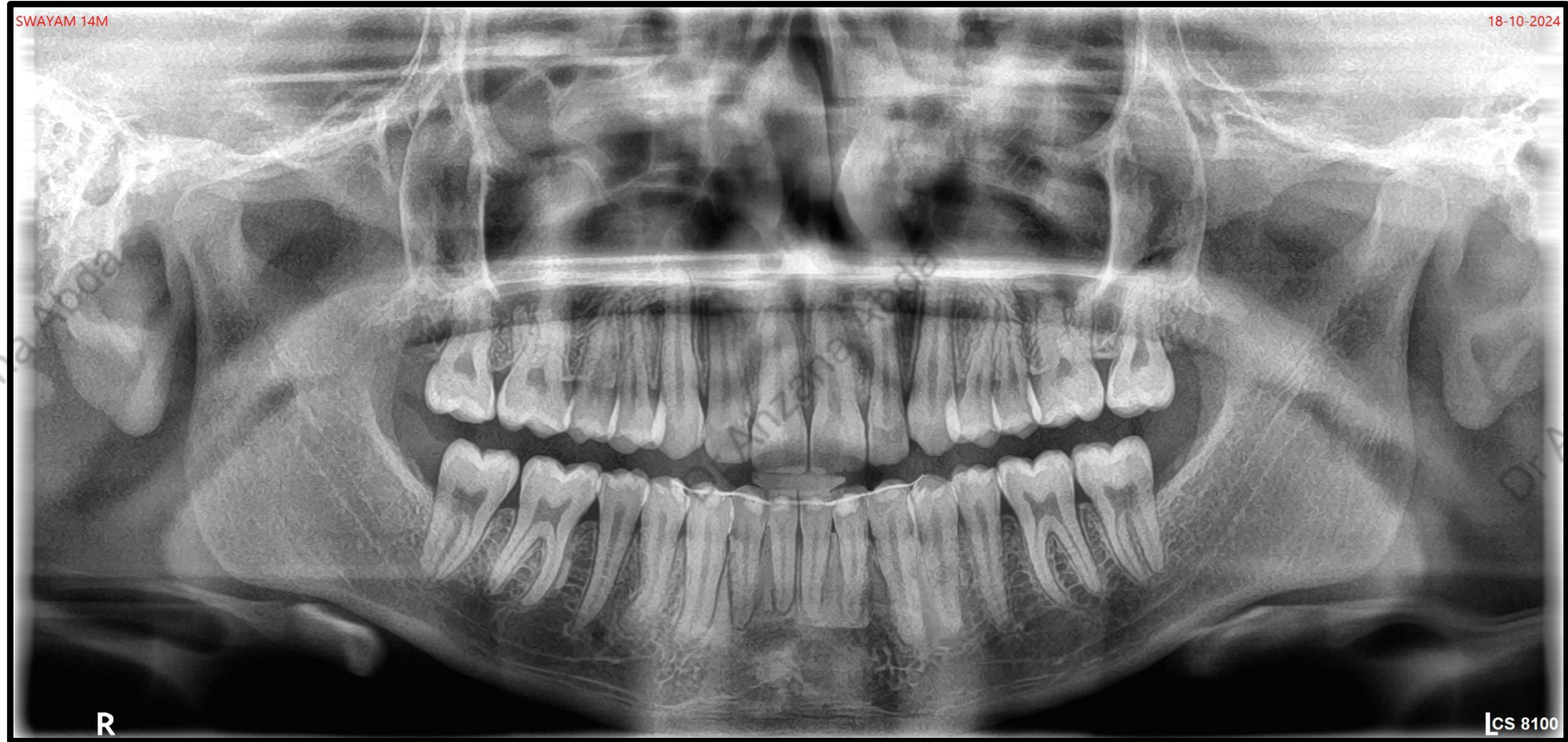# POST INTRAORAL



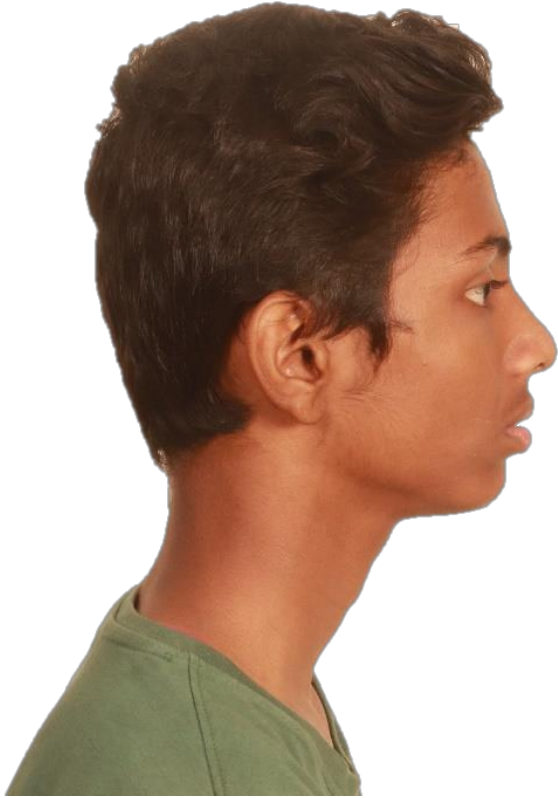# POST-TREATMENT LATERAL CEPHALOGRAM



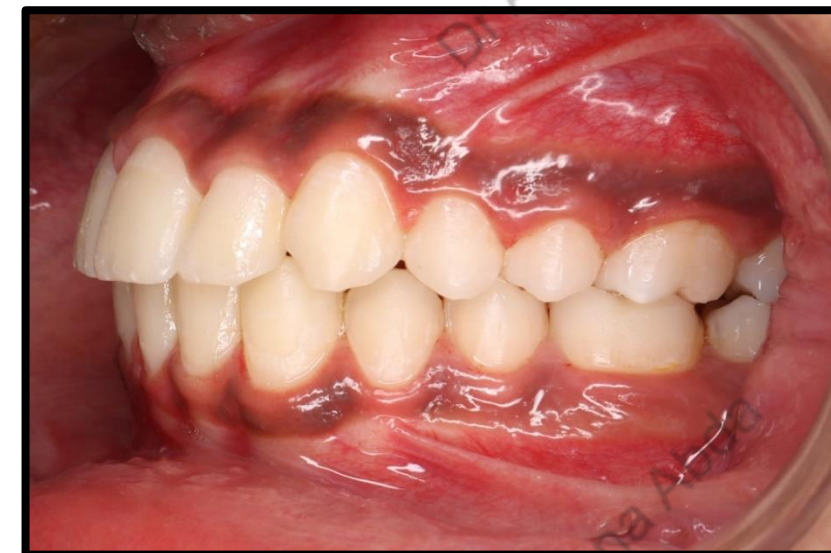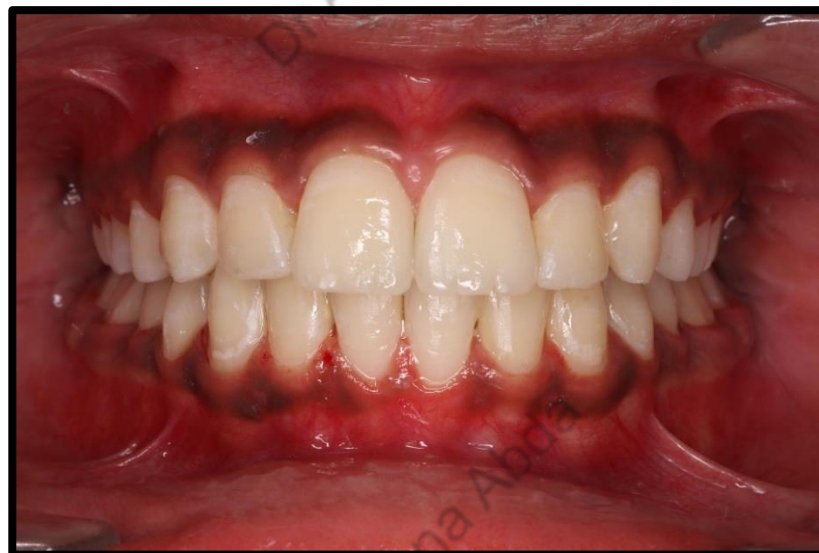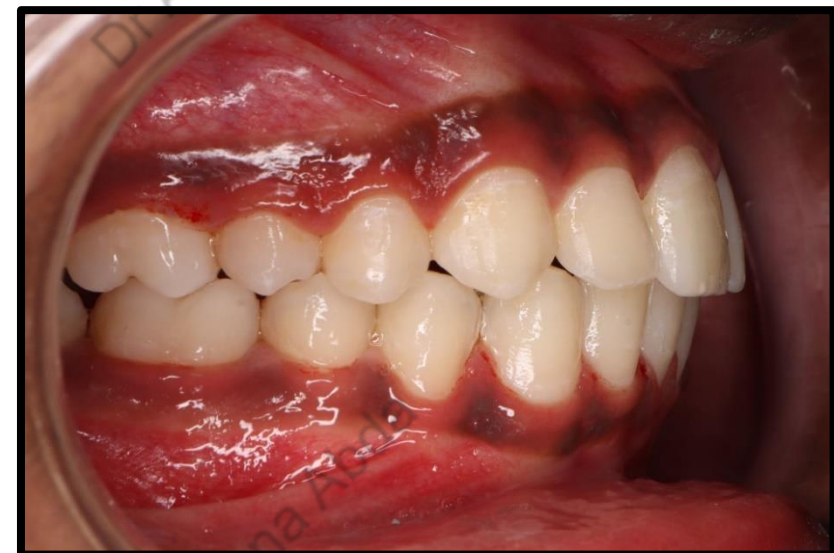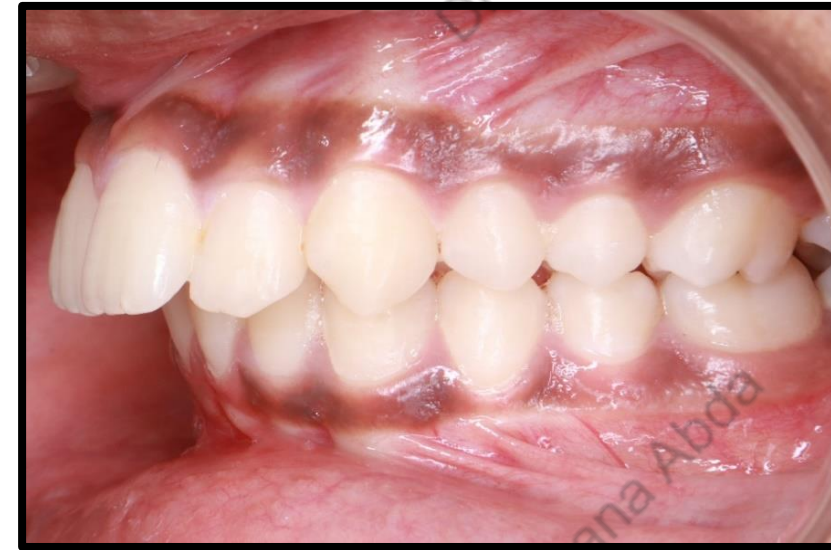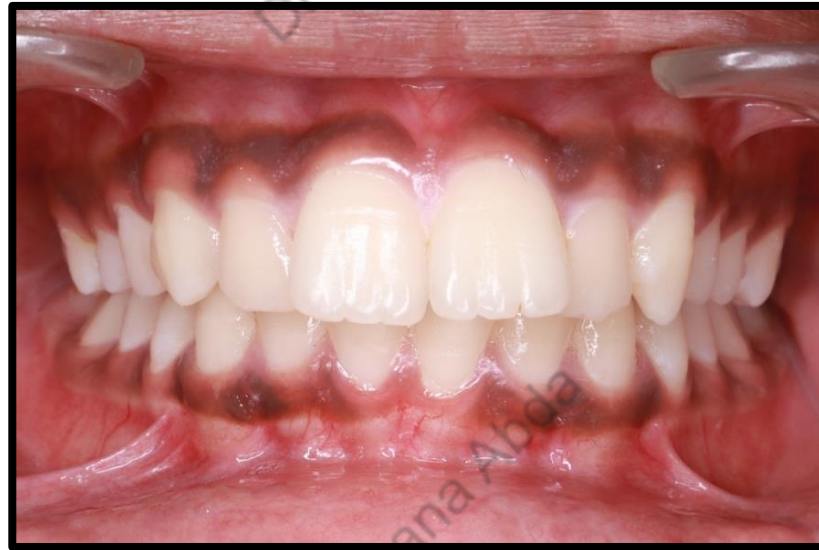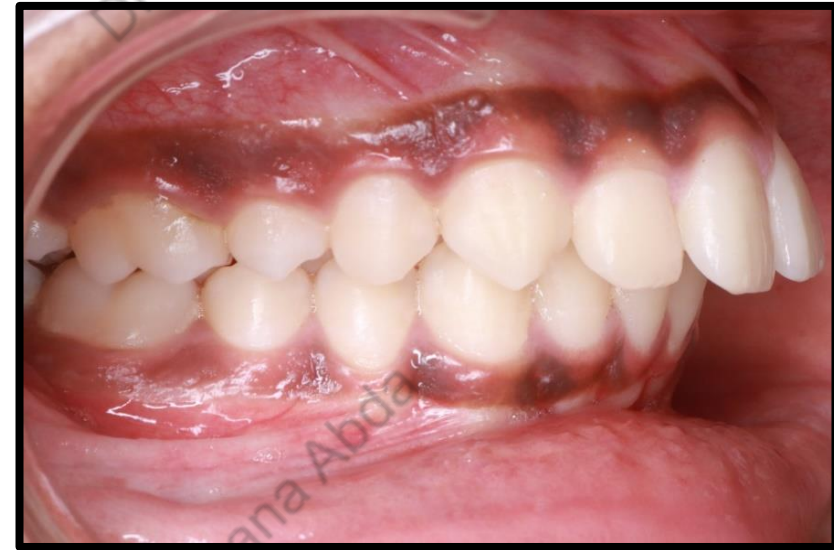# POST-TREATMENT OPG



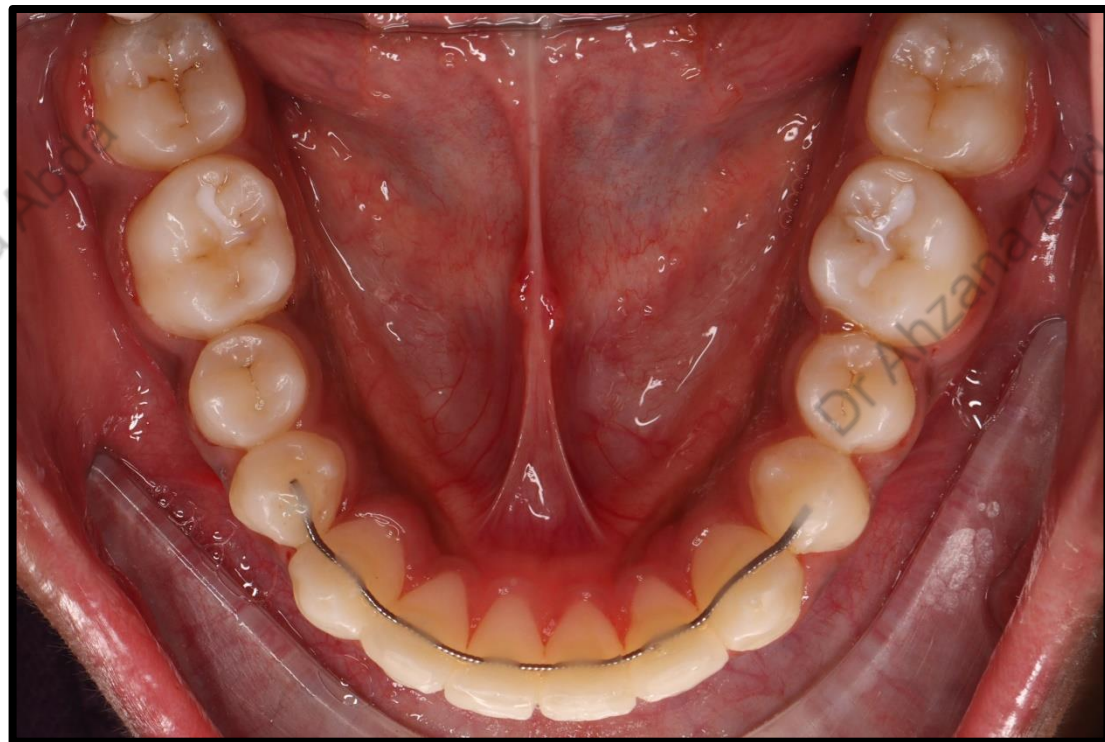
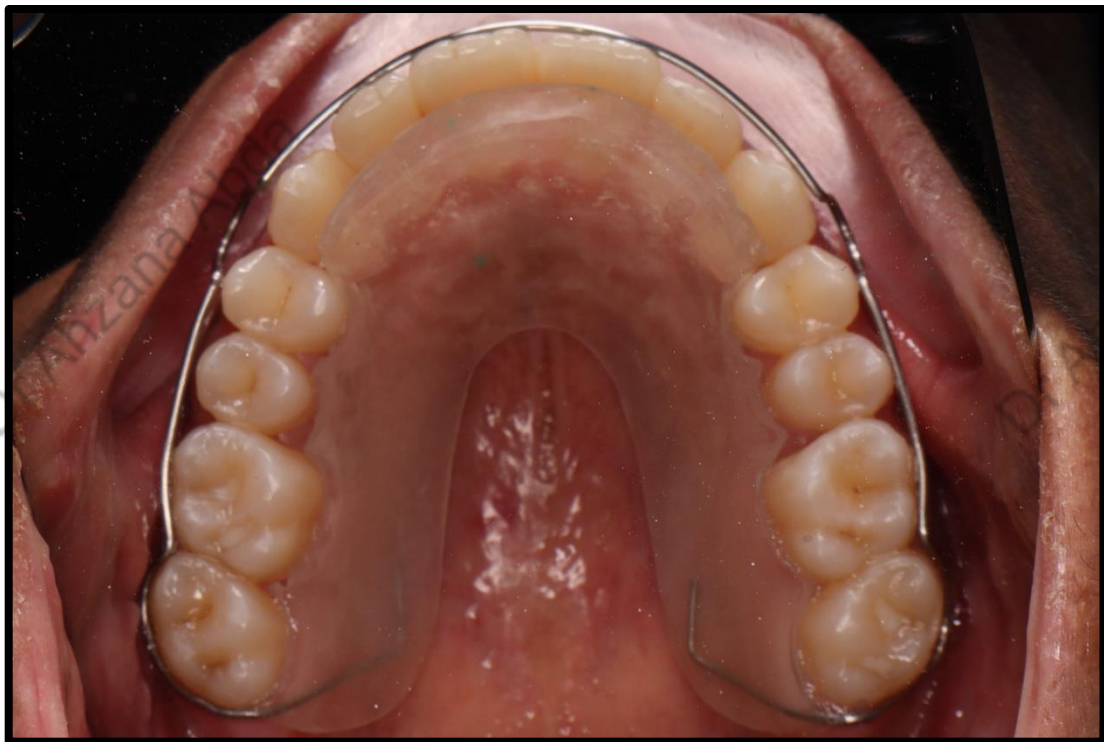## PRE-POST COMPARISON



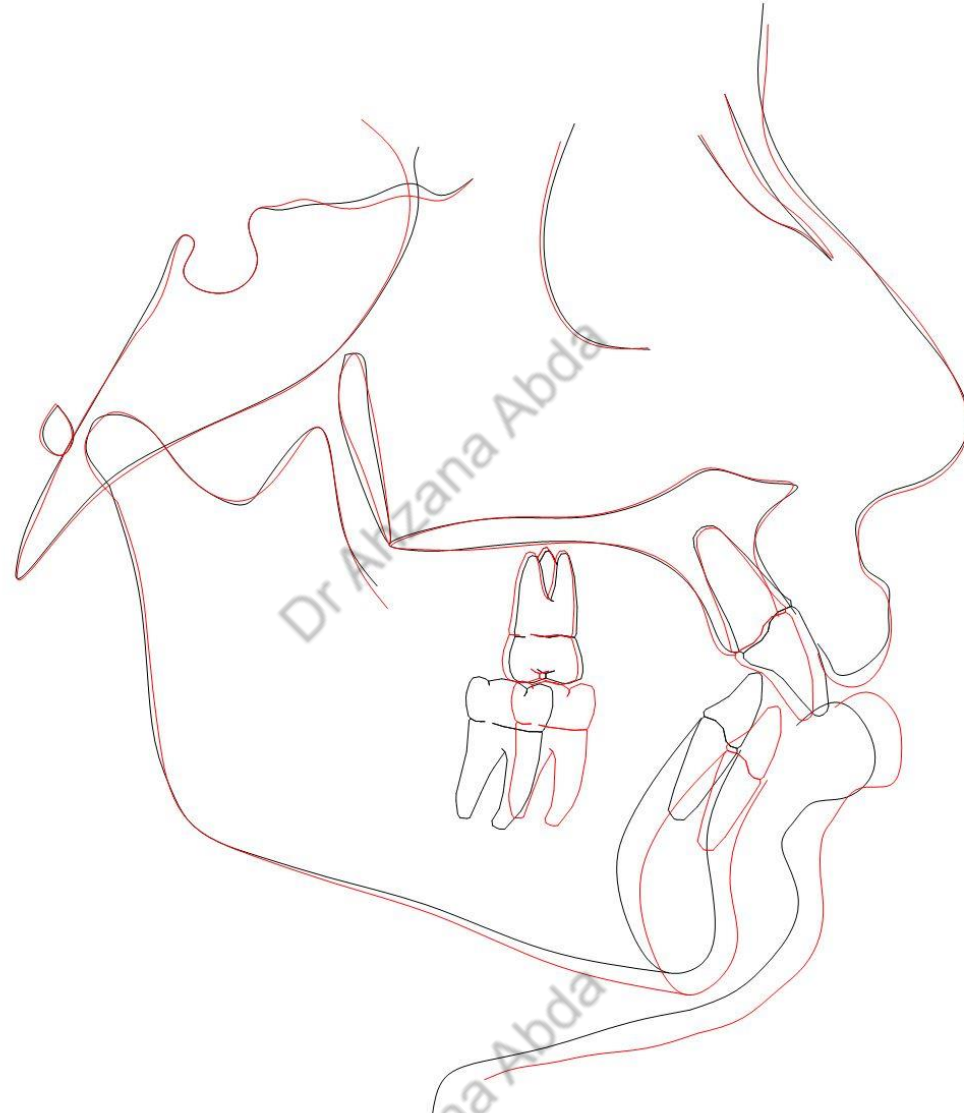
**PRE -POST INTRAORAL**



# RETAINER



# SUPERIMPOSITION



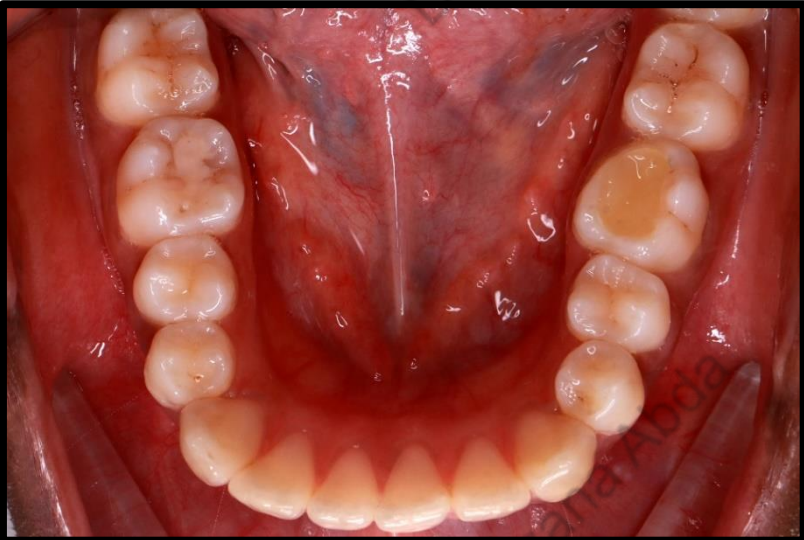
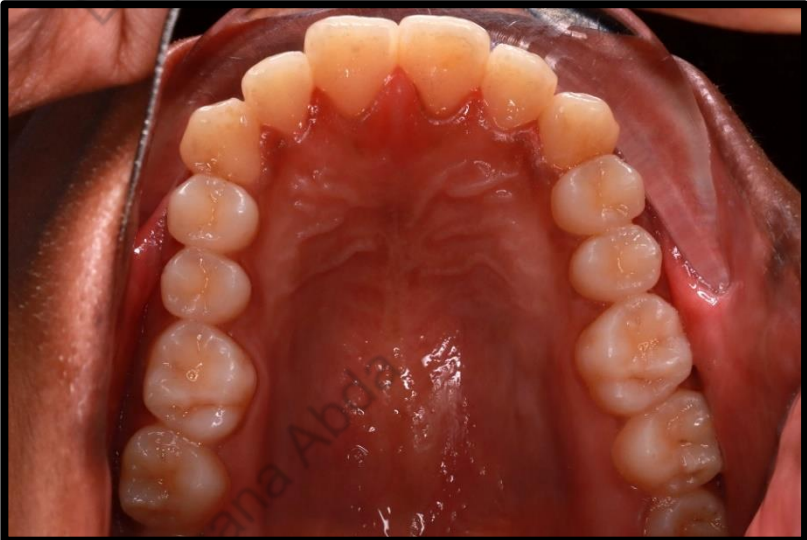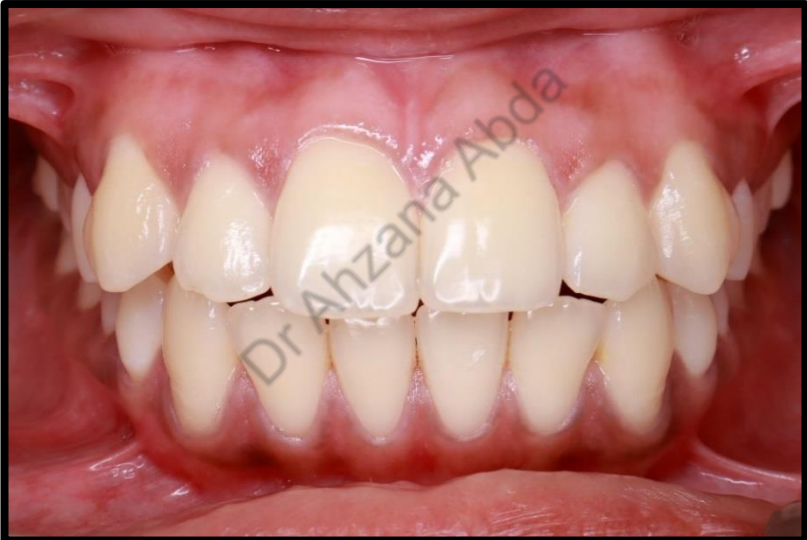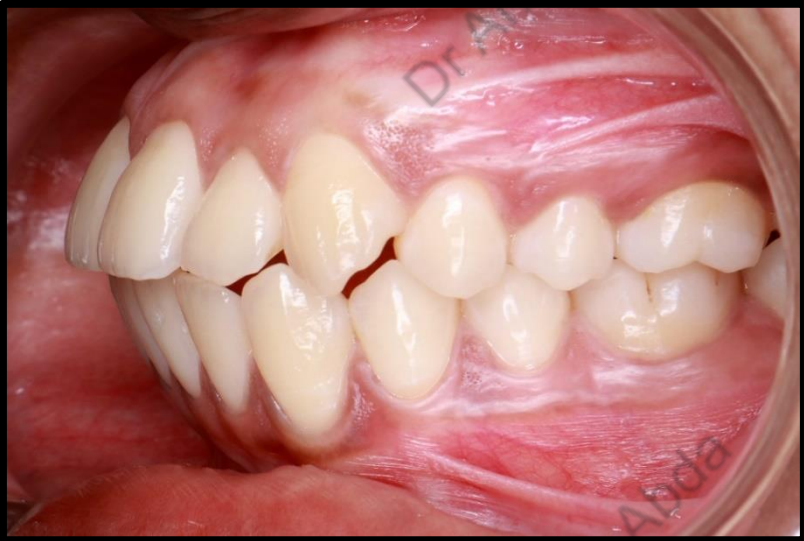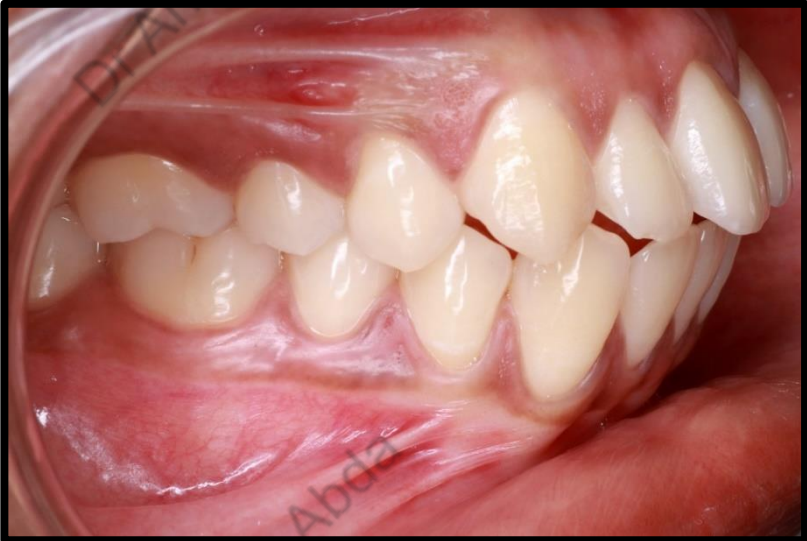# **CASE II**

**SREELAKSHMI 18/F**

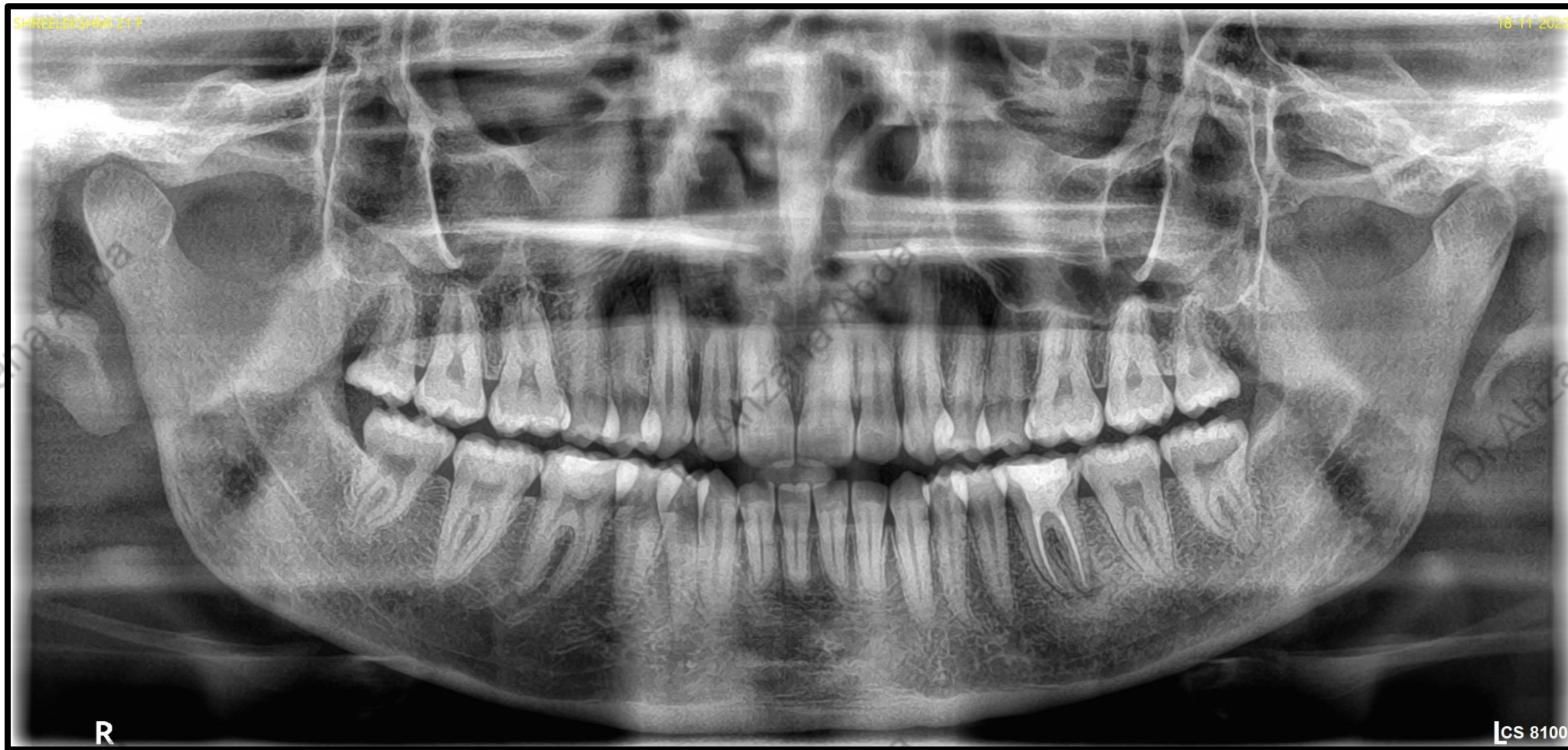
**PRE TREATMENT-EXTRA ORAL**



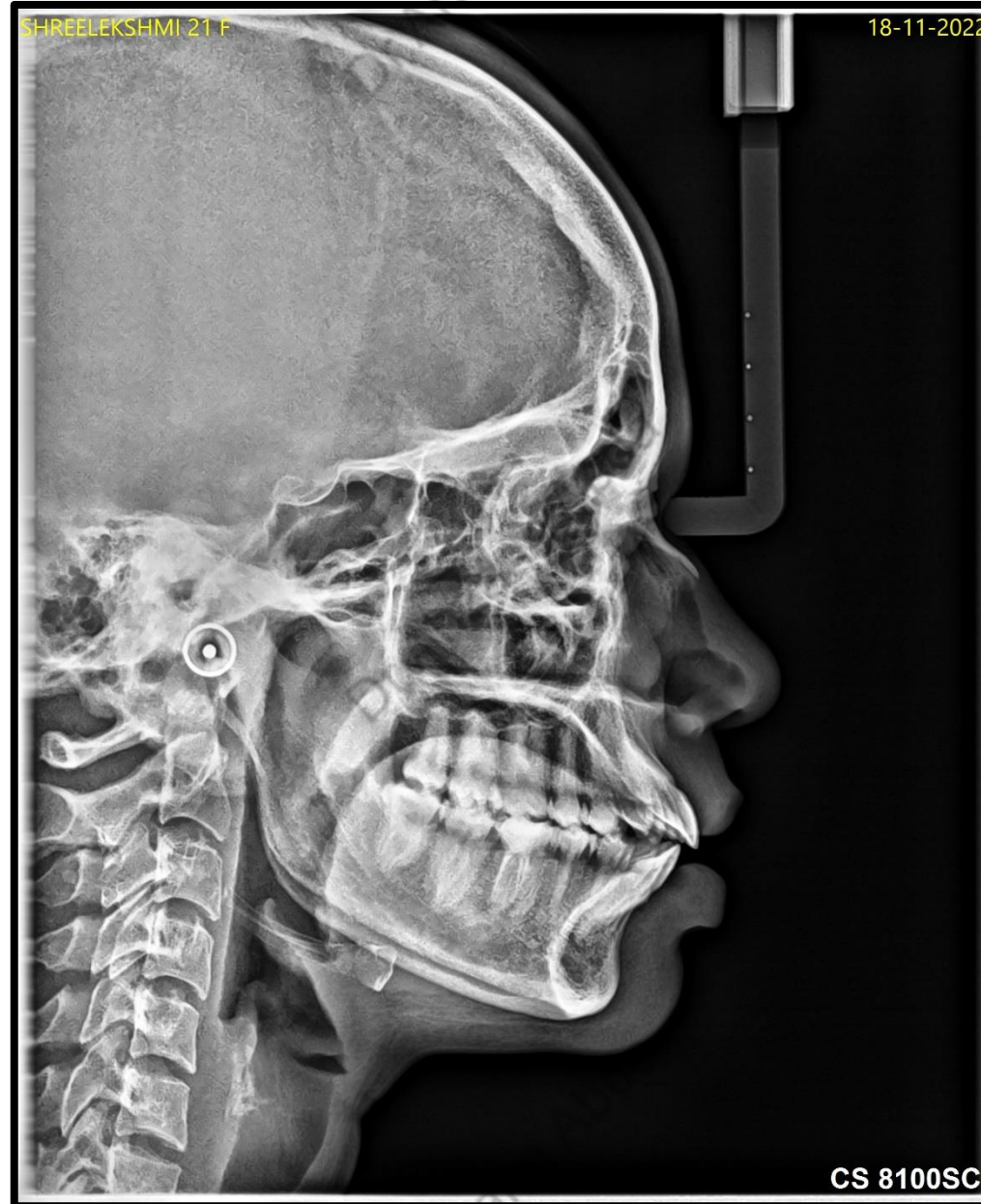**PRE-TREATMENT-INTRA ORAL**



**PRE TREATMENT  
(OPG)**



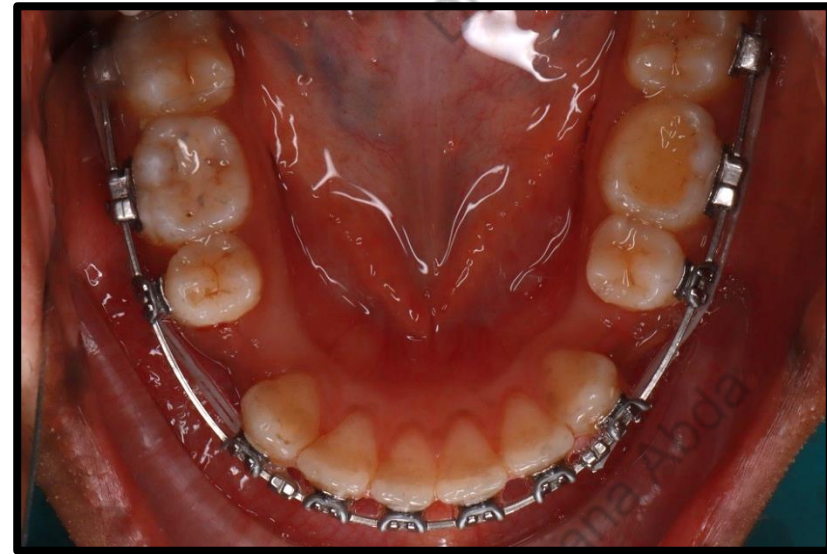
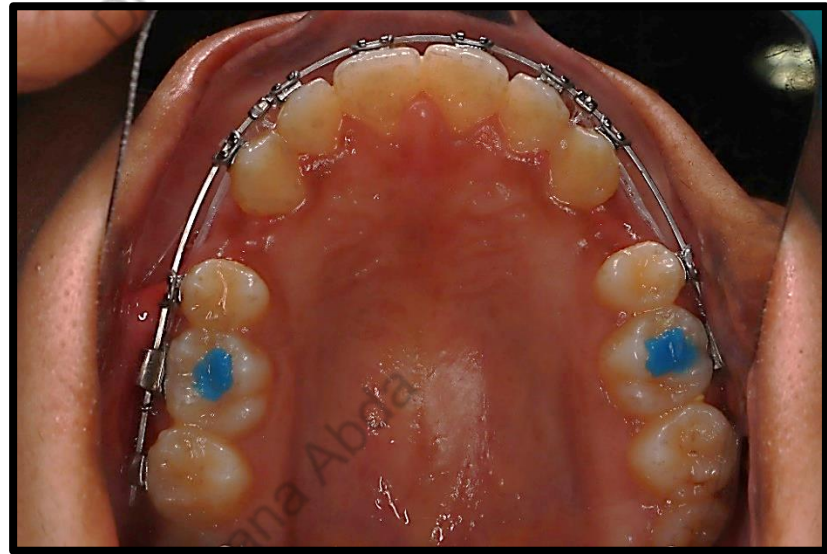
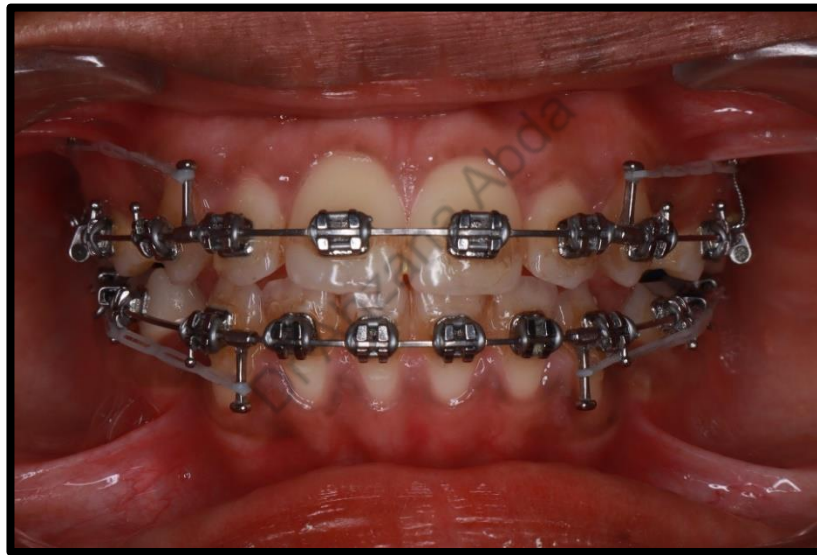
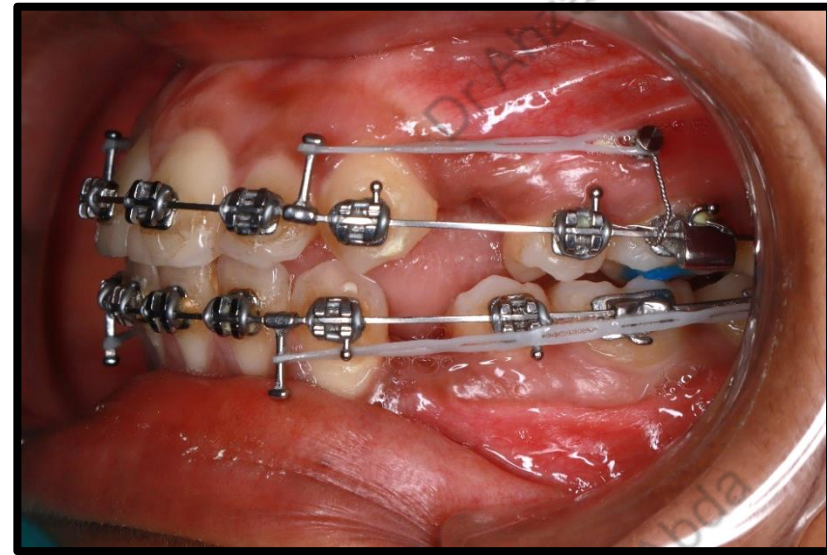
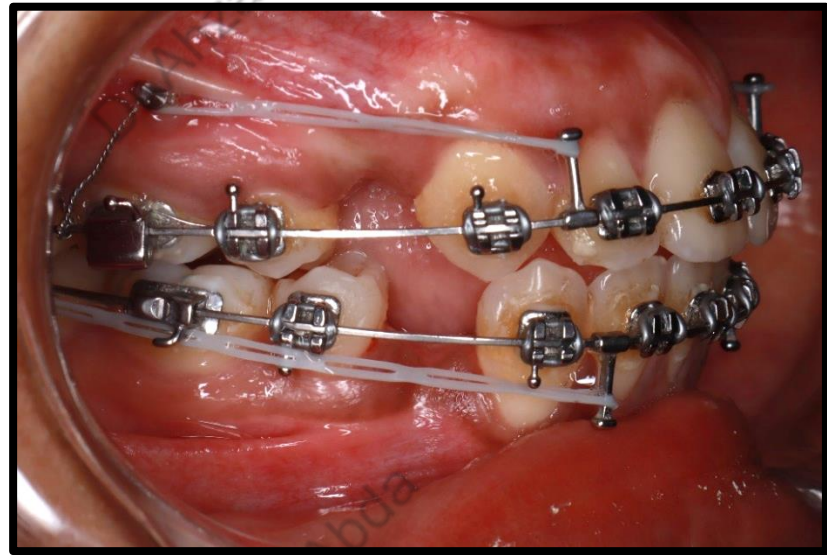
# PRE-TREATMENT (Lateral Cephalogram)



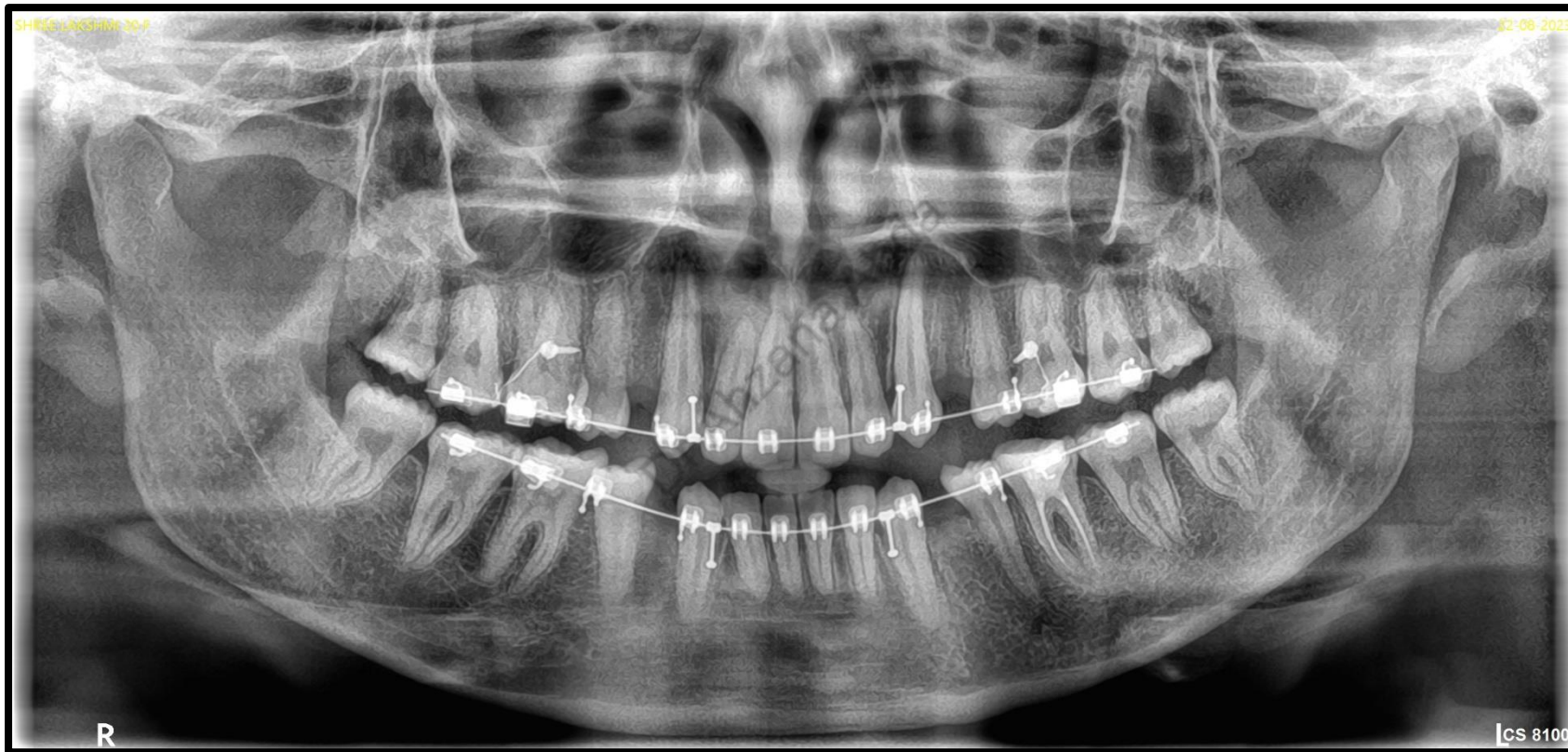
**MID TREATMENT**  
(Extraoral)



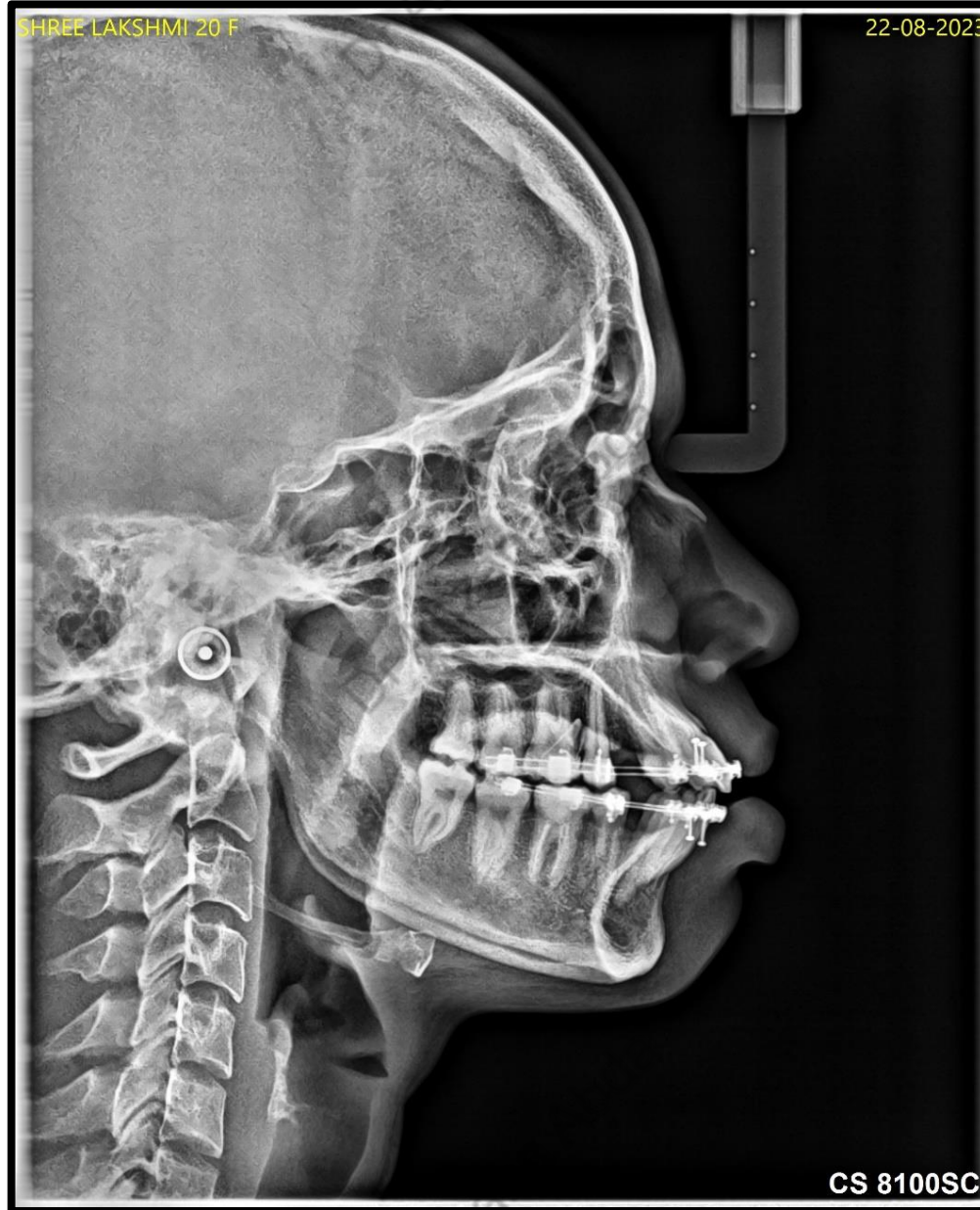**MID TREATMENT**  
(Intraoral)



**MID TREATMENT**  
**(OPG)**



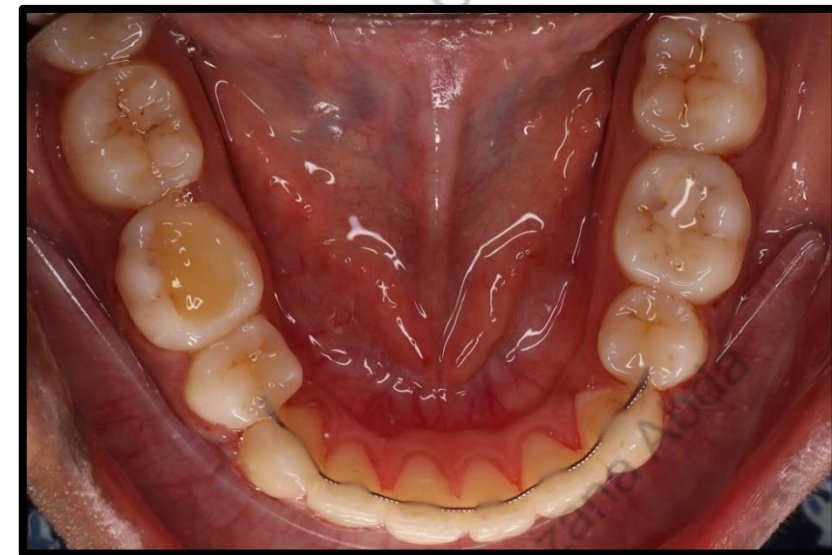
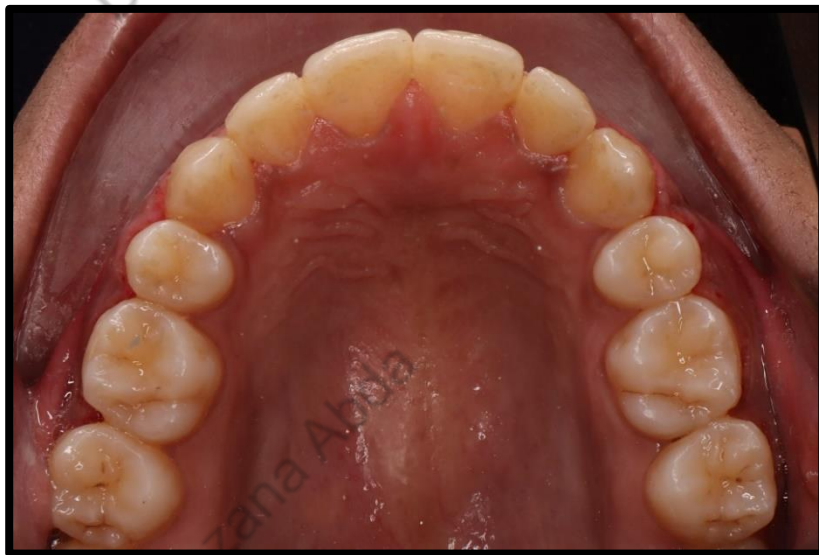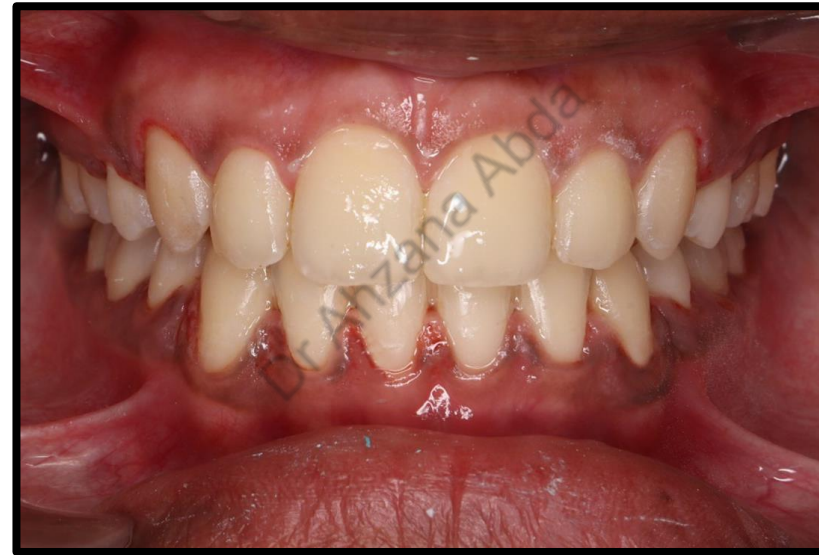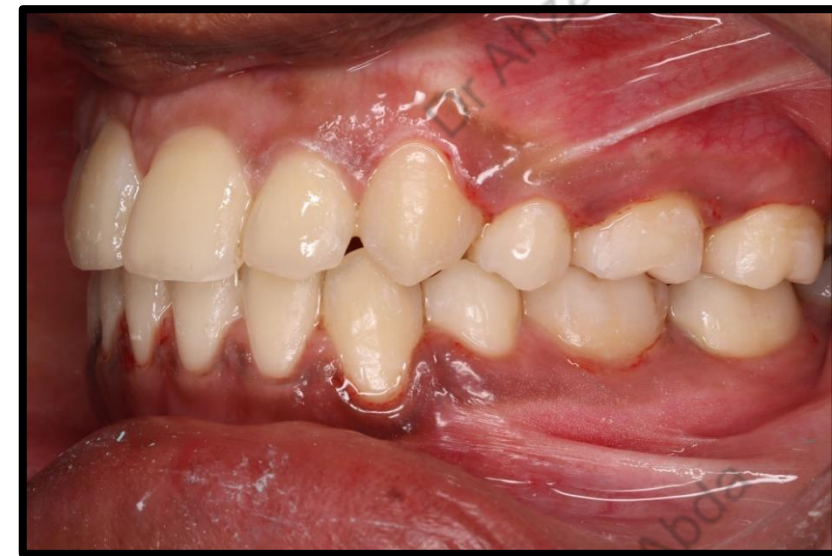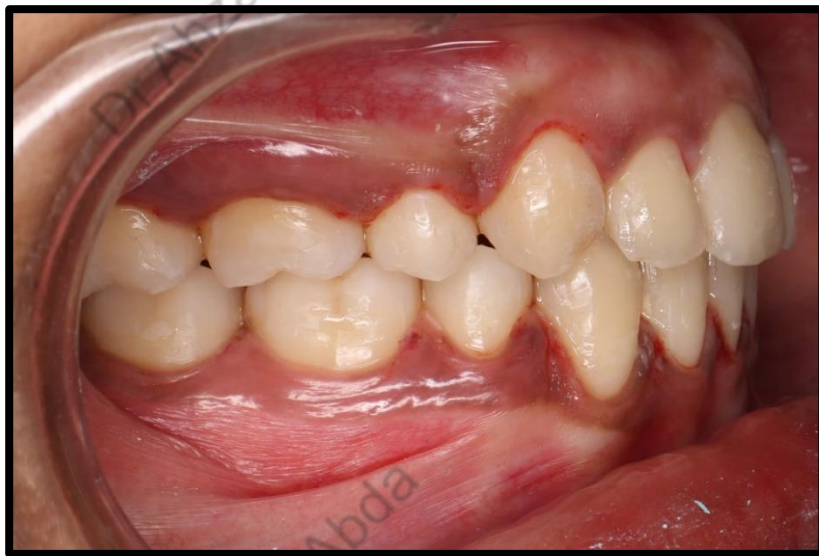# MID TREATMENT (Lateral Cephalogram)



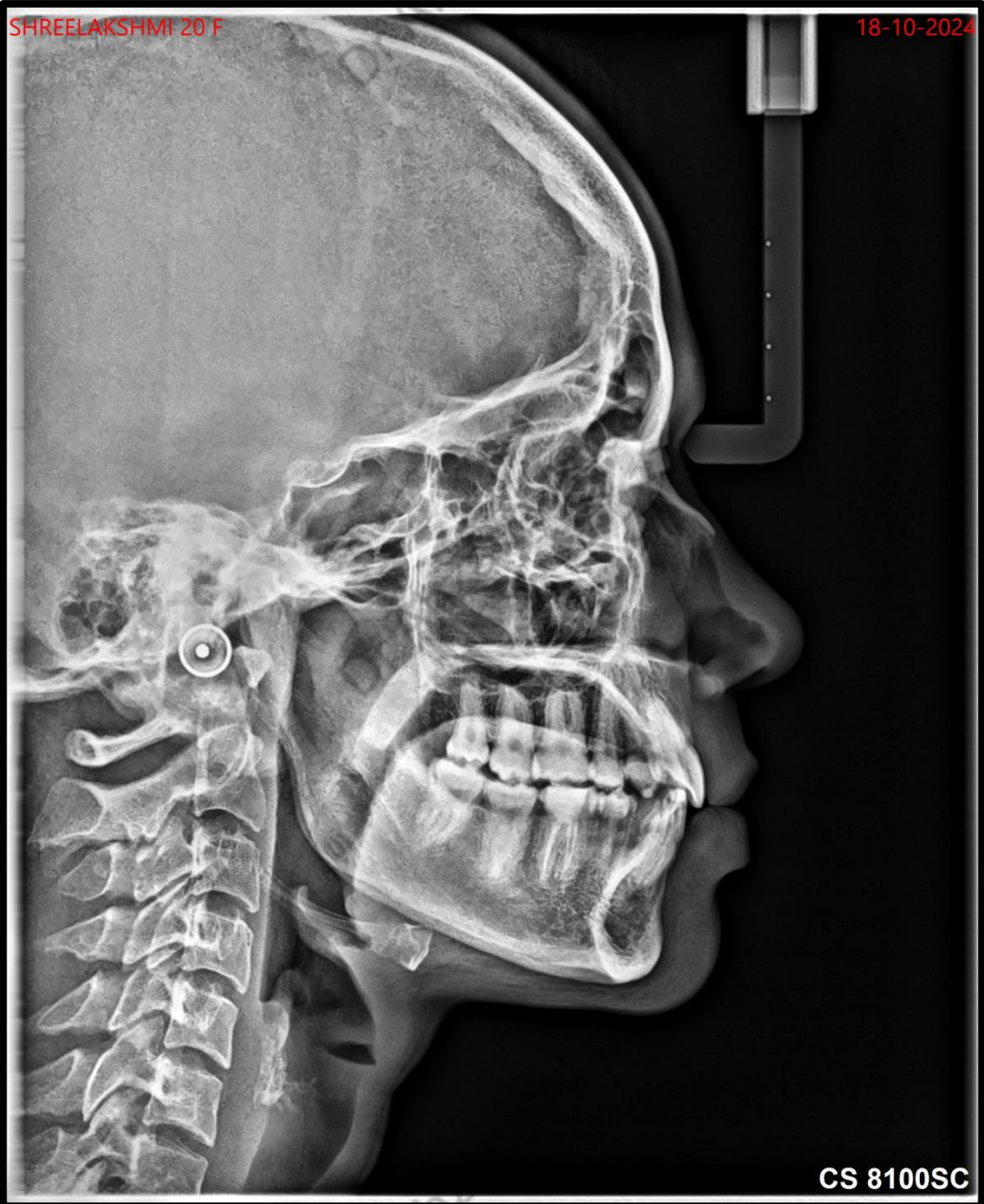**POST EXTRA ORAL**



**POST INTRA ORAL**



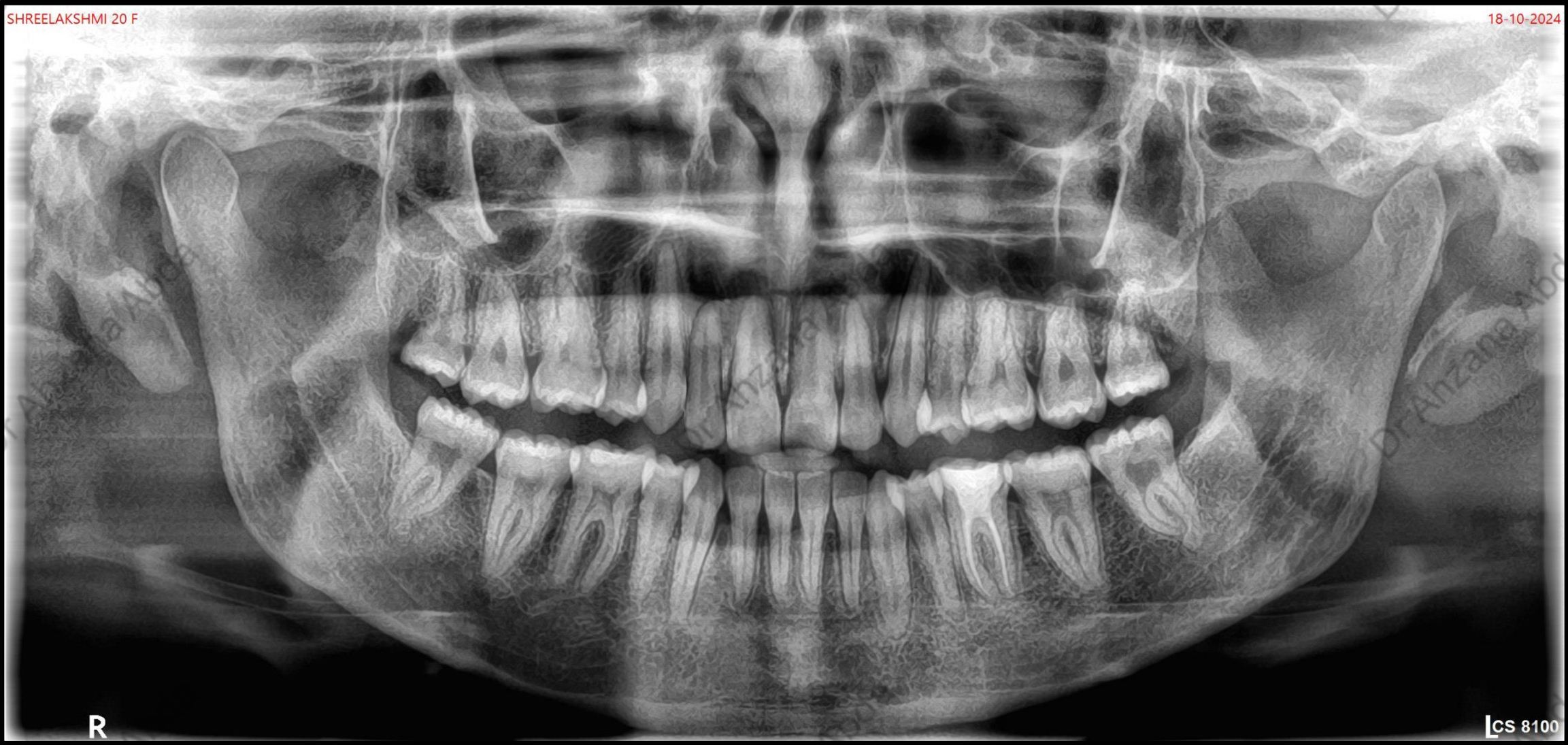# POST-TREATMENT LATERAL CEPHALOGRAM



# POST TREATMENT OPG

SHREELAKSHMI 20 F

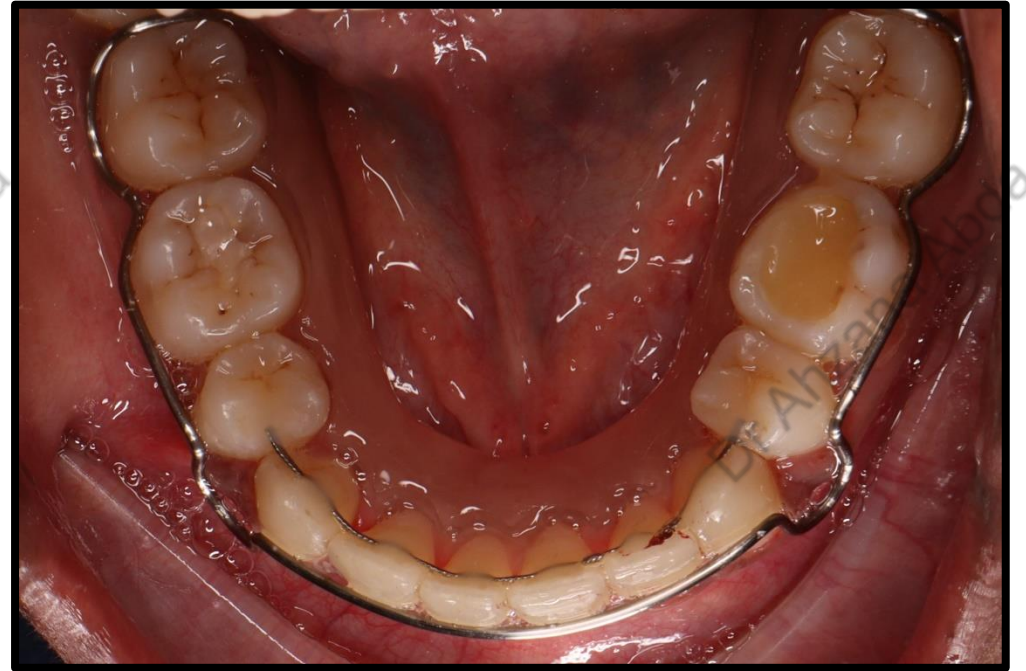
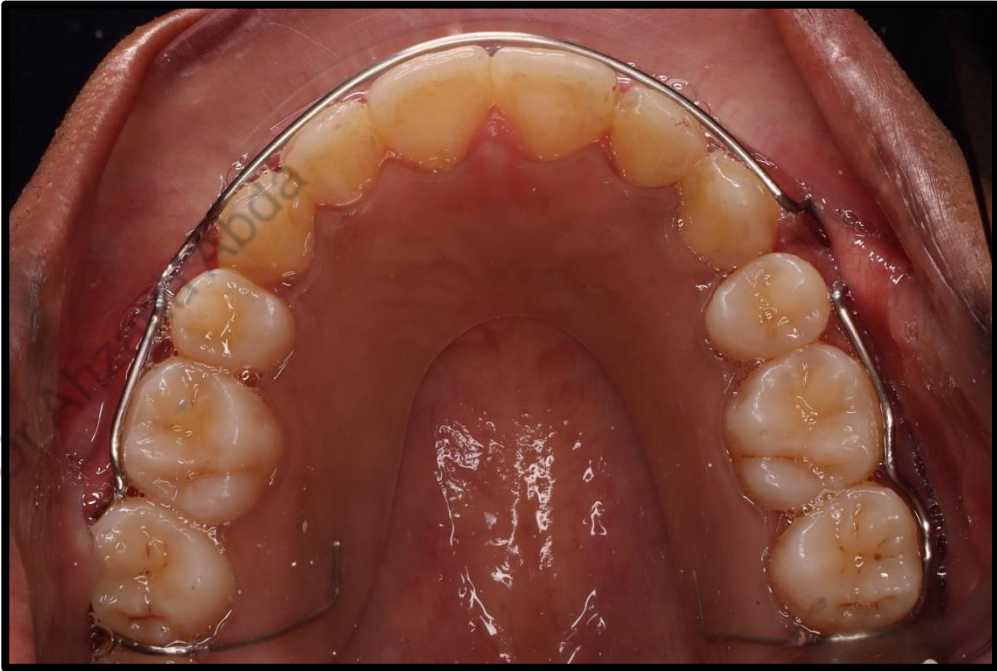
18-10-2024



R

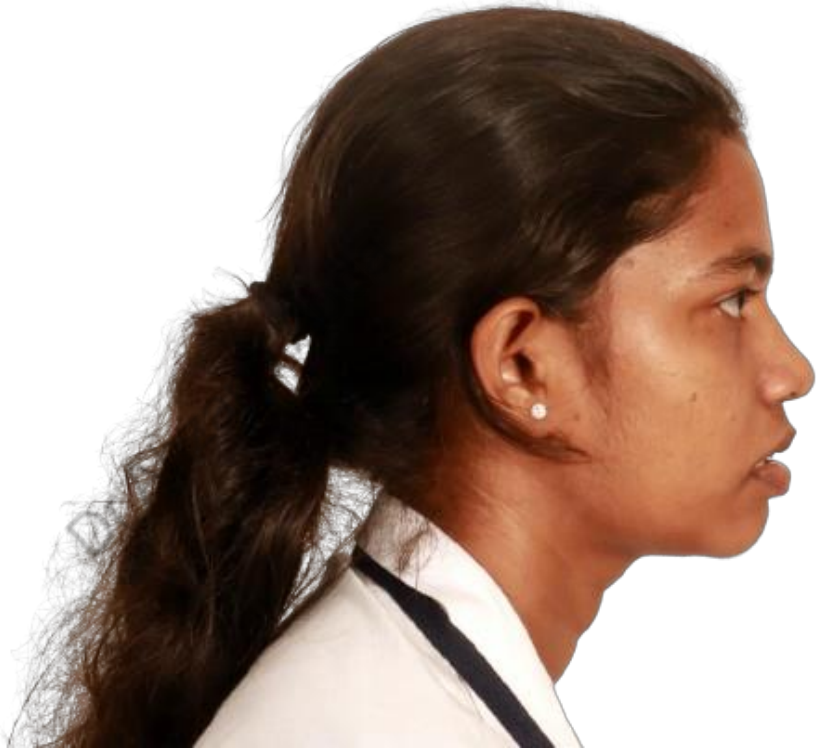CS 8100

# RETAINERS



Dr Ahzana A

**PRE**



Dr Ahzana A

**MID**



Dr Ahzana A

**POST**

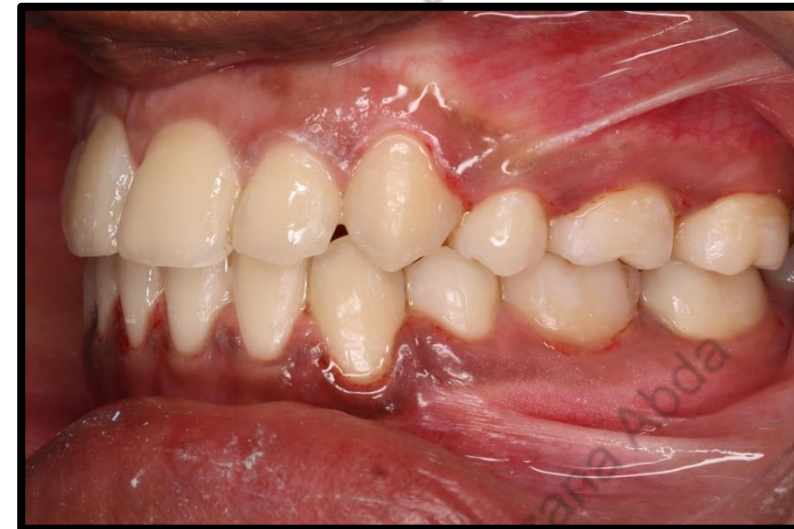
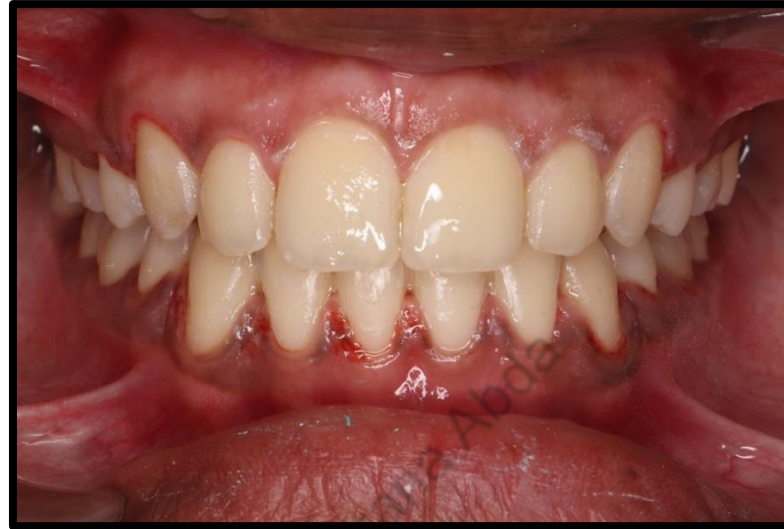
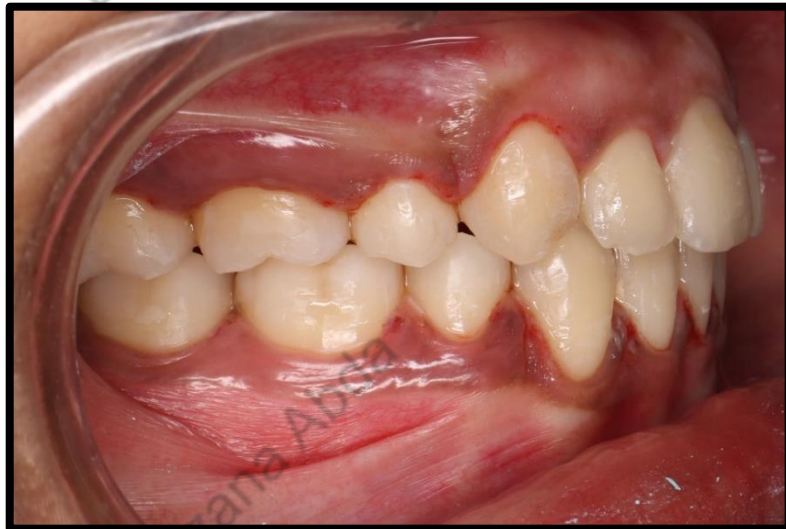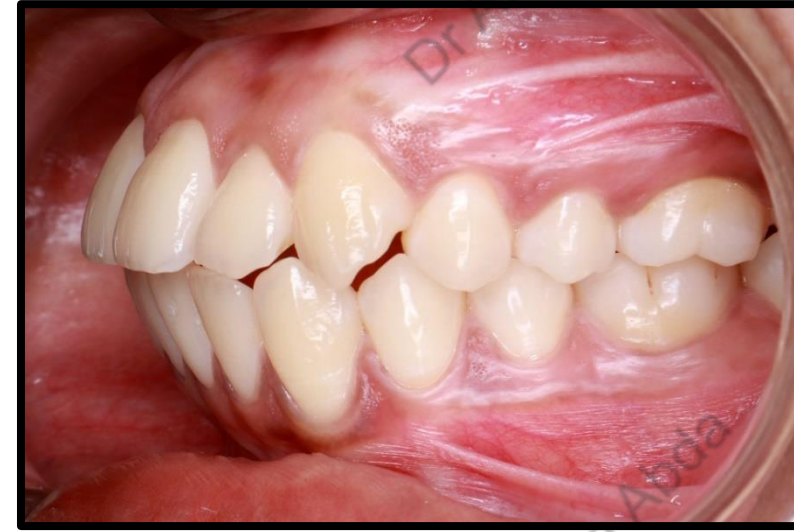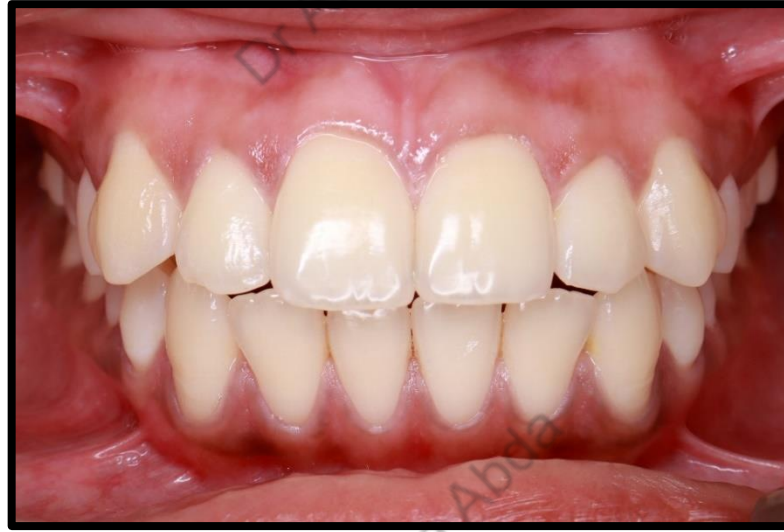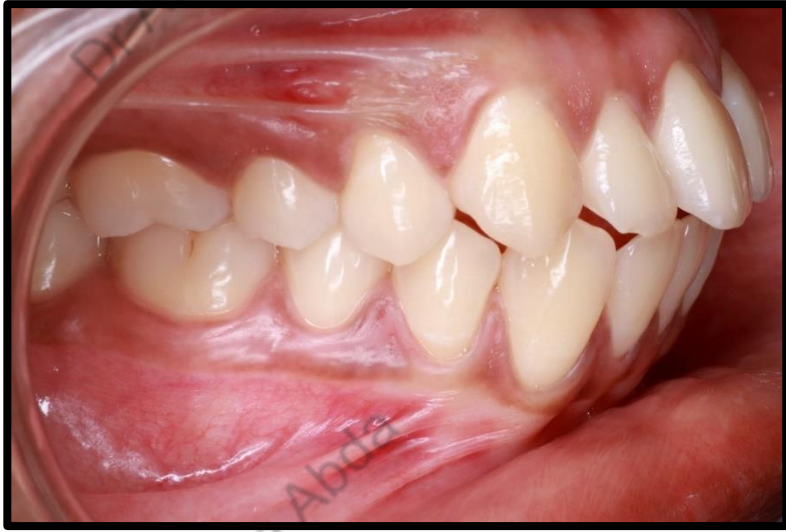Dr Ahzana Abda

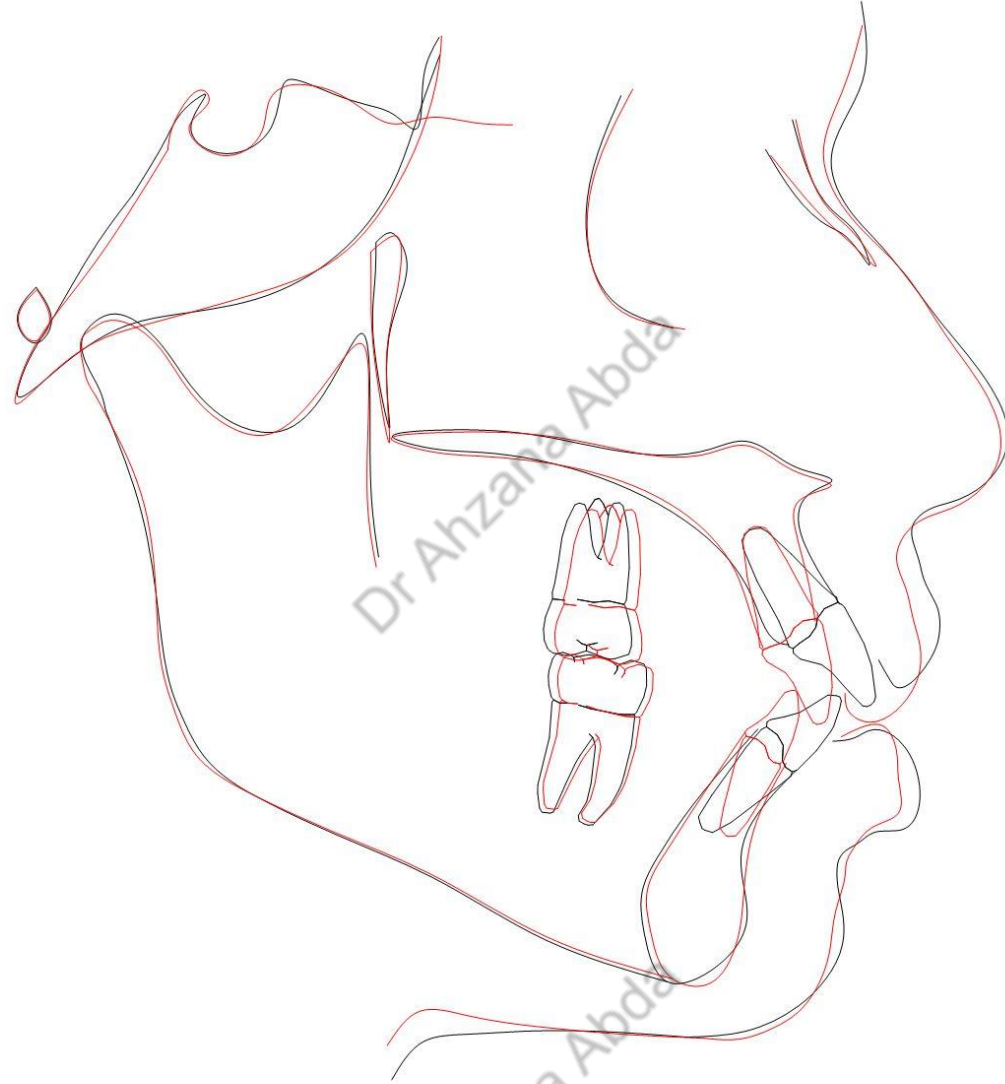
Dr Ahzana Abda

Dr Ahzana Abda

# PRE – POST INTRAORAL COMPARISON



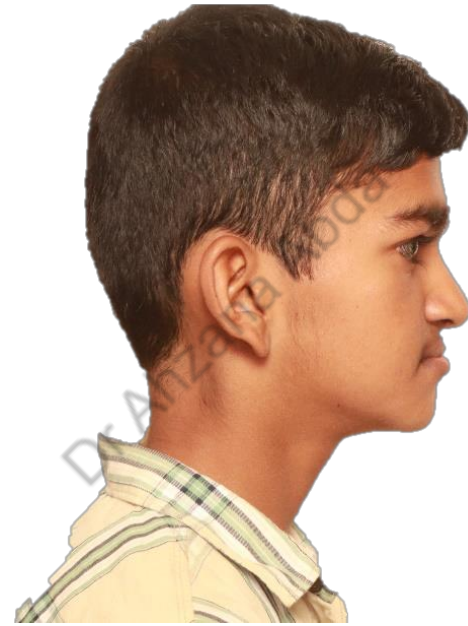# SUPERIMPOSITION



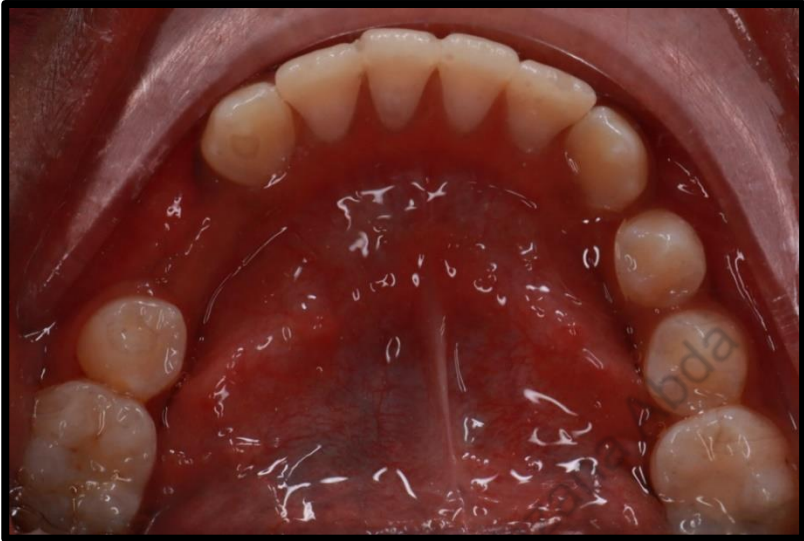
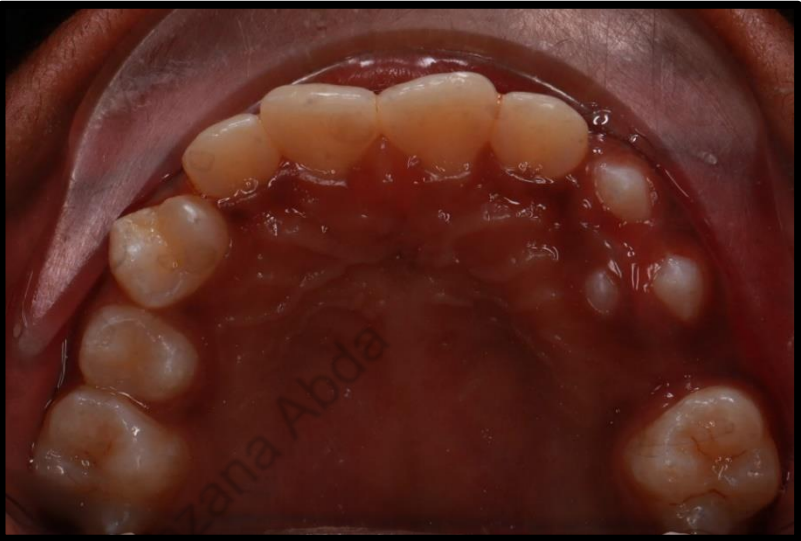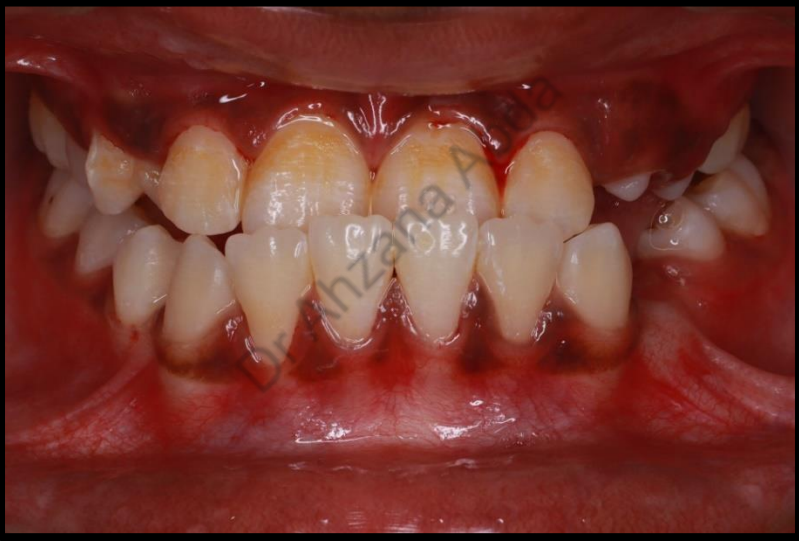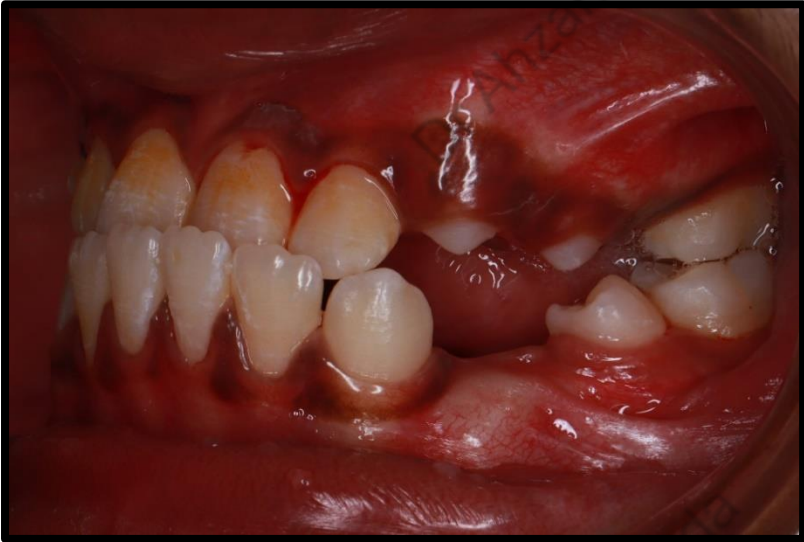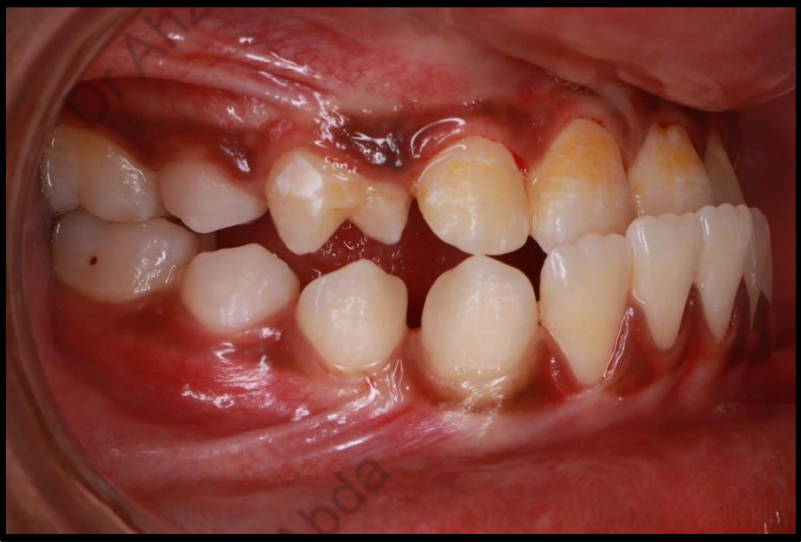# CASE III

**Rimshad 12/M**

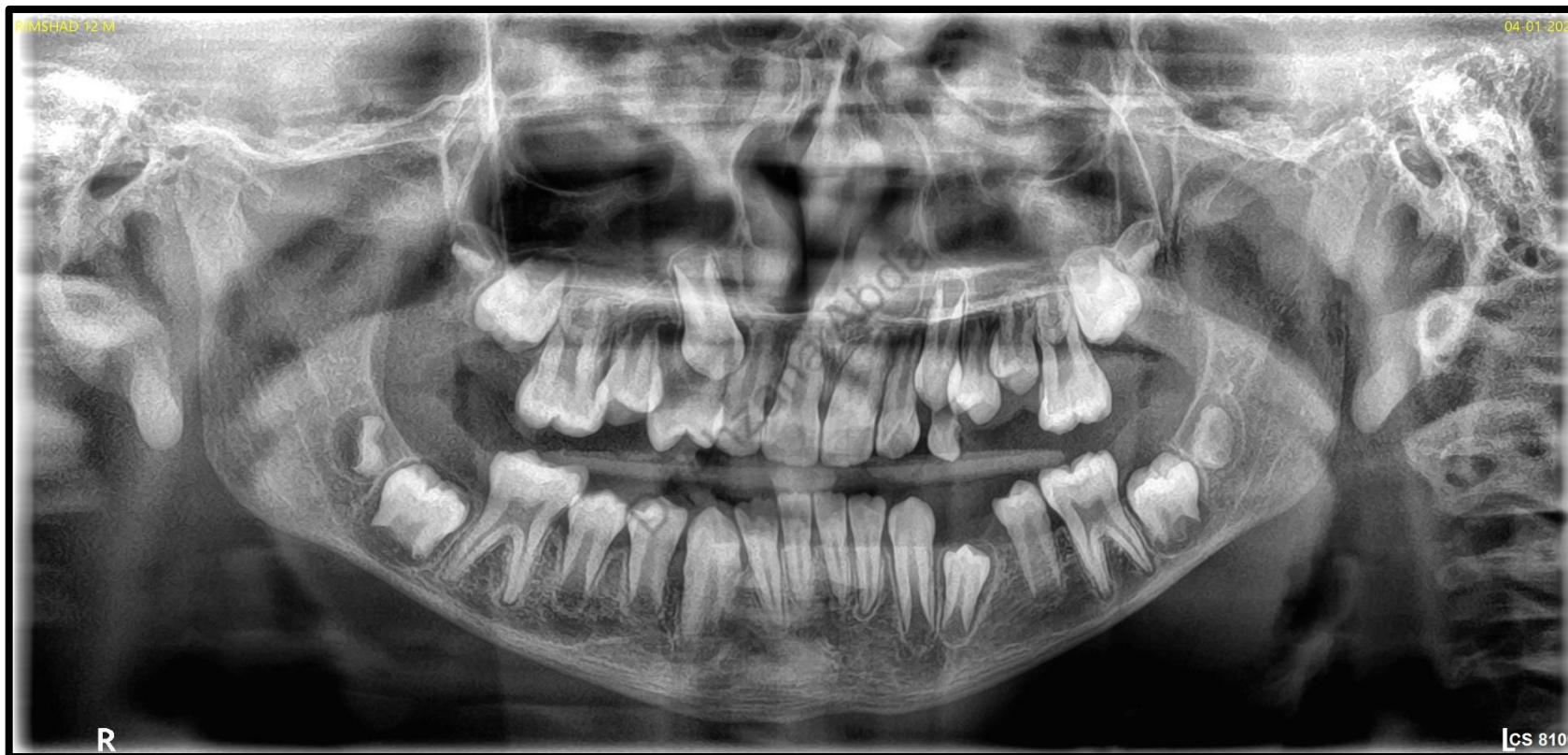
# PRE TREATMENT EXTRAORAL



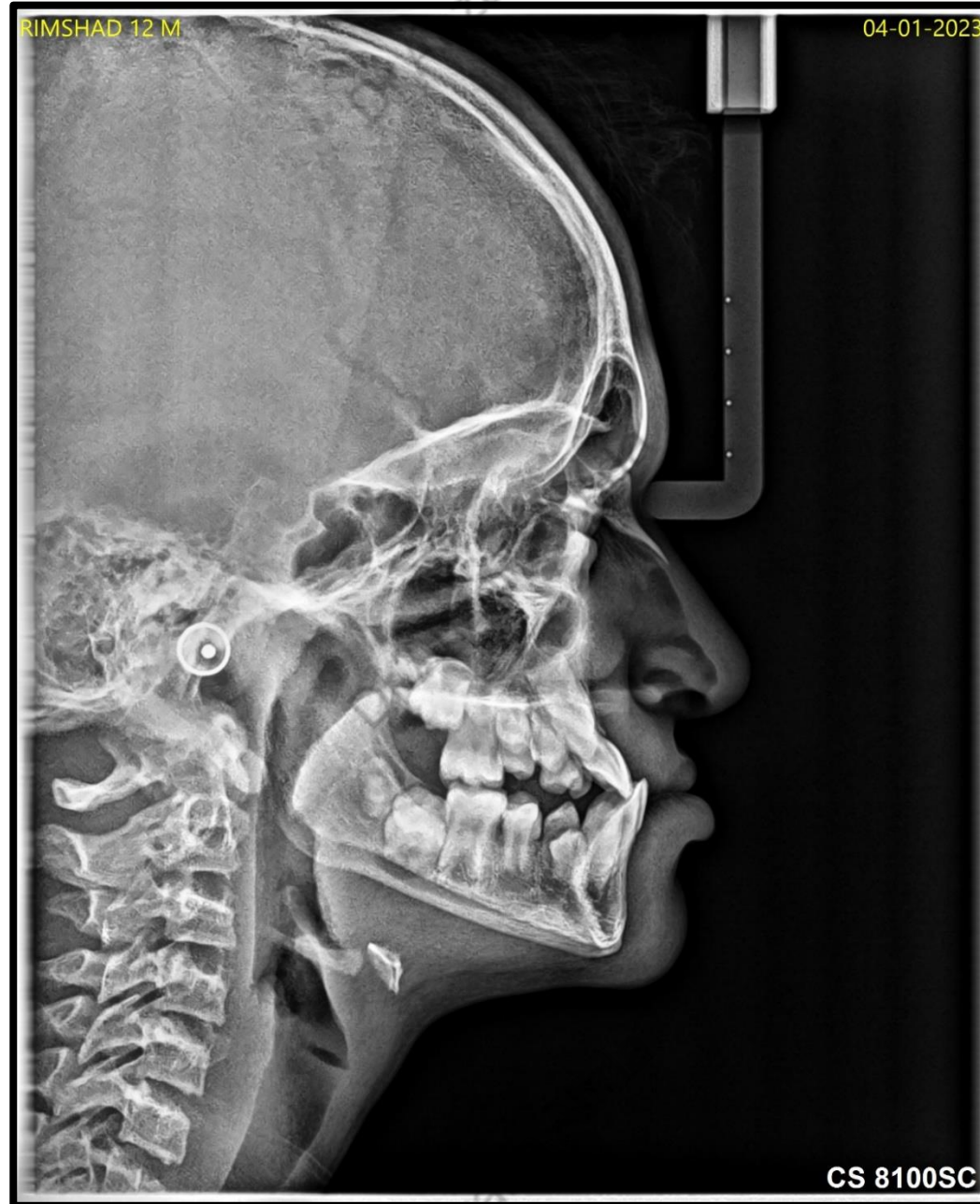**PRE TREATMENT INTRAORAL**



# PRE TREATMENT OPG

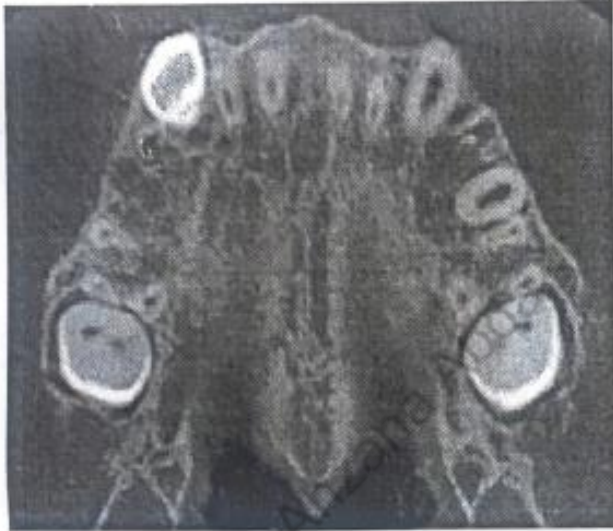


# PRE TREATMENT LATERAL CEPHALOGRAM

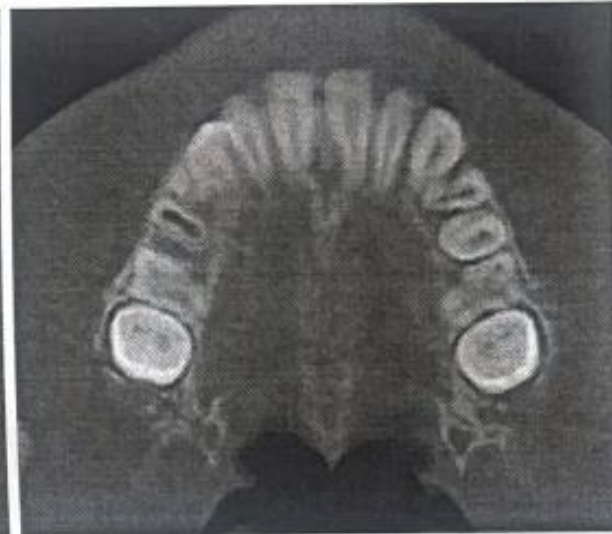


## MID – PALATINE SUTURE

Stage D (*Angelieri et al*) - The fusion of the midpalatal suture has occurred in the palatine bone, with maturation progressing from posterior to anterior. In the palatine bone, the midpalatal suture cannot



*Axial view slice thickness 0.06mm*



*Axial view slice thickness 5mm*

be visualized at this stage, and the parasutural bone density is increased (high-density bone) compared with the density of the maxillary parasutural bone. In the maxillary portion of the suture, fusion has not yet occurred, and the suture still can be seen as 2 high-density lines separated by small low-density spaces

## **DIAGNOSIS**

- Class III Skeletal Pattern
- Angle's Class I Malocclusion with anterior crossbite
- Average to Horizontal Growth Pattern

## **TREATMENT PLAN**

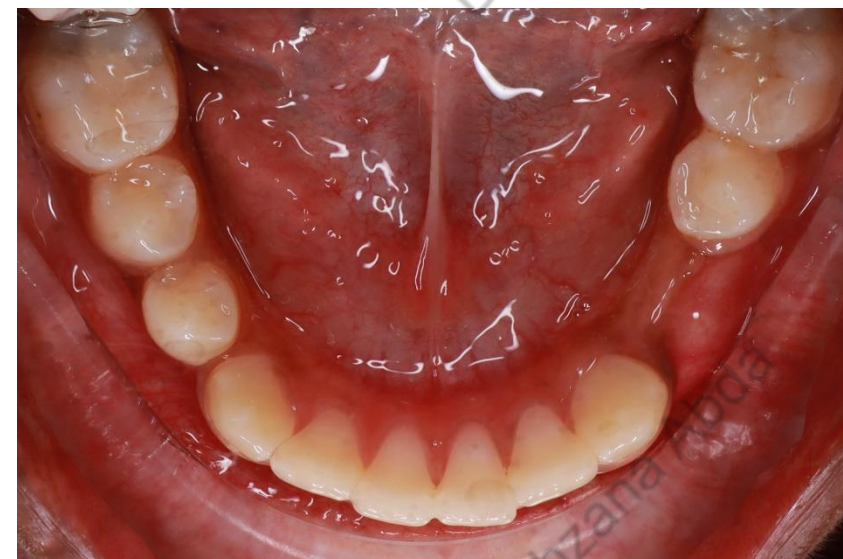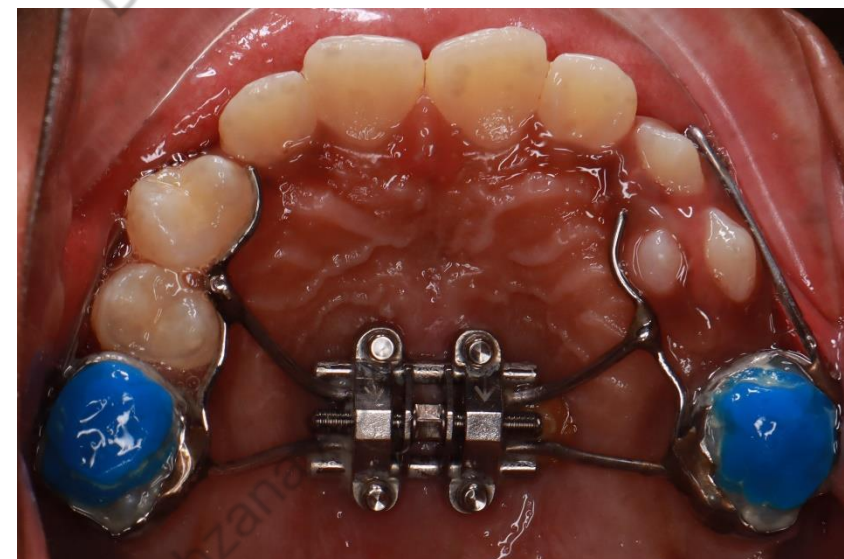
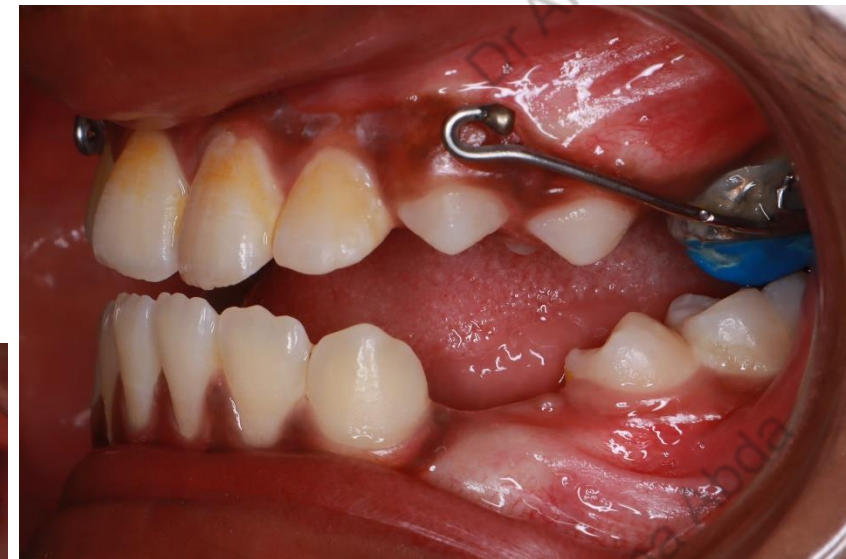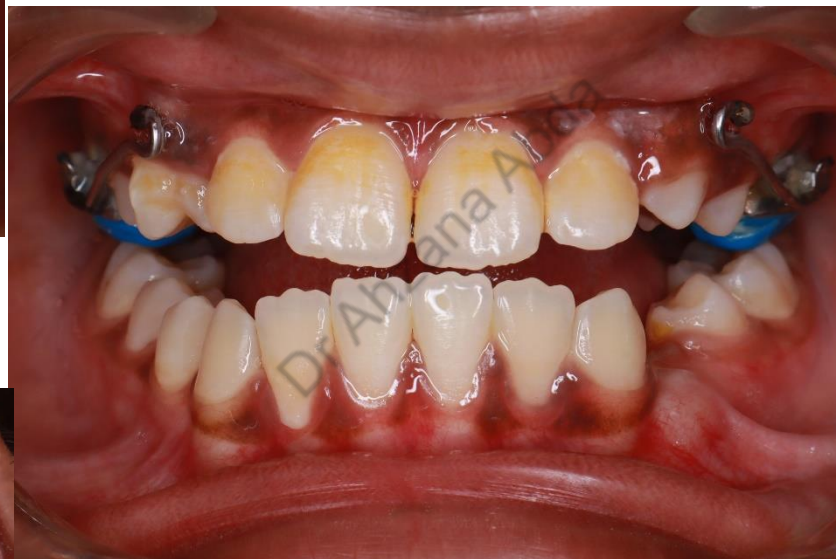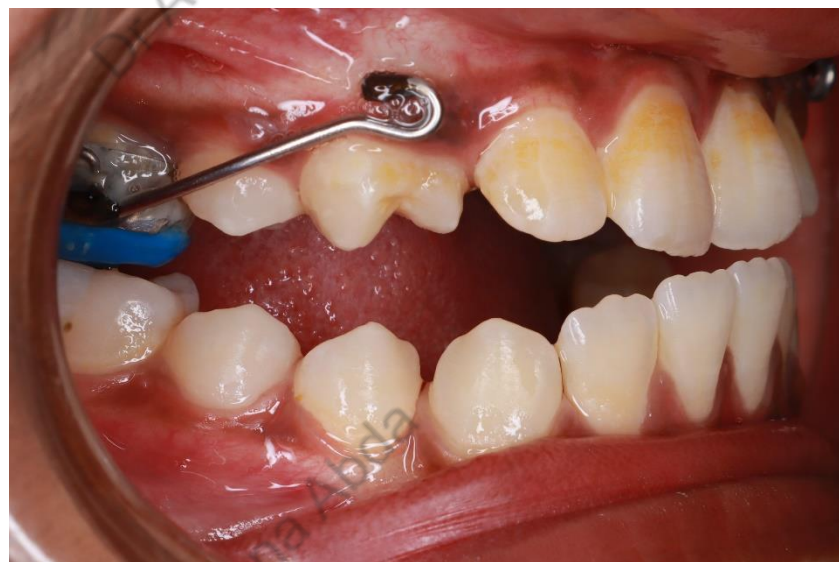- **PHASE I THERAPY**

Facemask with MSE

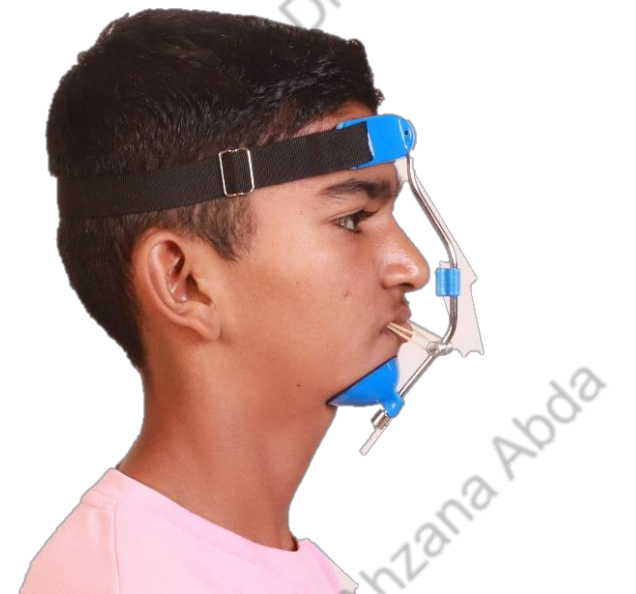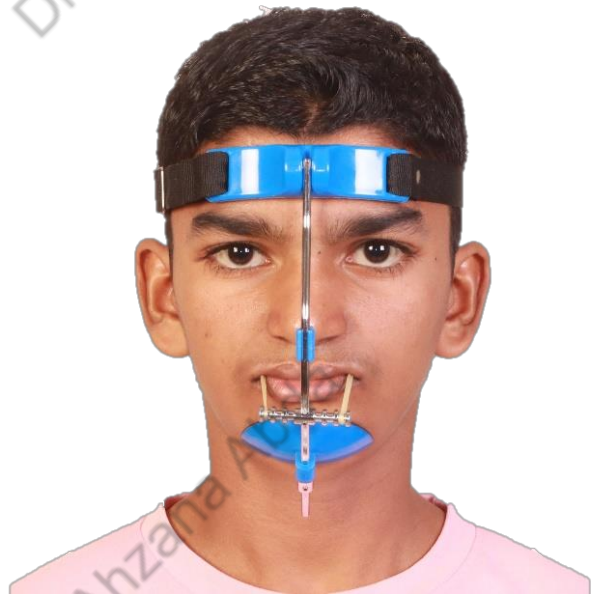
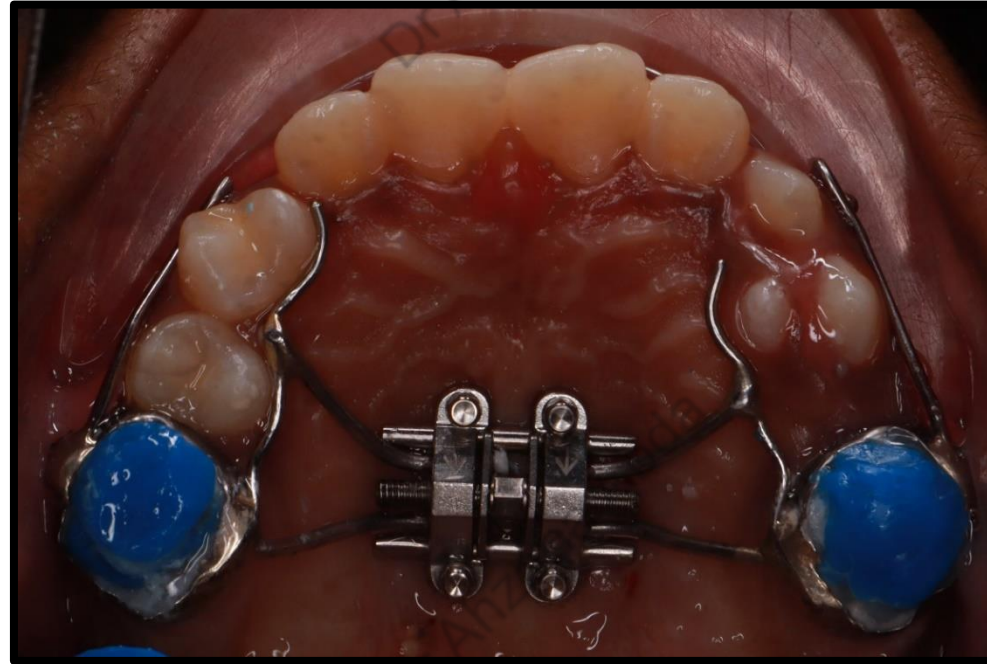
- **PHASE II THERAPY**

Fixed mechanotherapy

**MSE**



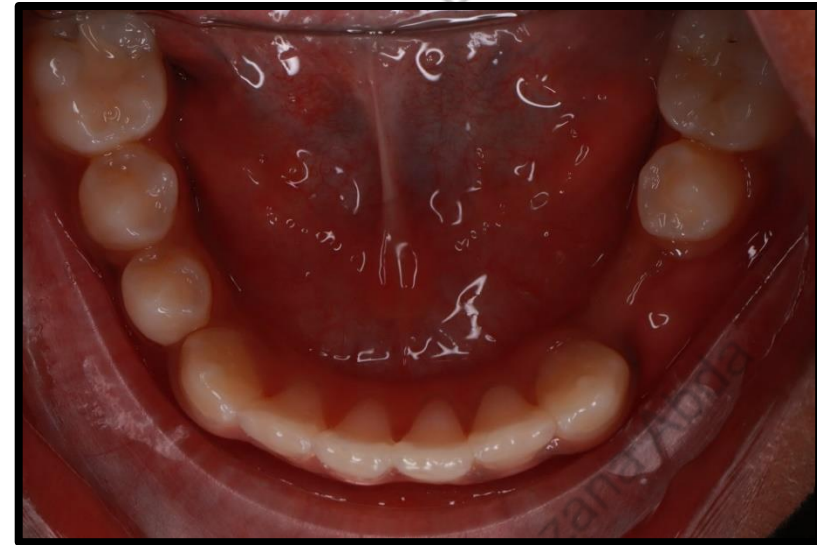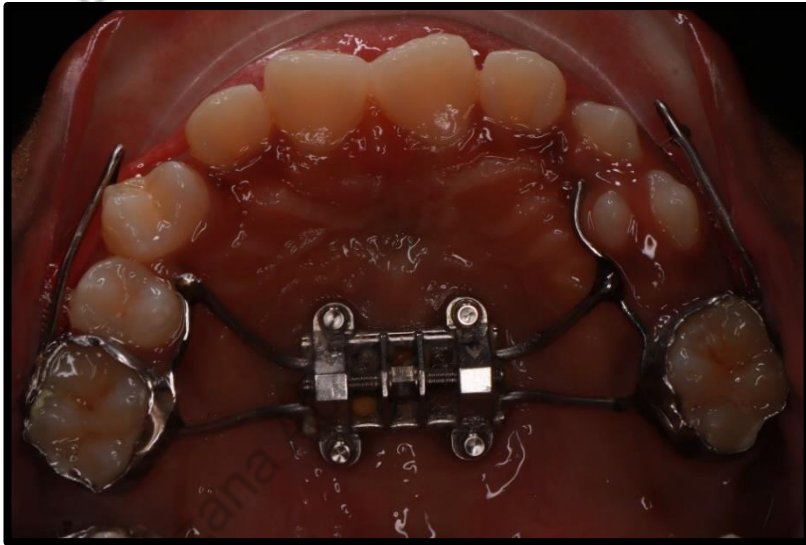
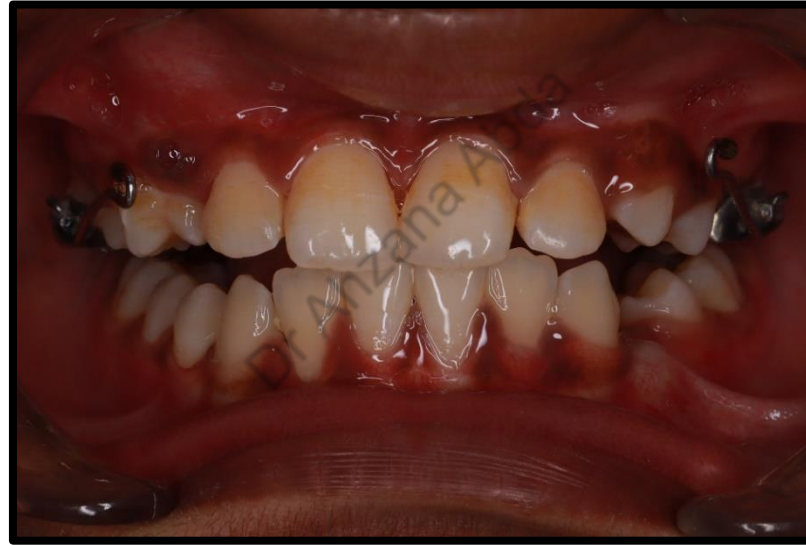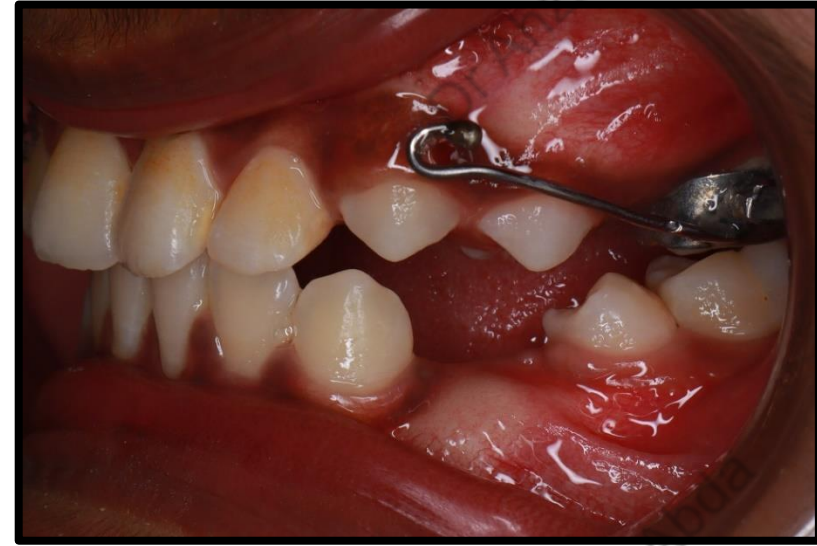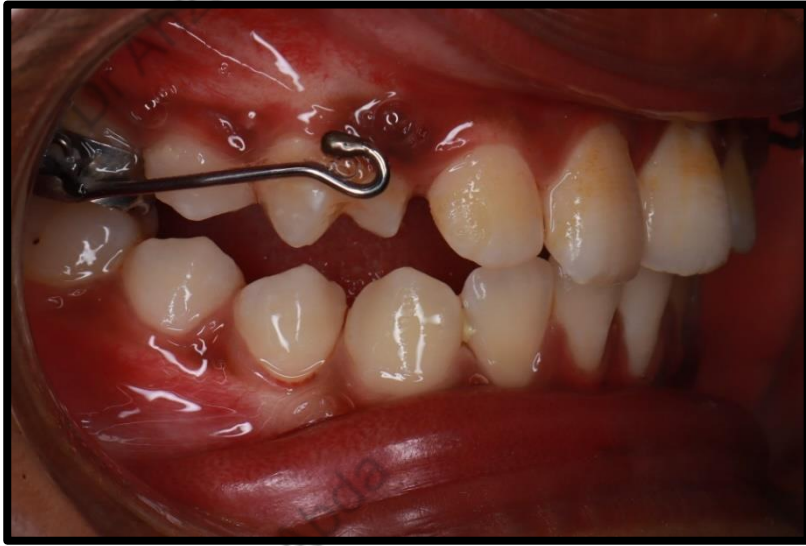
# MSE WITH FACEMASK



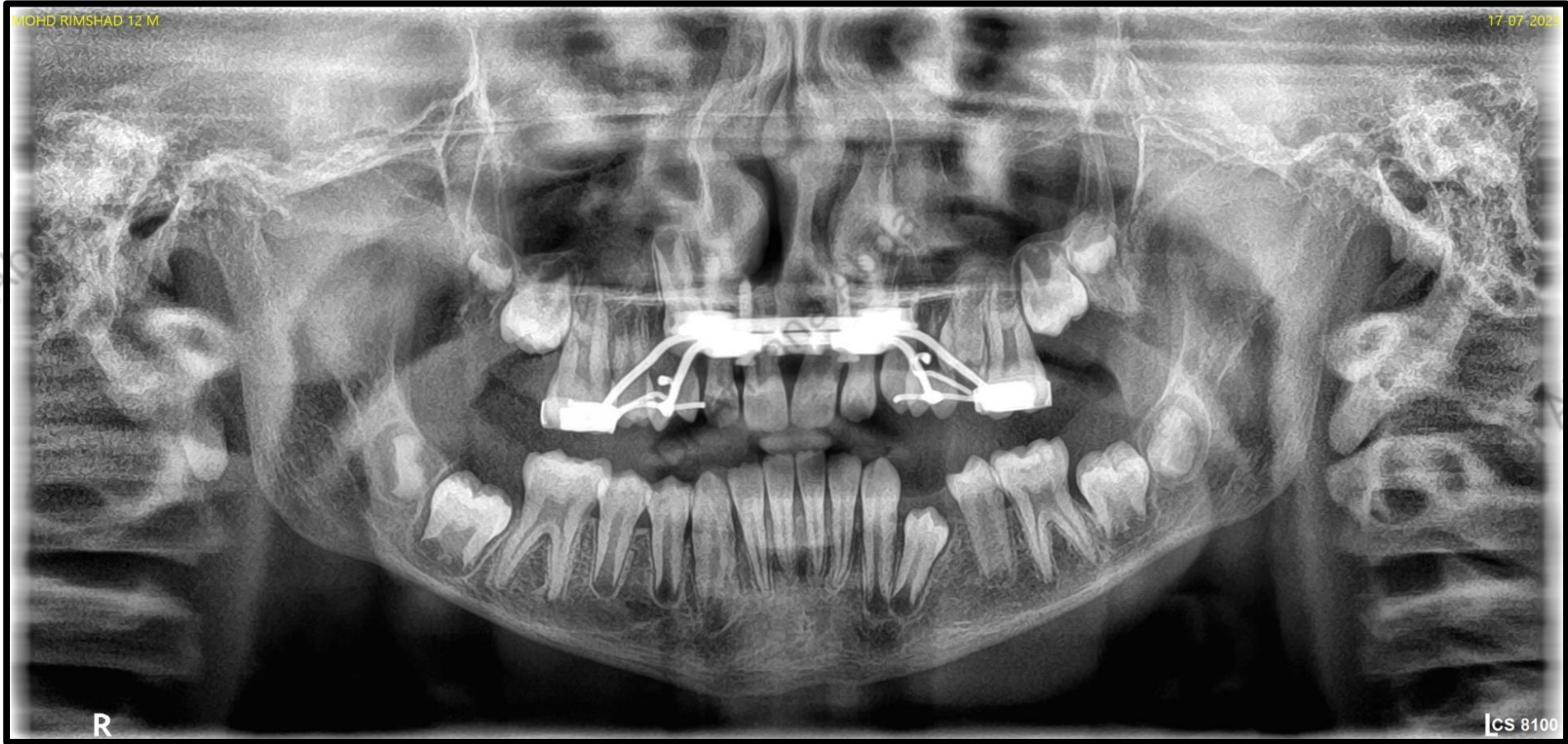
**END OF PHASE I  
EXTRA ORAL**



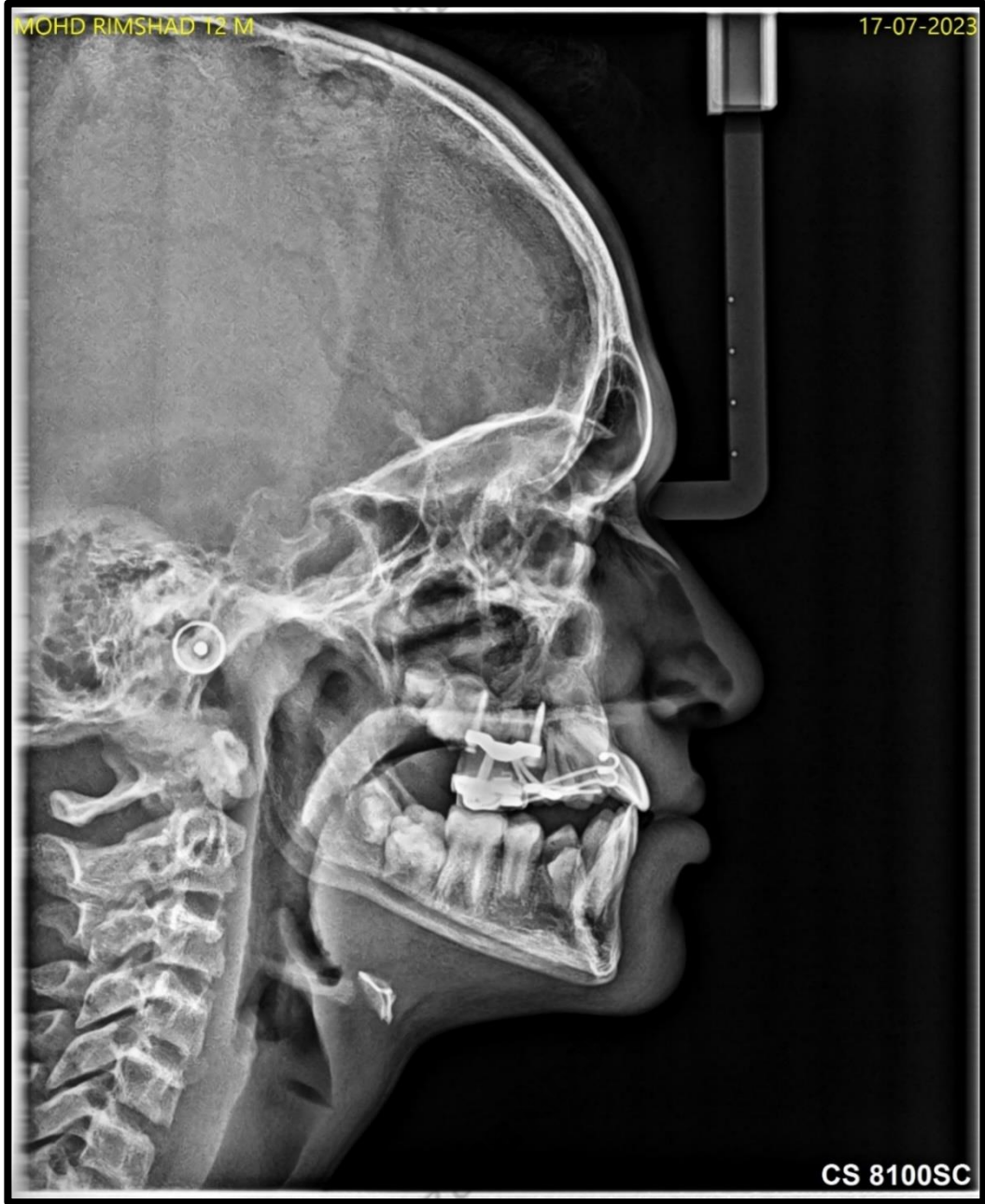**END OF PHASE I  
INTRA ORAL**



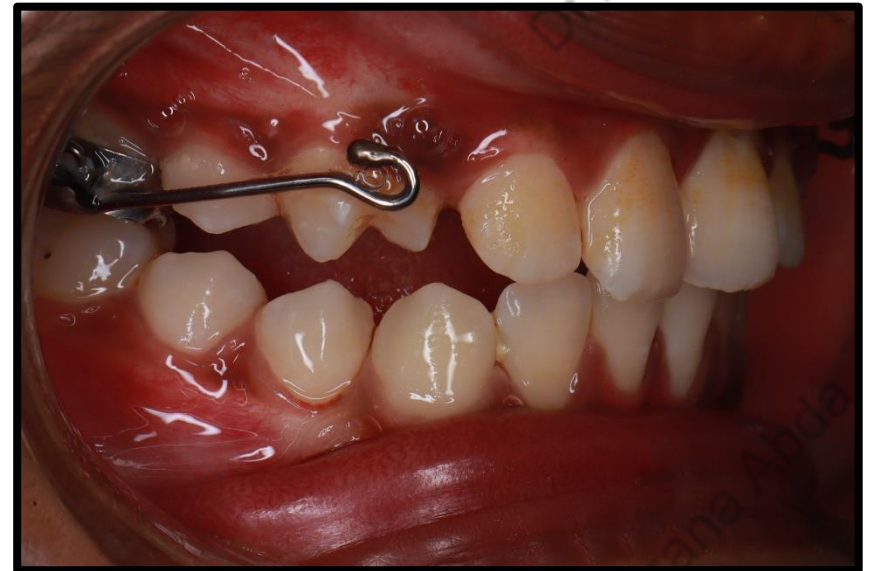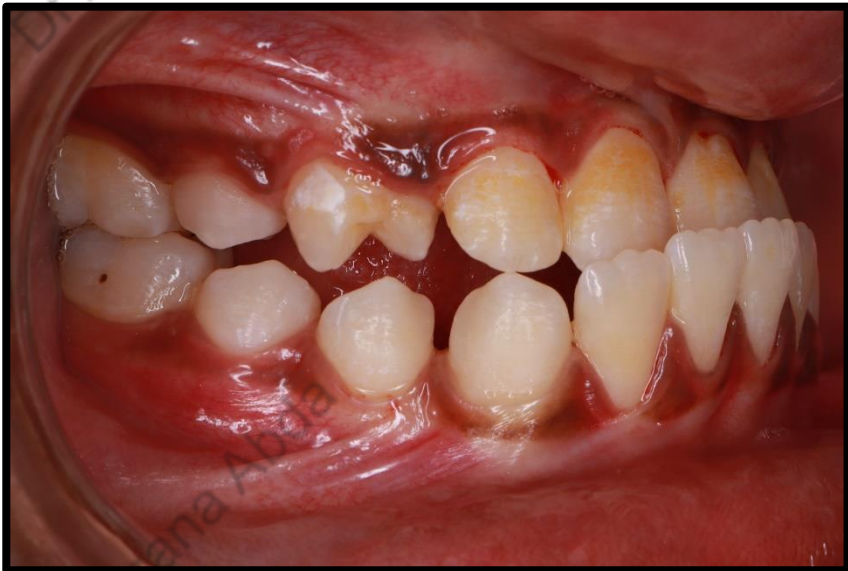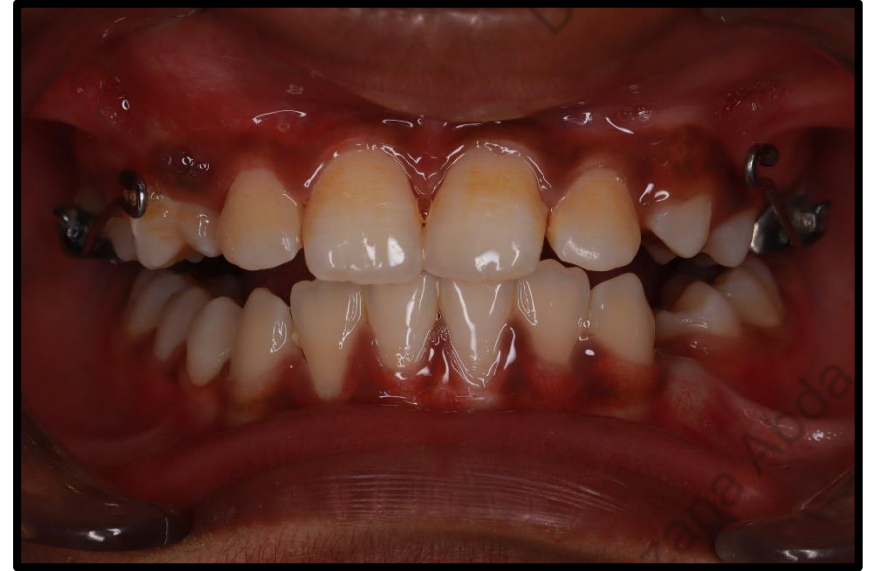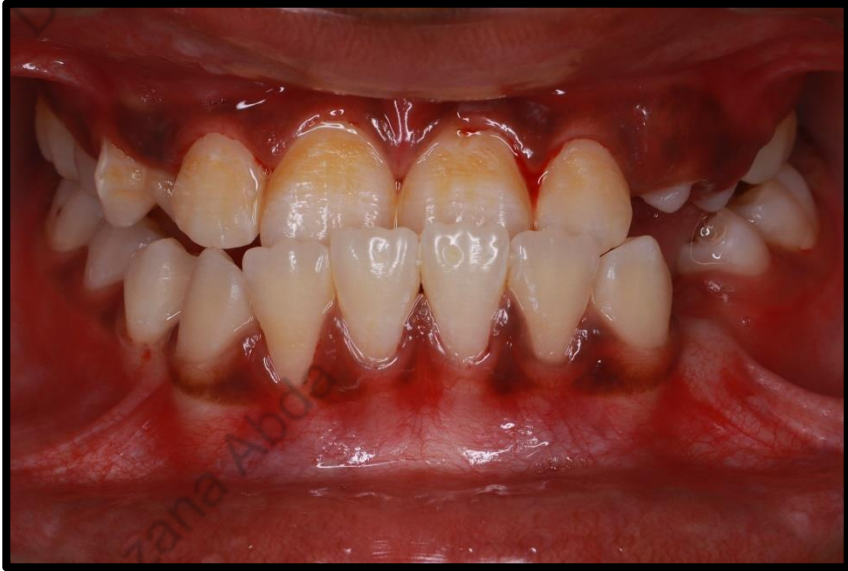**END OF PHASE I  
OPG**



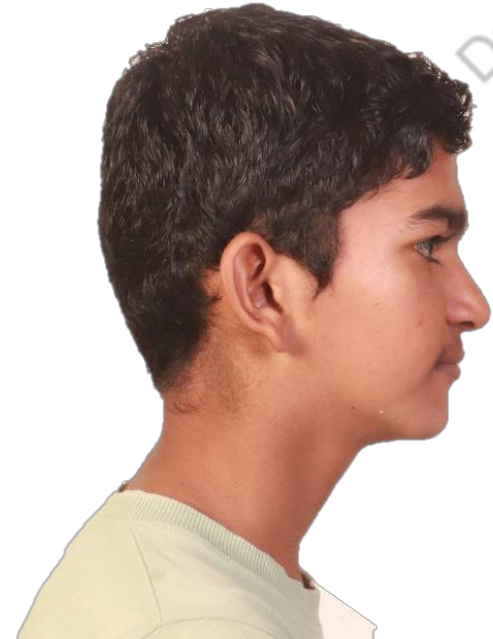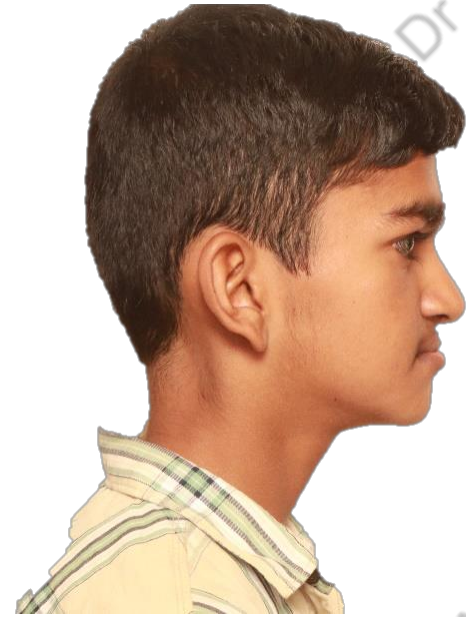# END OF PHASE I - LATERAL CEPHALOGRAM

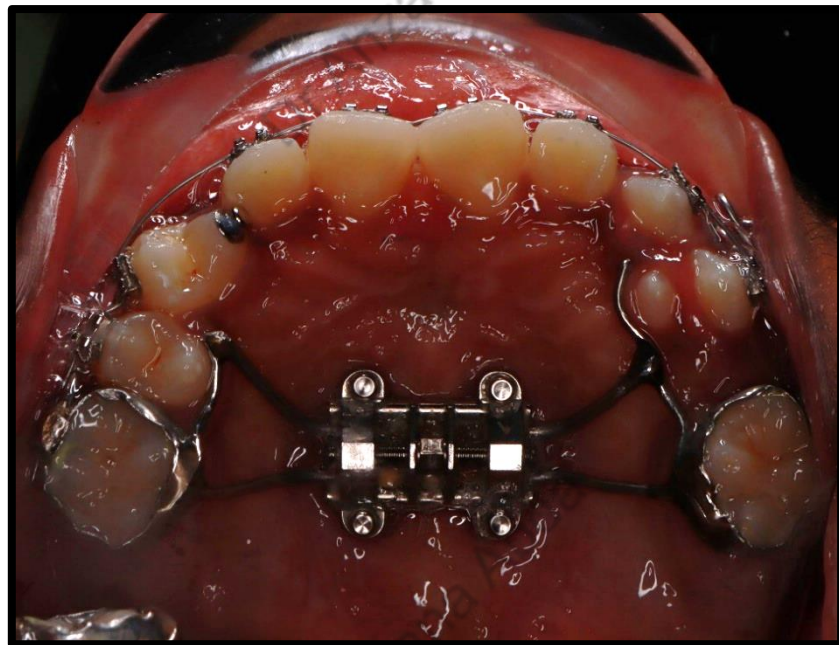
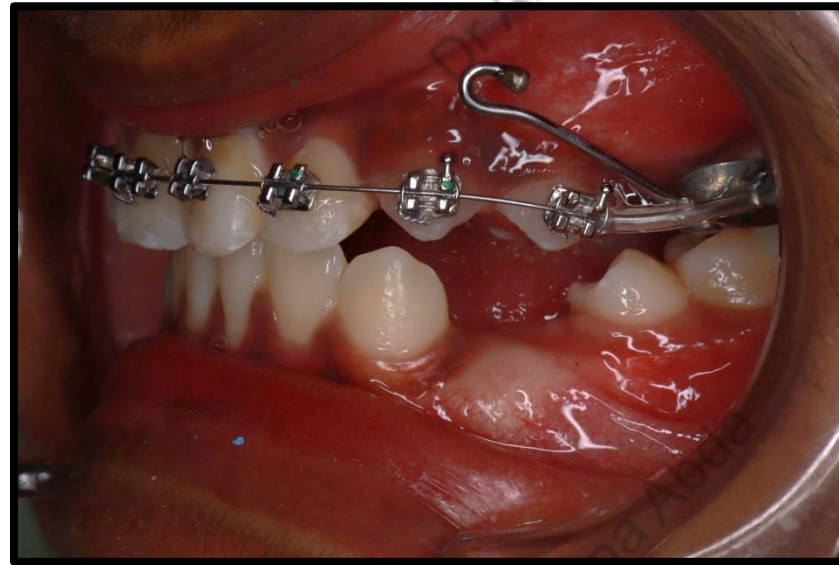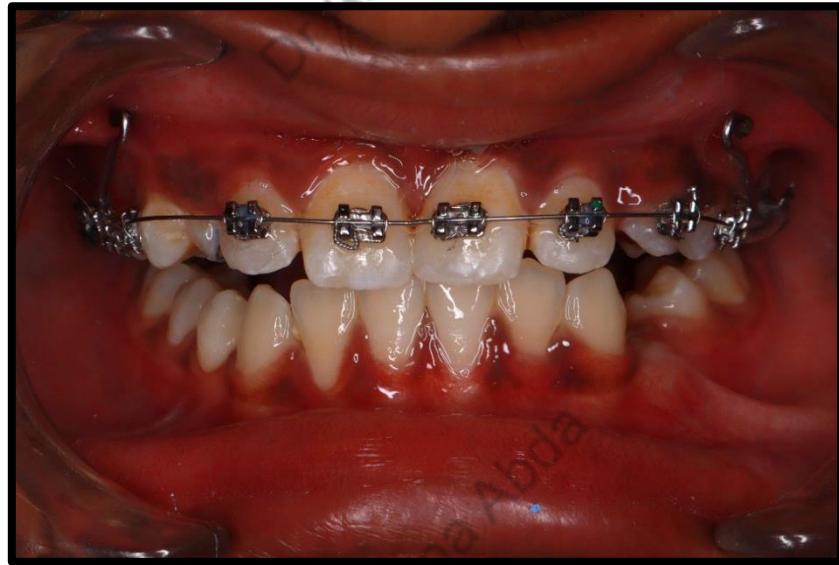
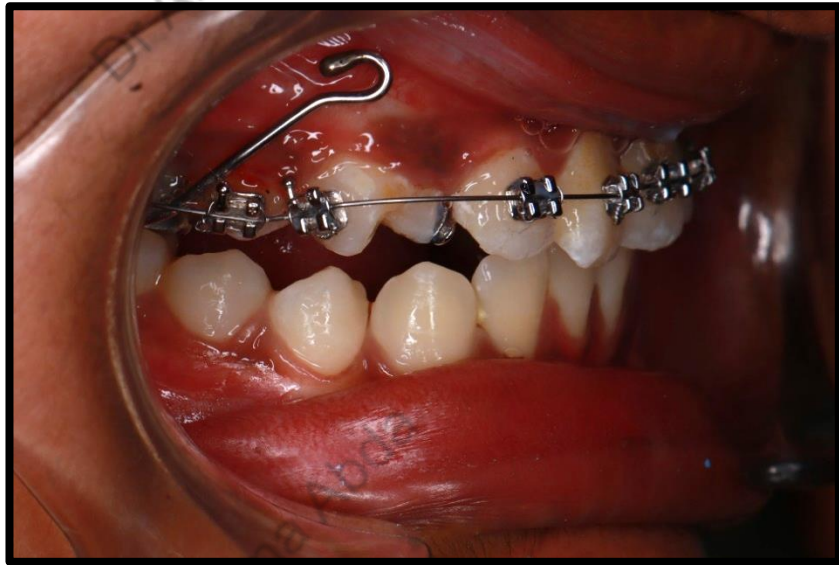


# PRE-END OF PHASE 1 COMPARISON

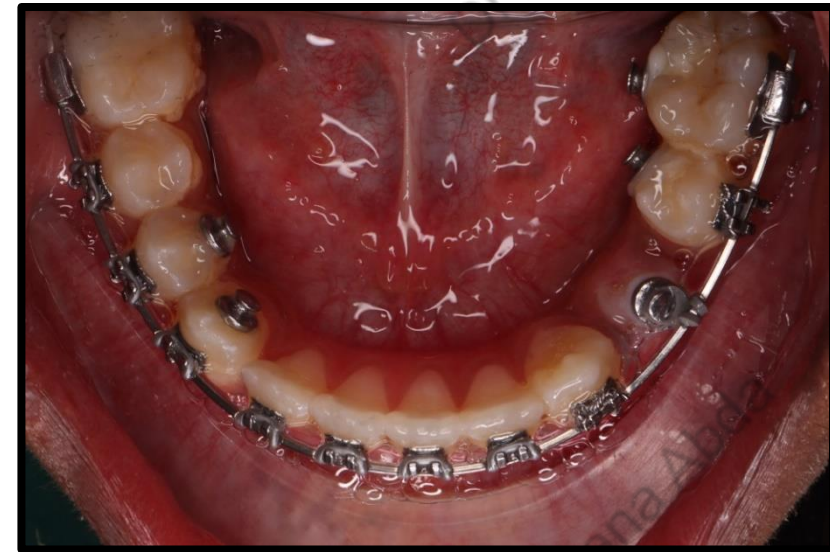
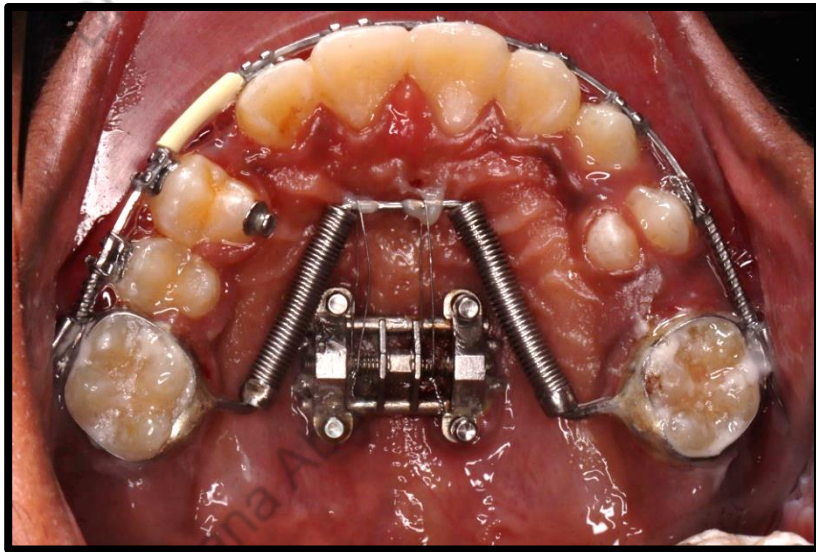
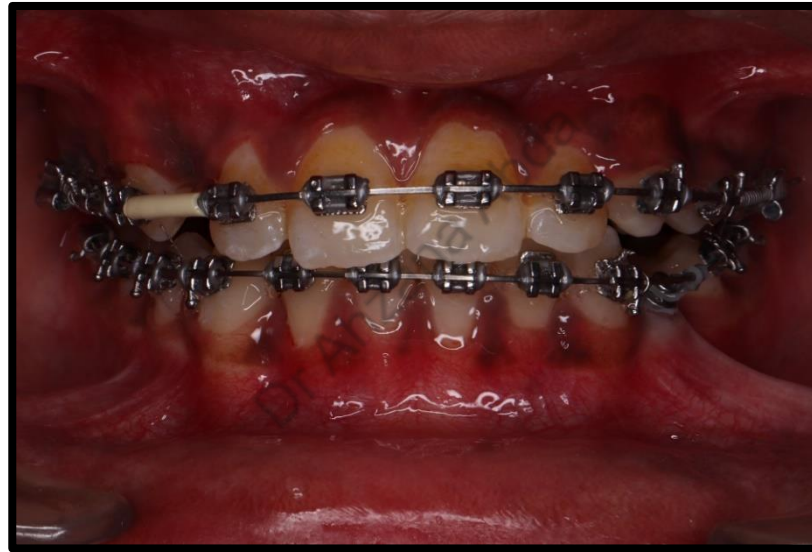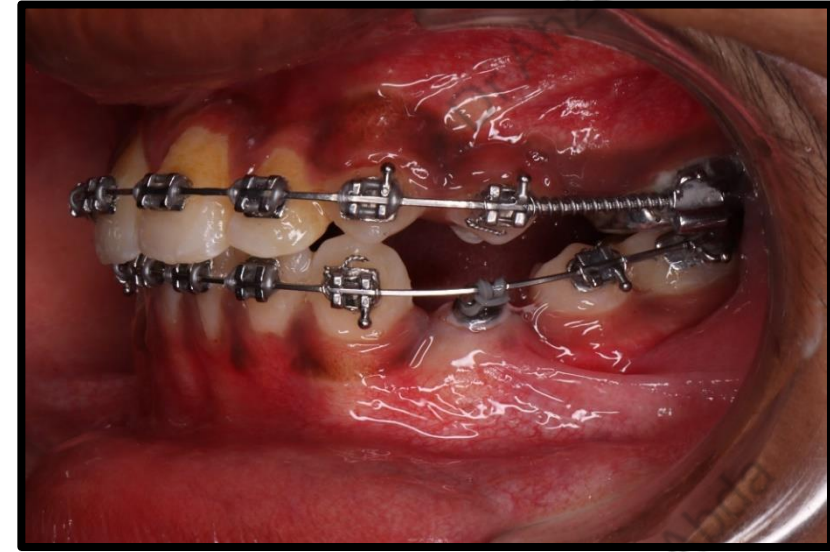

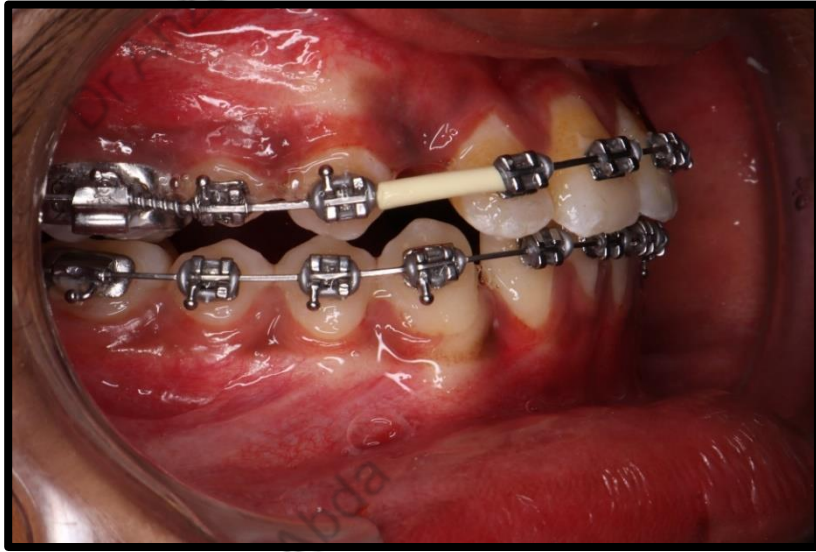
# PRE-END OF PHASE ONE COMPARISON

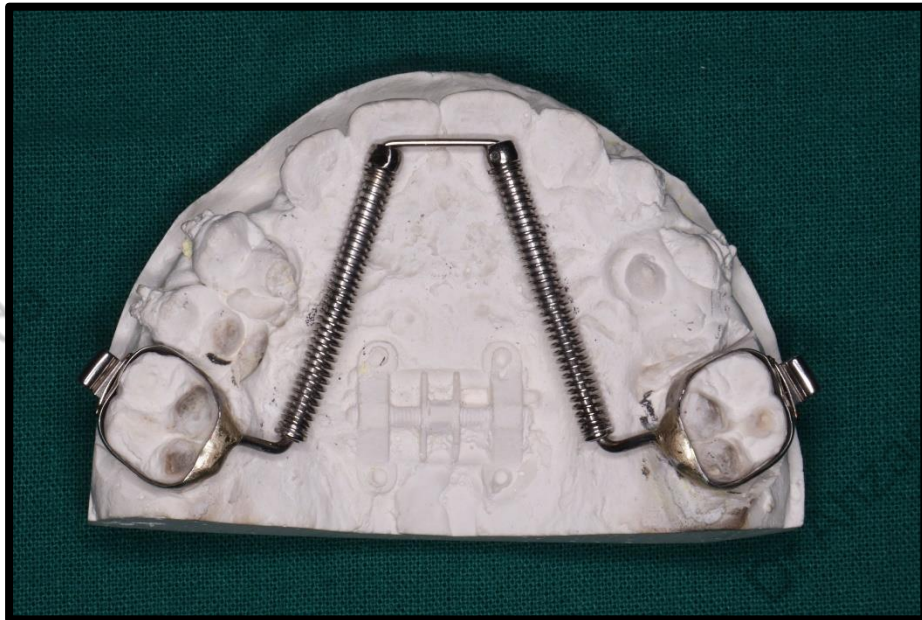




# DISTALIZATION



# DISTALIZATION APPLIANCE

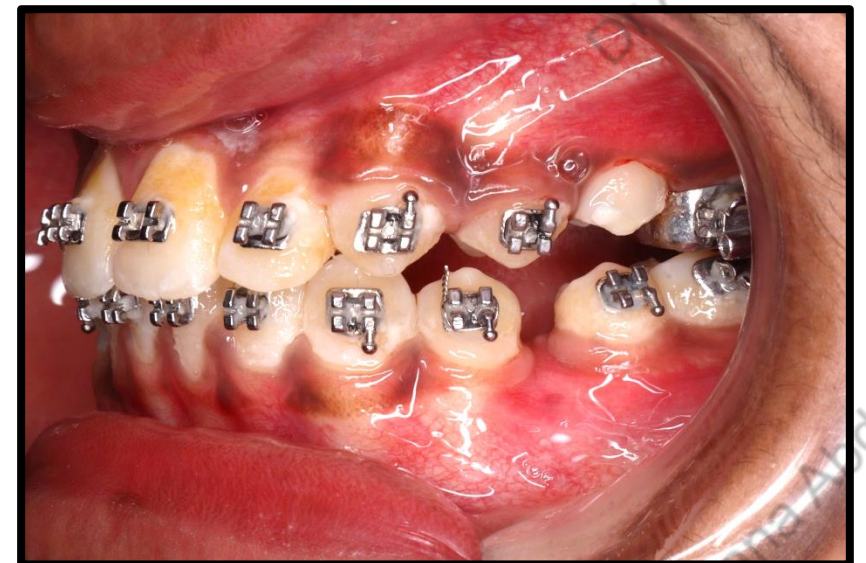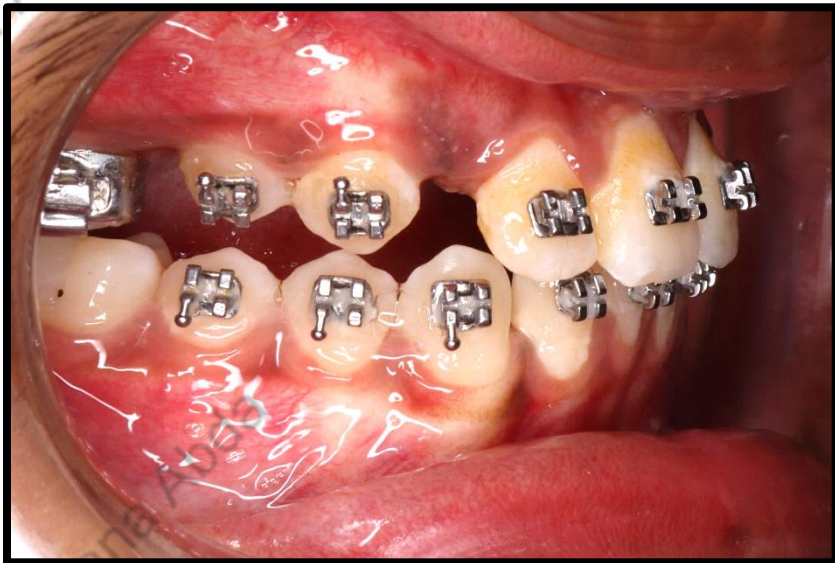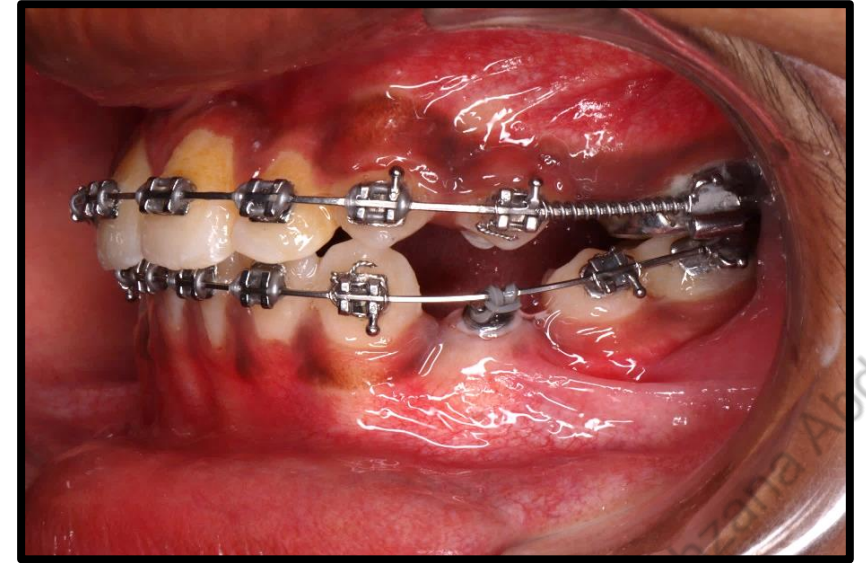


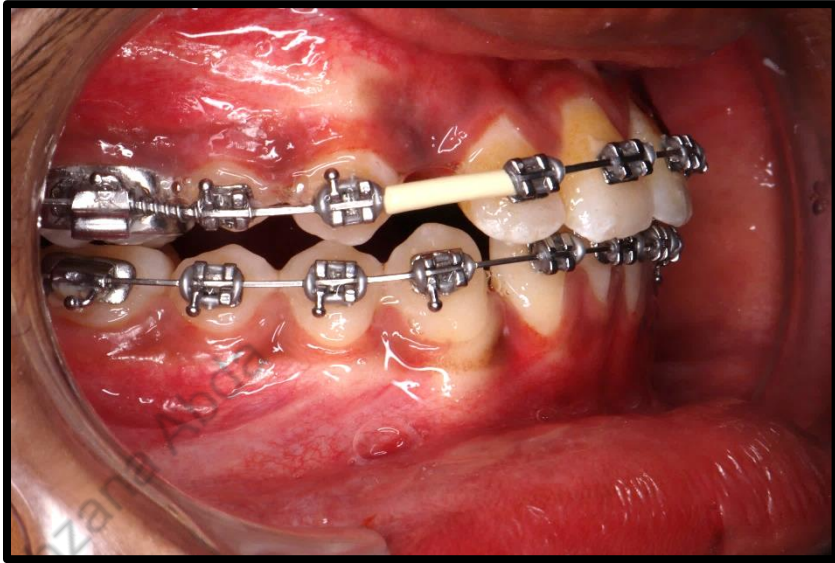C

D

E

# PRE-POST-DISTALIZATION PHOTOGRAPHS




## Amalgamation of Forsus spring module and MSE for distalization : A Novel Hybrid Approach

Author Details : Dr Ahzana Abda\*, Dr Stanly Selva Kumar, Dr Shafees Koya, Dr Ranjan Bhat, Dr Sandeep Shetty,

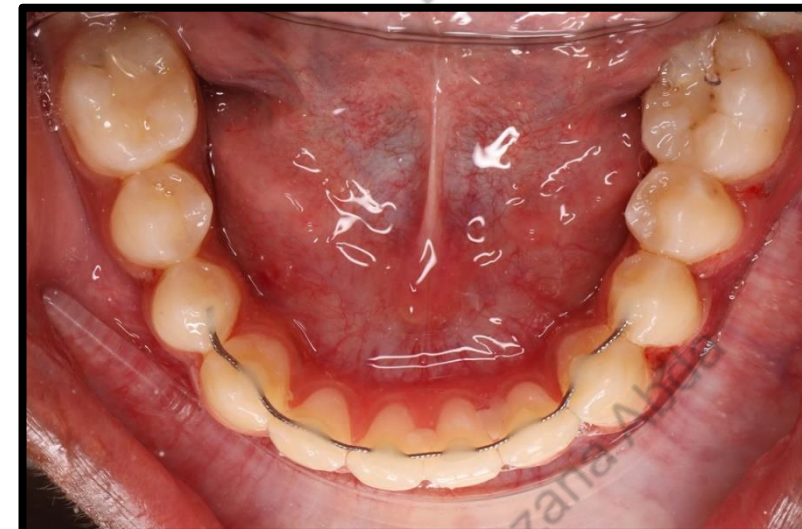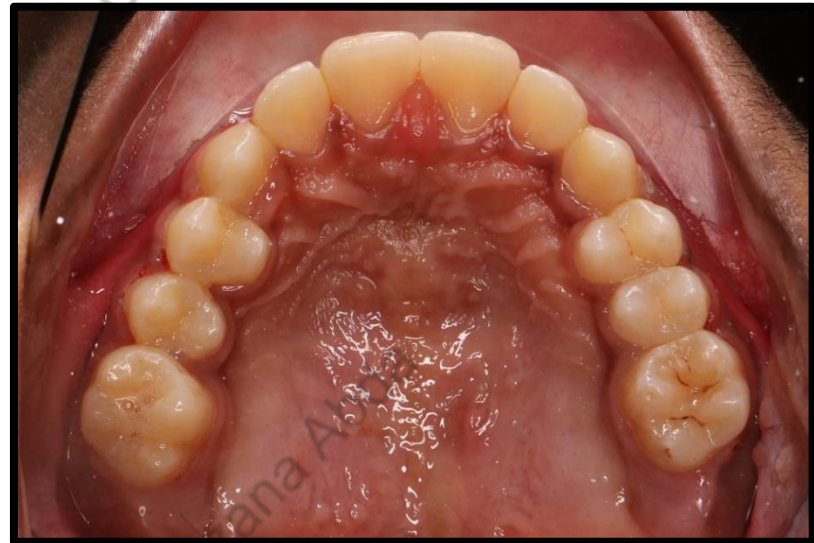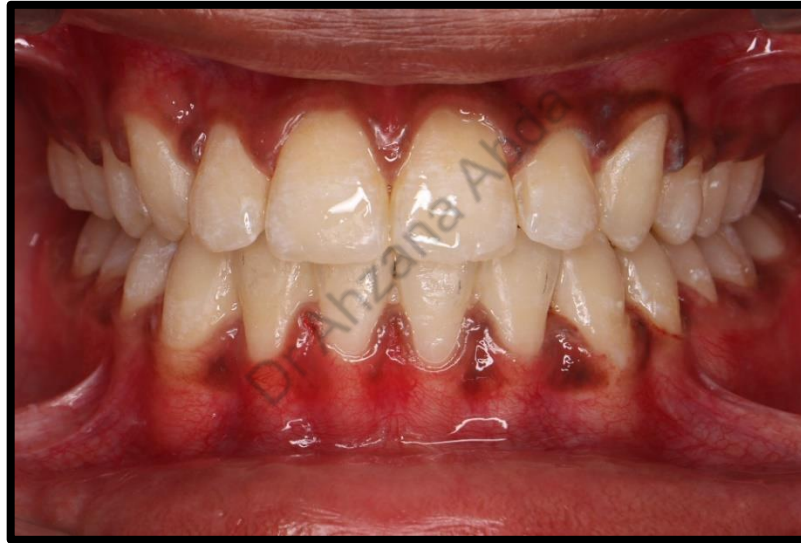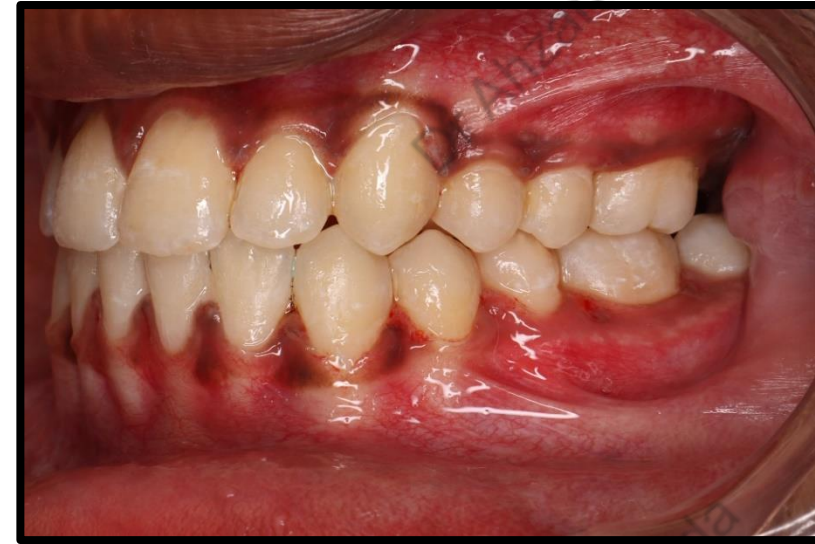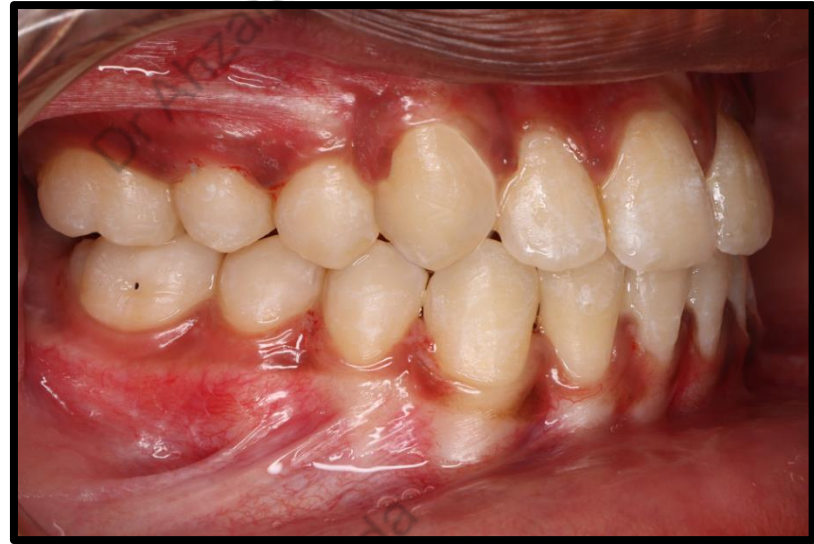A novel hybrid approach using the Maxillary Skeletal Expander (MSE) and Forsus spring module for molar distalization in class II malocclusion treatment, aiming to simplify procedures and enhance clinical outcomes by transitioning patients from class II to class I occlusion effectively



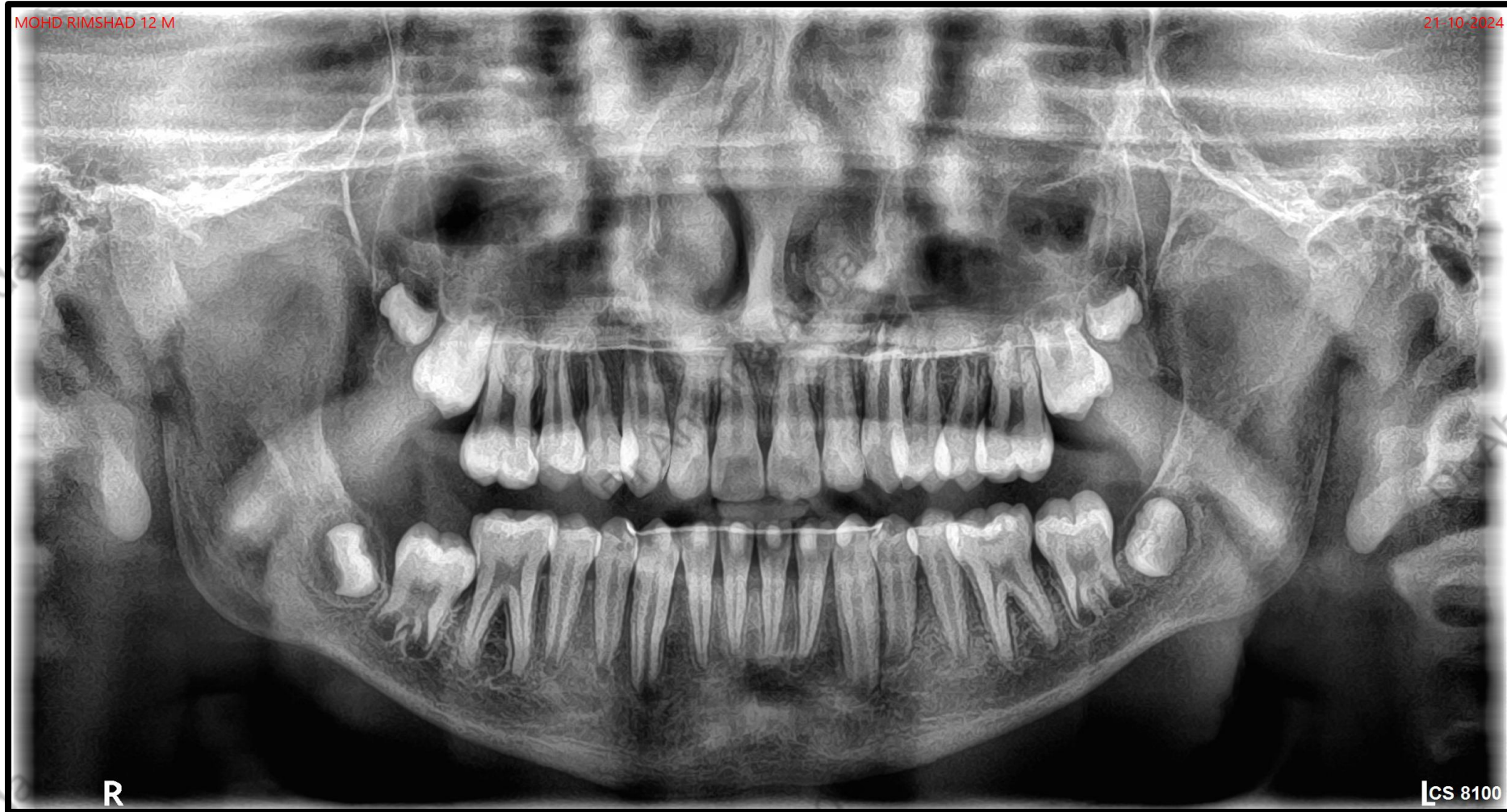
**POST TREATMENT-EXTRAORAL**

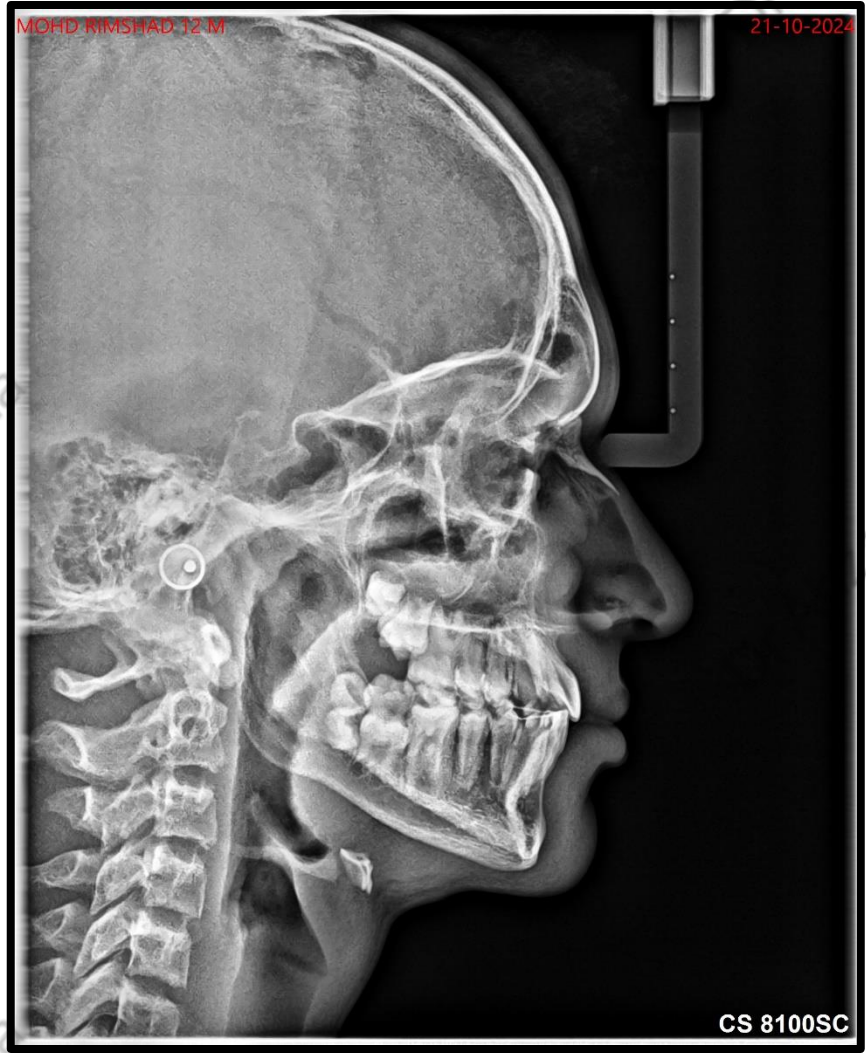
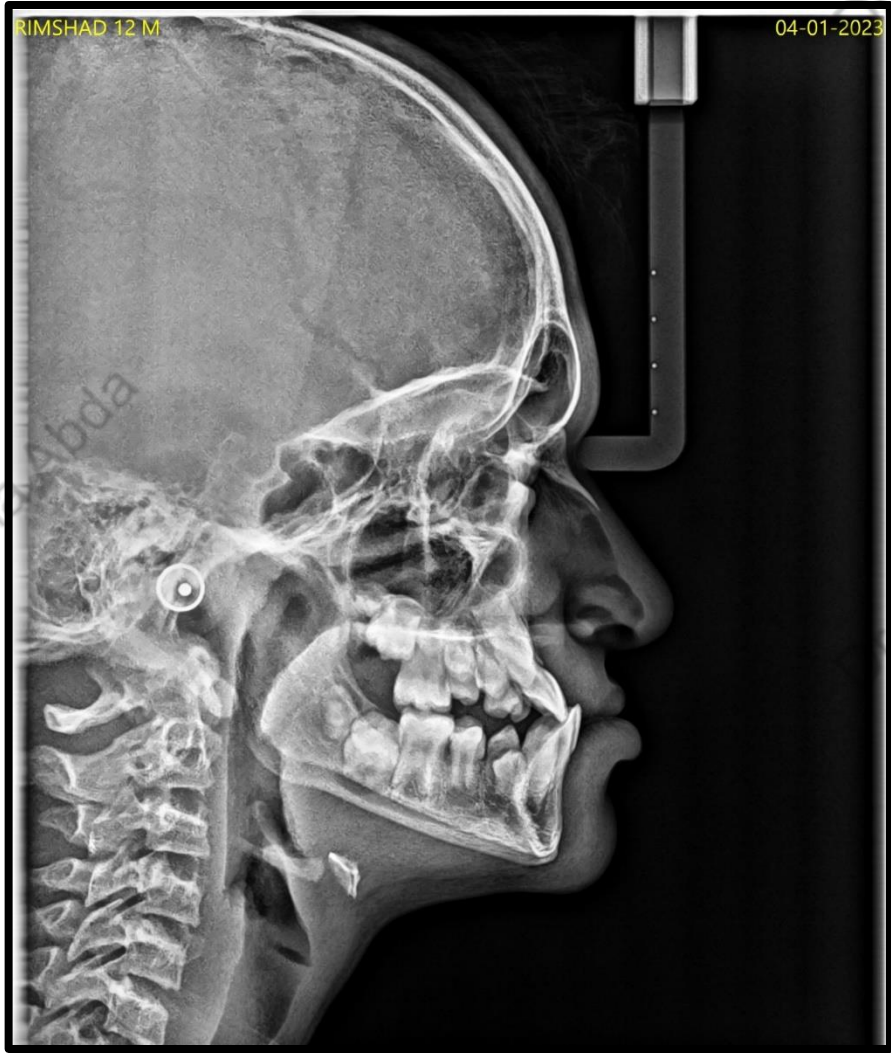

**POST TREATMENT-  
INTRAORAL**

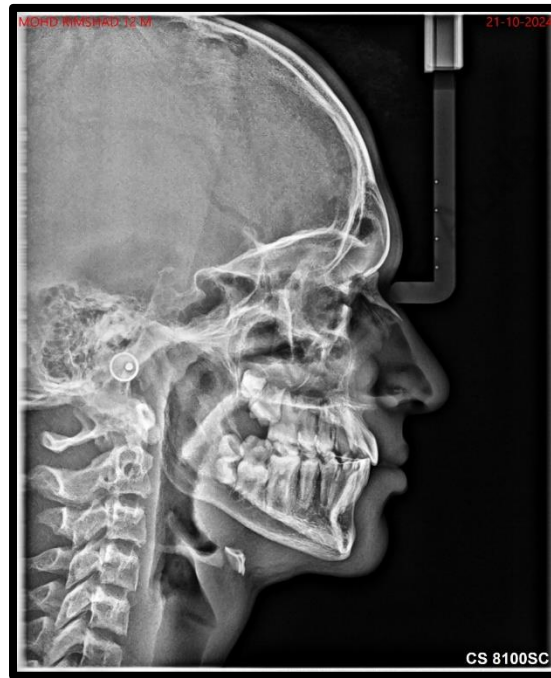
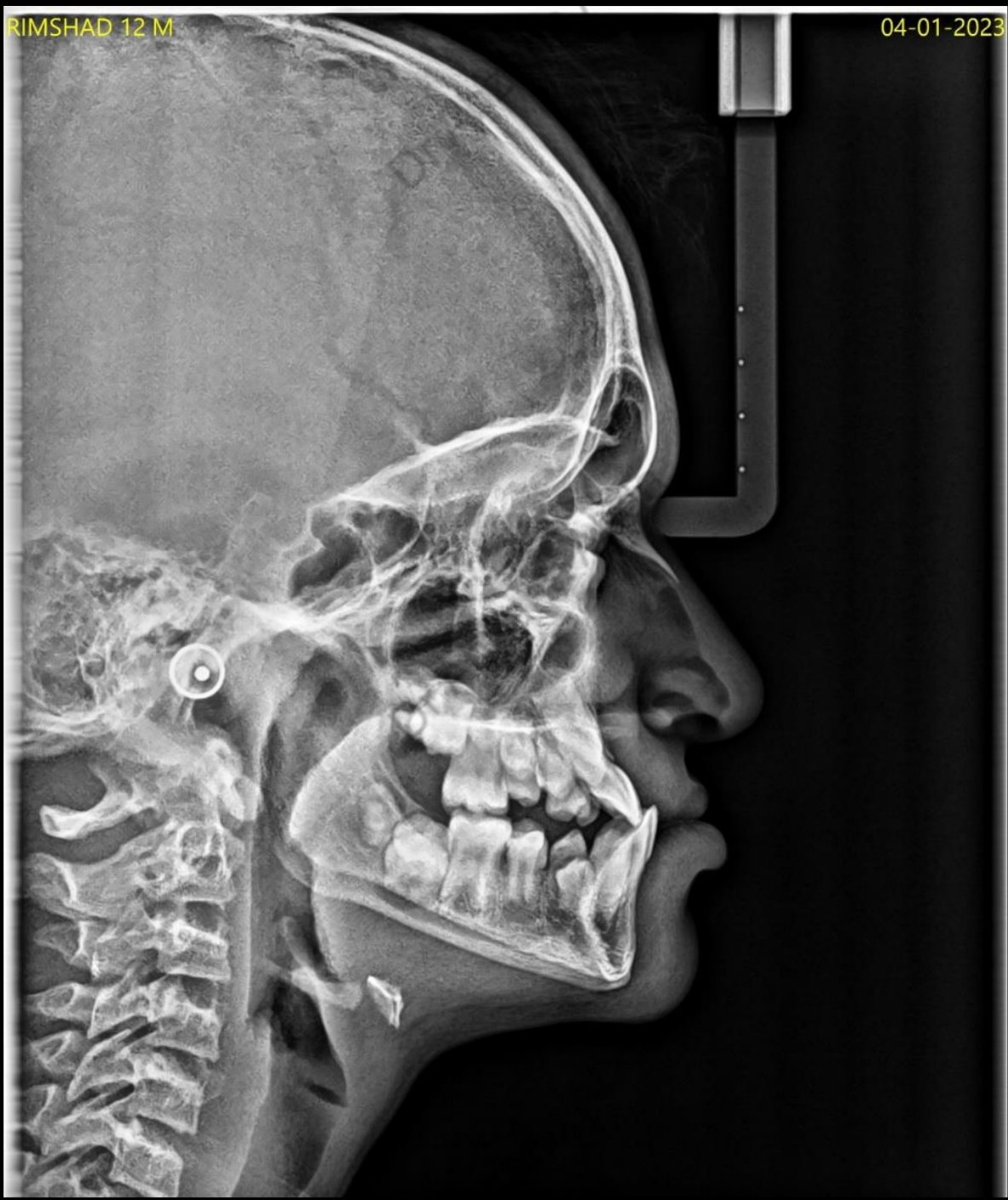
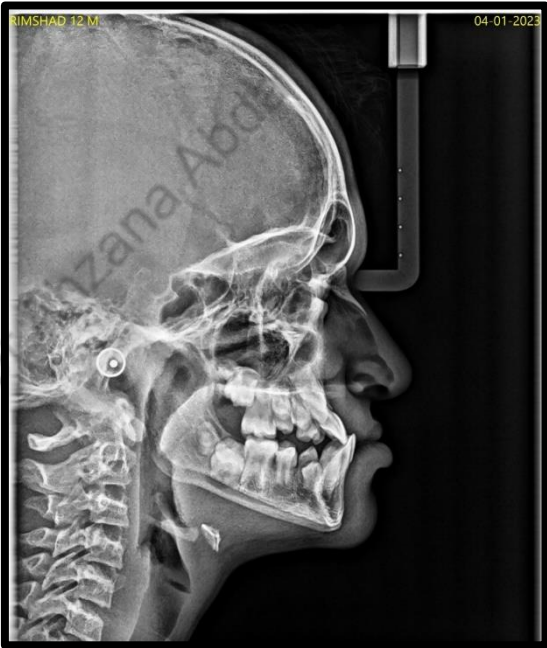# POST-OPG



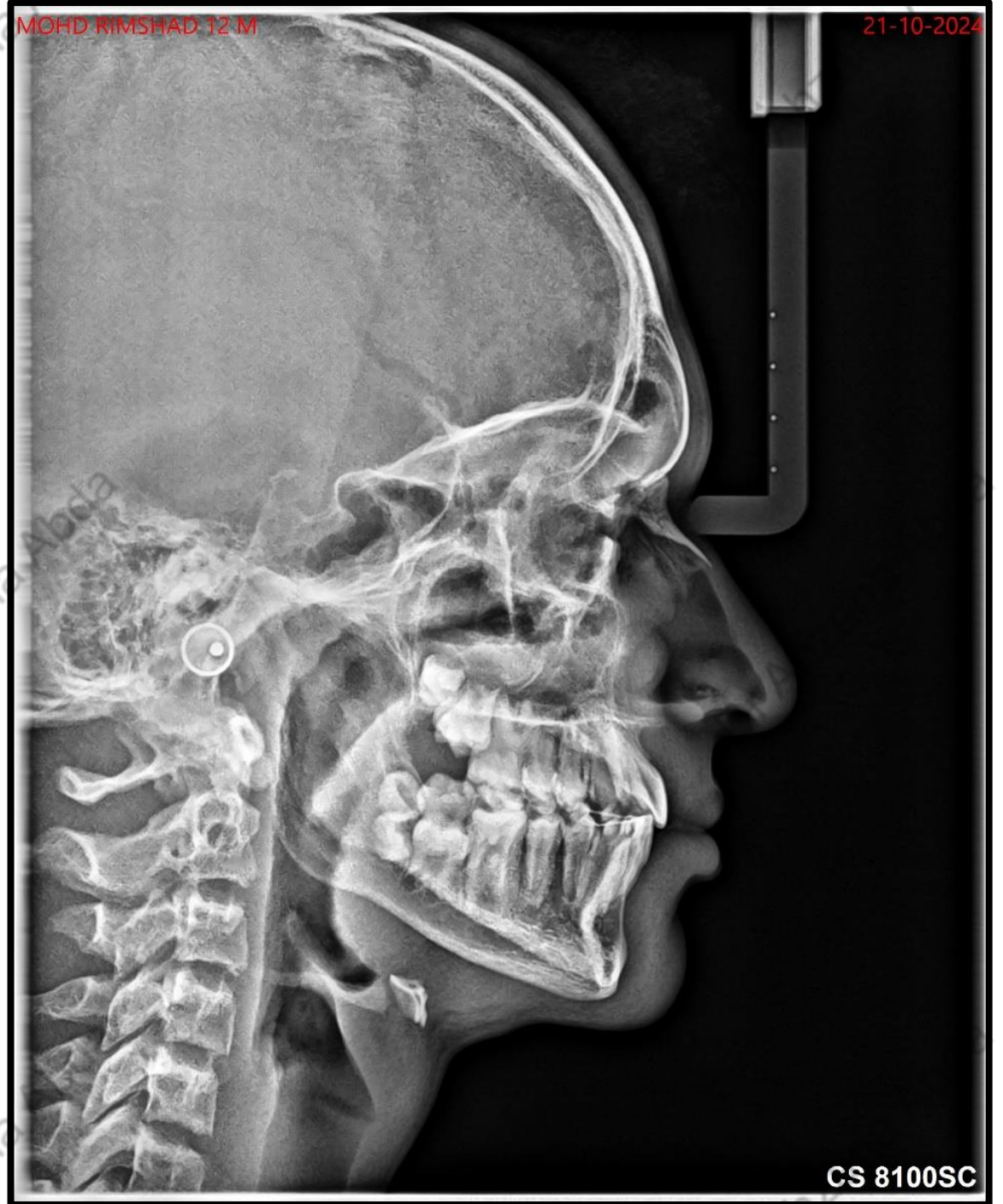


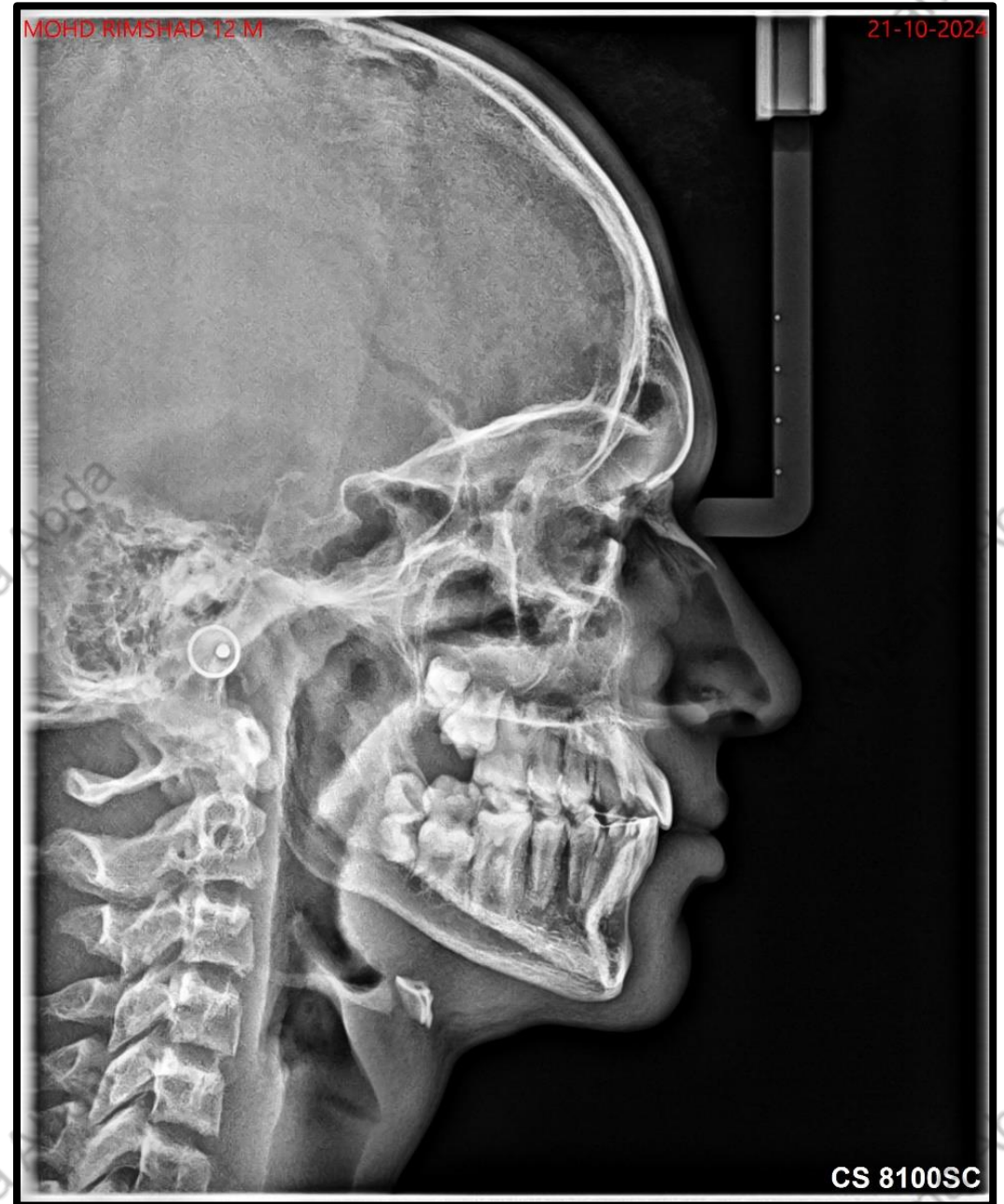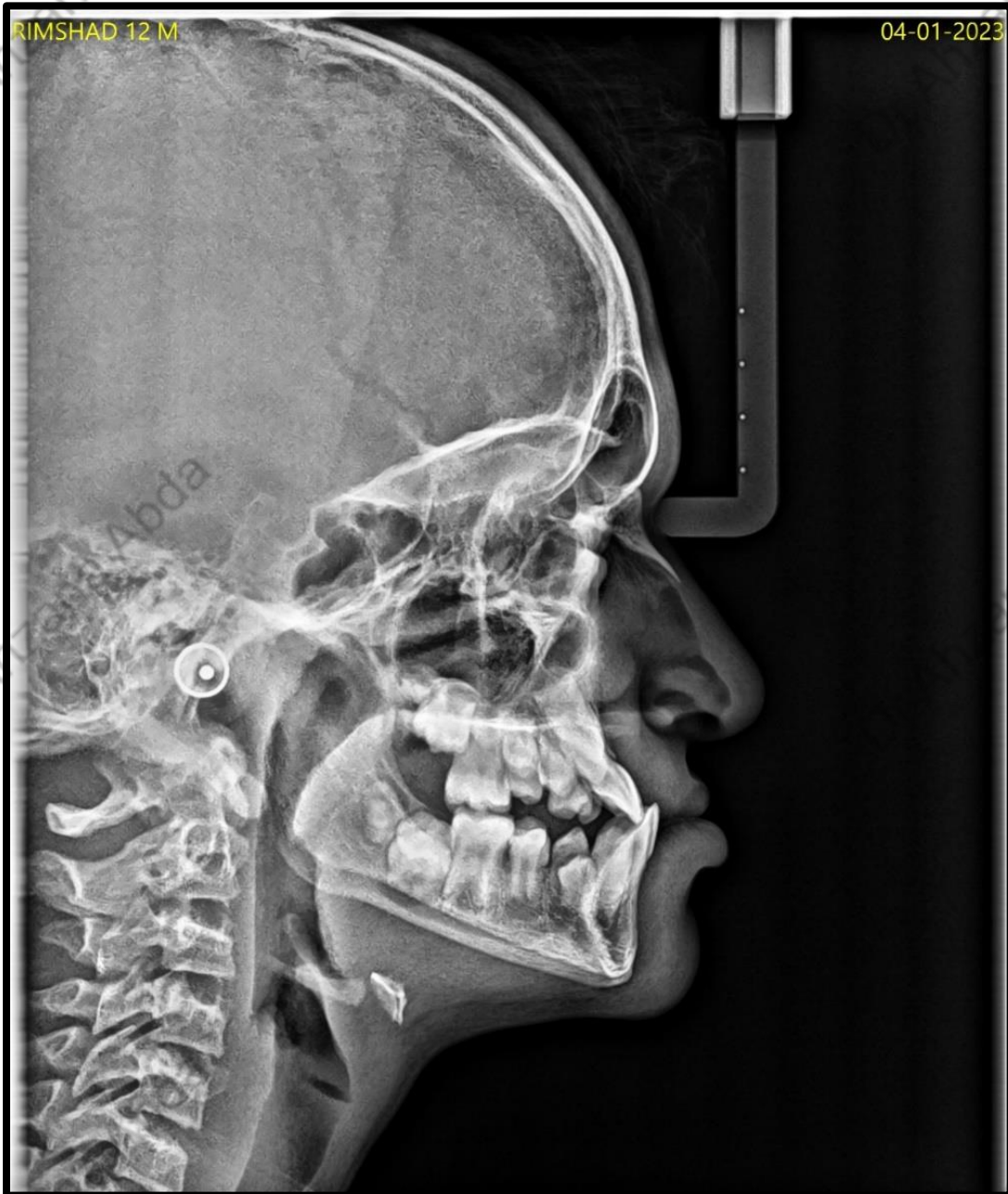**PRE TREATMENT -  
LATERAL  
CEPHALOGRAM**





**POST -LATERAL  
CEPHALOGRAM**

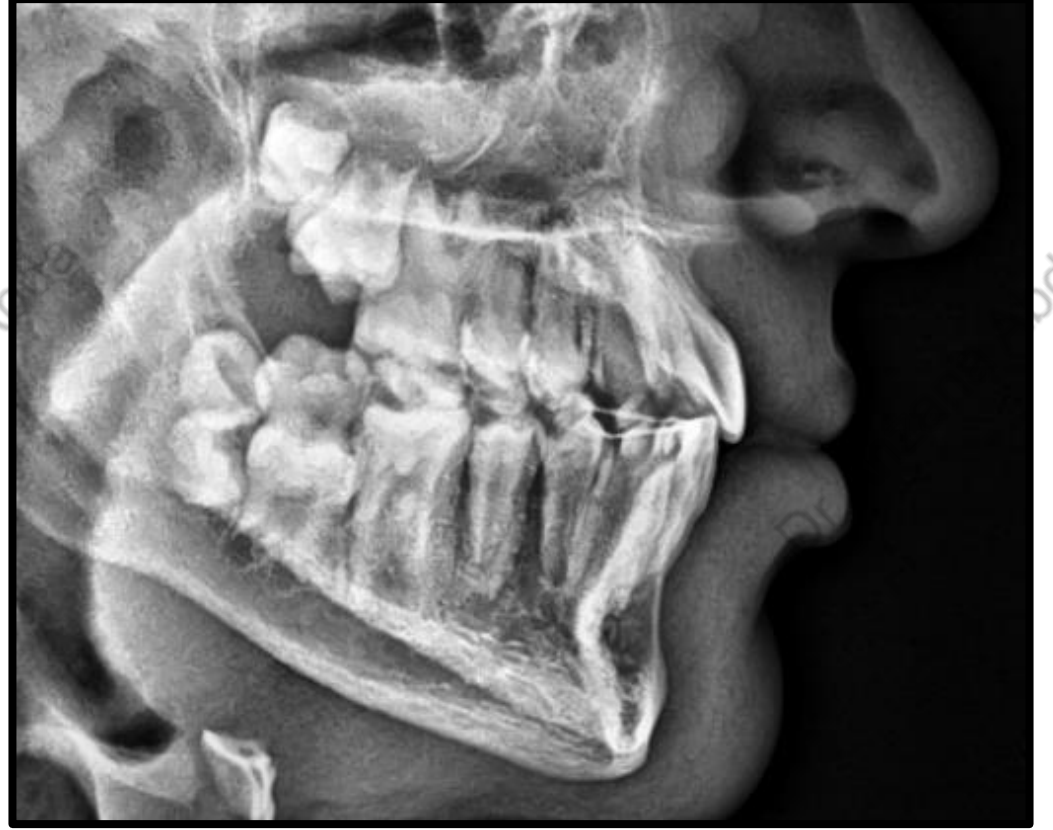
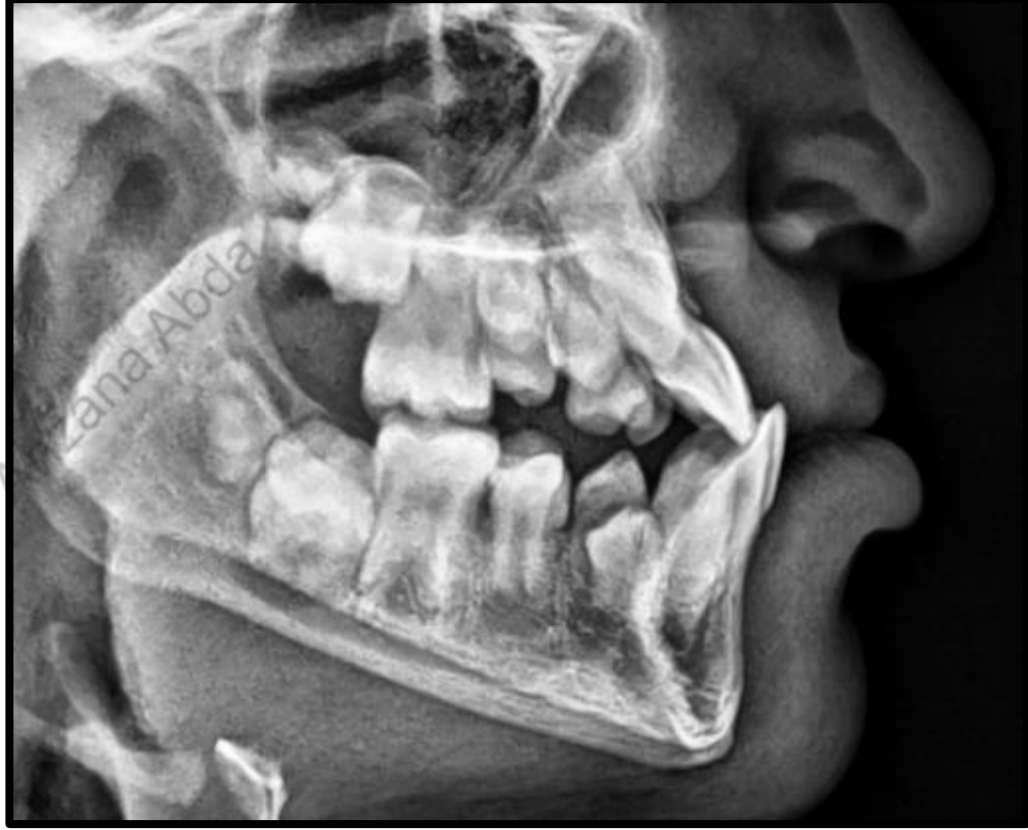


Dr Ahzana Abda

Dr Ahzana Abda

Dr Ahzana Abda



Dr Ahzana Abda

Dr Ahzana Abda

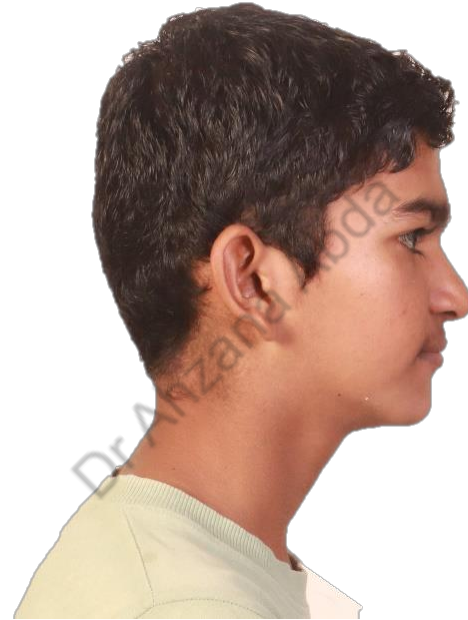
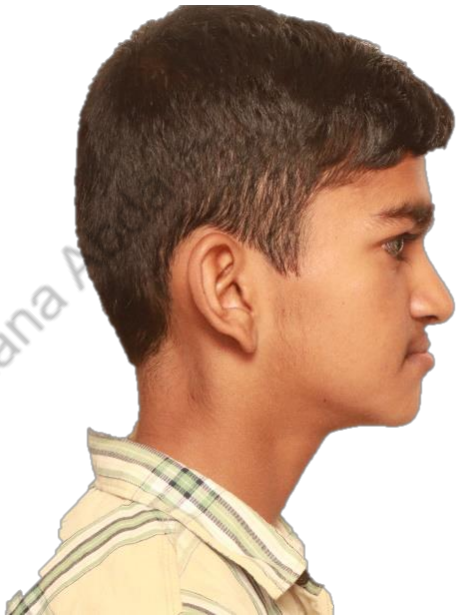Abda

Dr Ahzana Abda

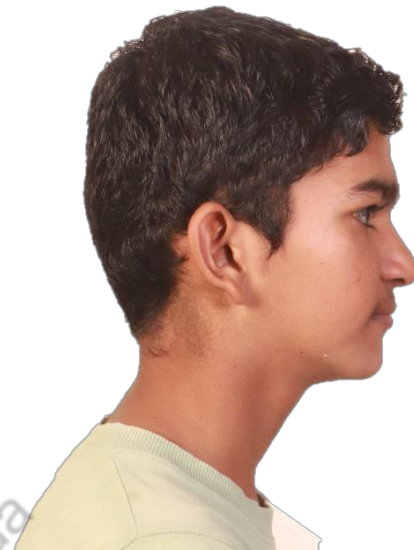
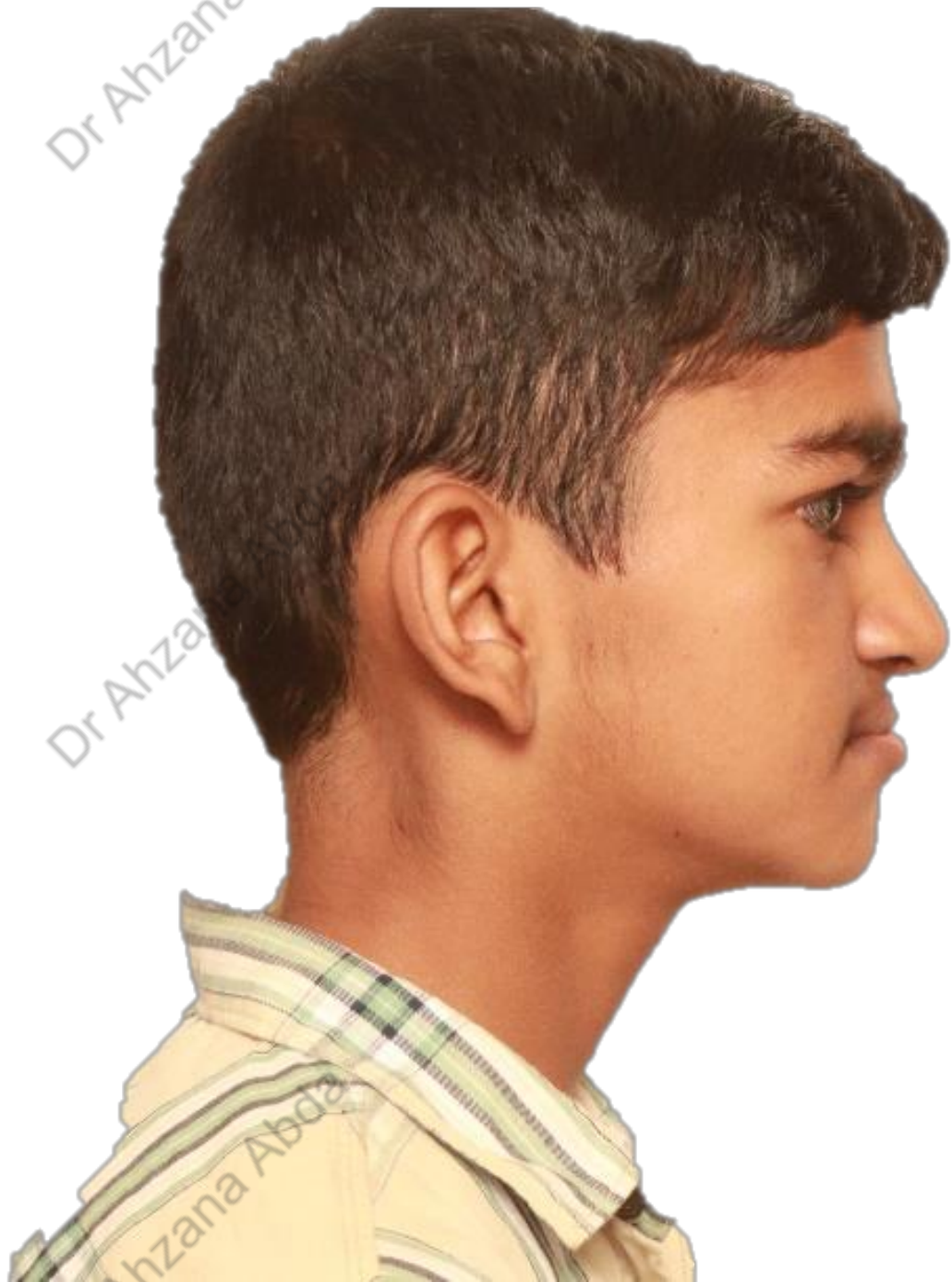Dr Ahzana Abda

Dr Ahzana Abda

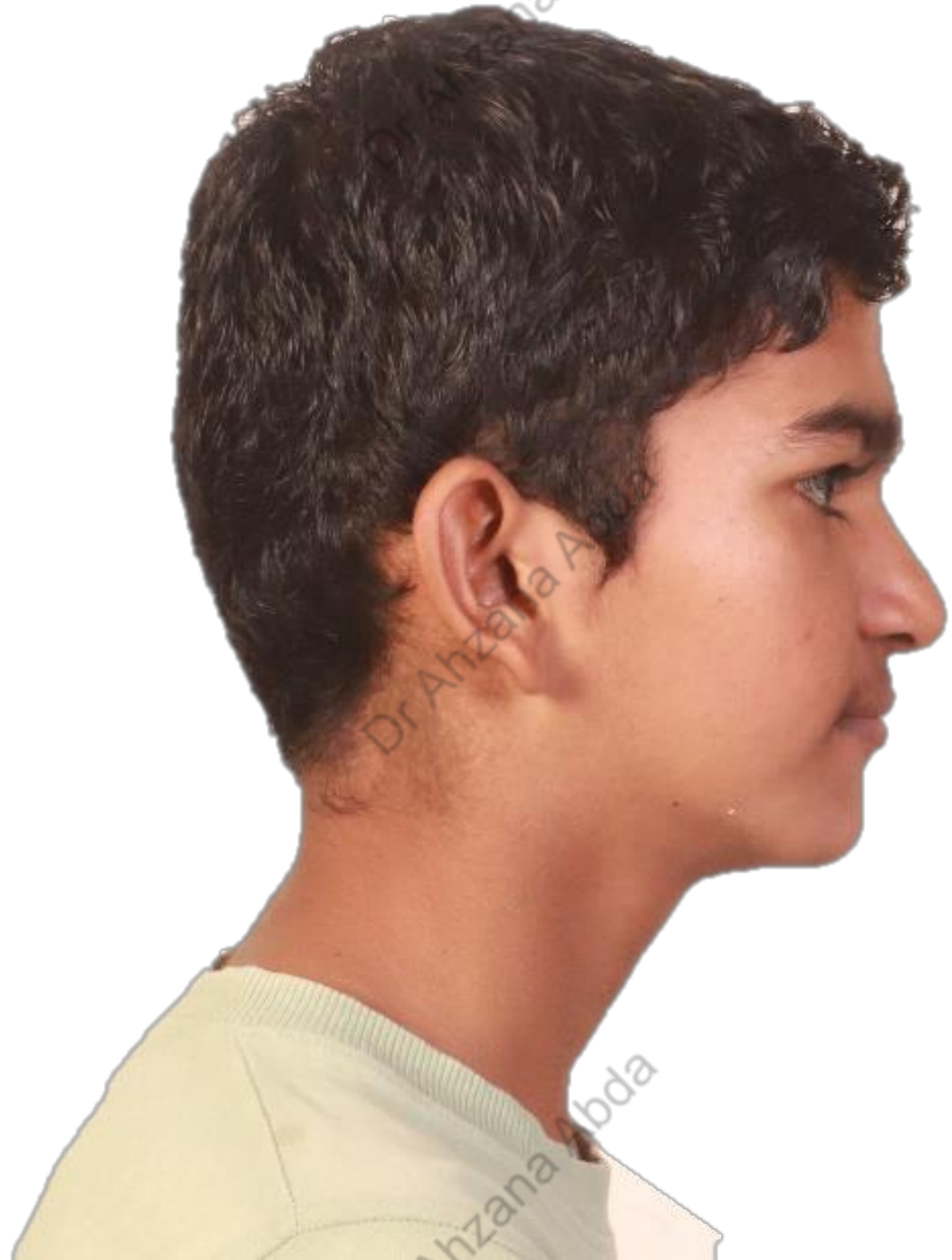
# EXTRAORAL COMPARISON PROFILE



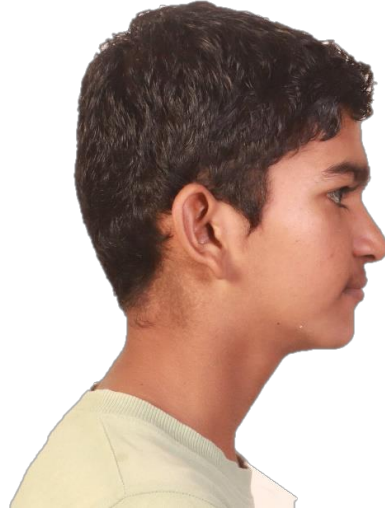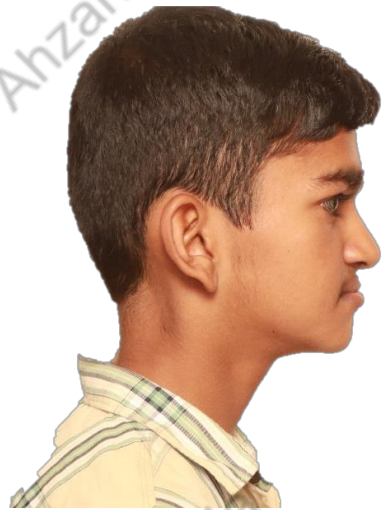
**EXTRAORAL PRE PROFILE**




**EXTRAORAL  
AFTER PHASE I  
PROFILE**



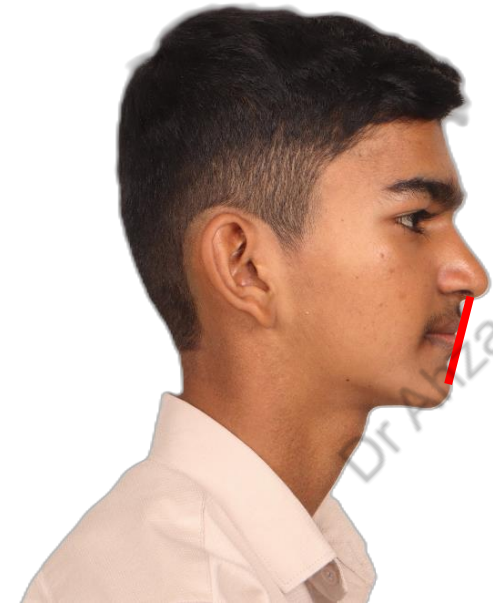
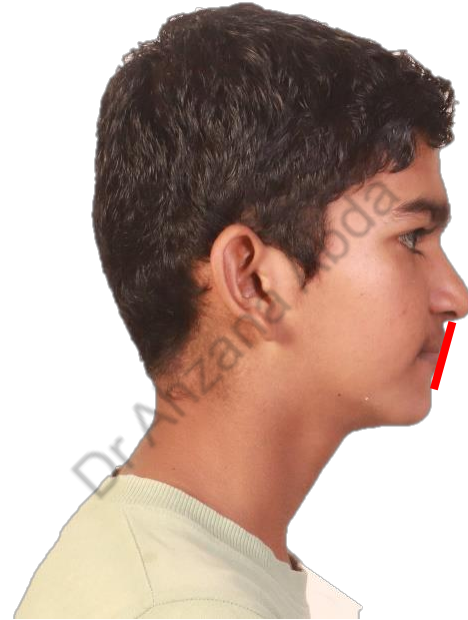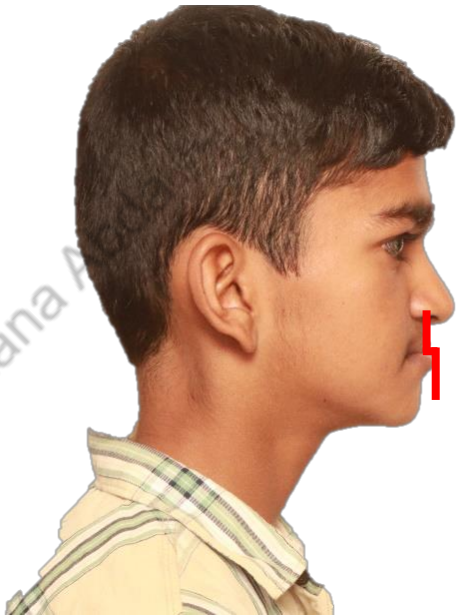
**EXTRAORAL POST PROFILE**



# EXTRAORAL COMPARISON PROFILE



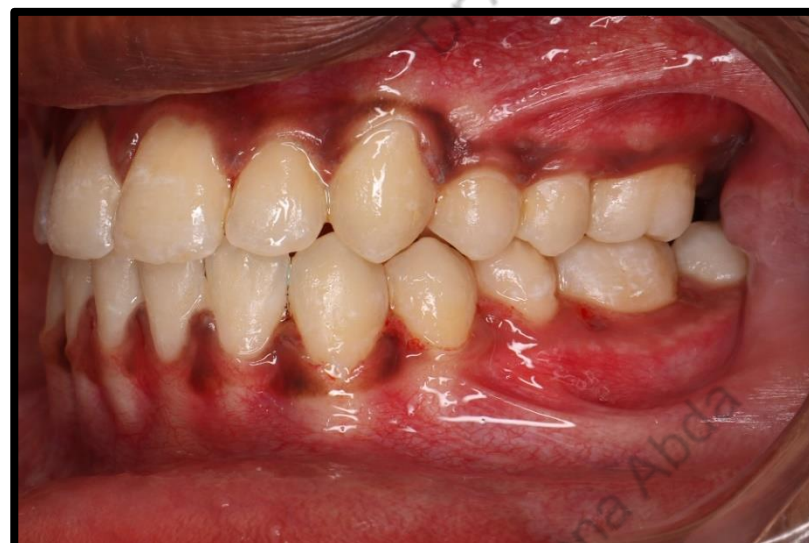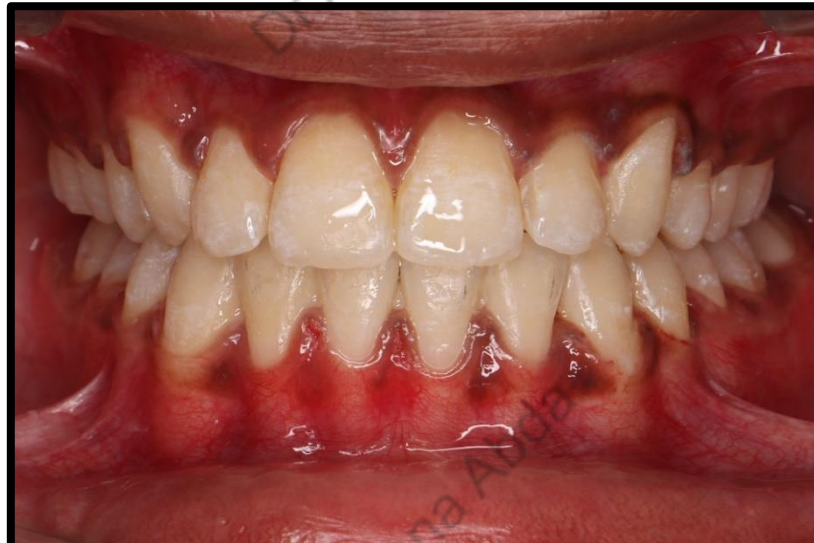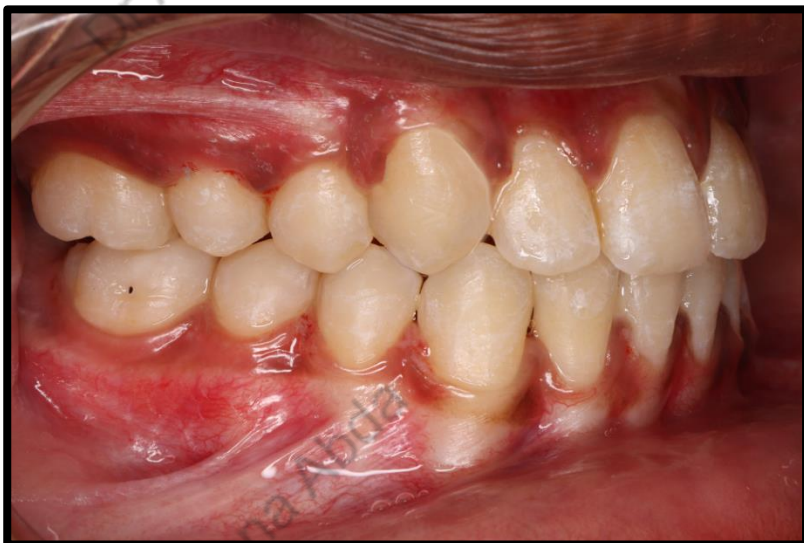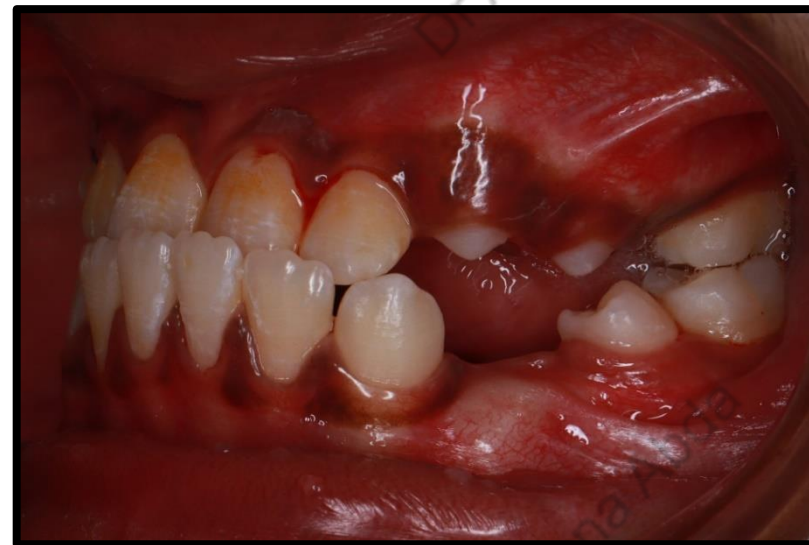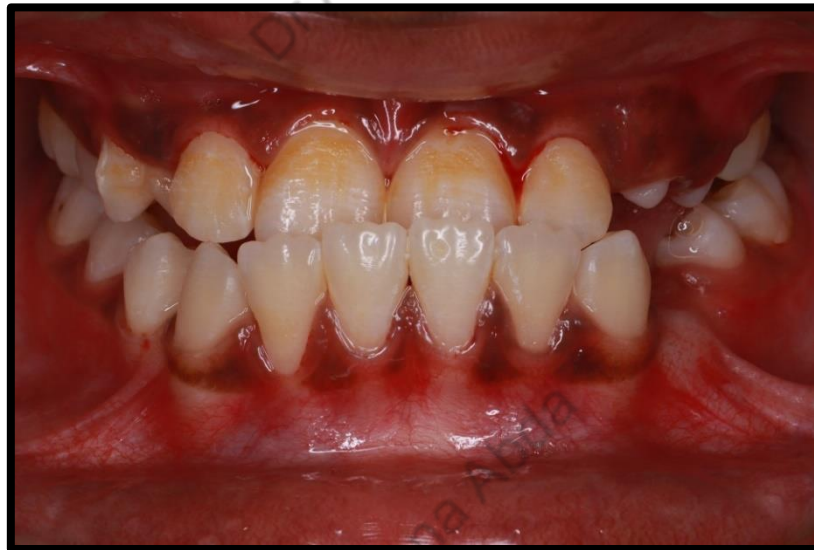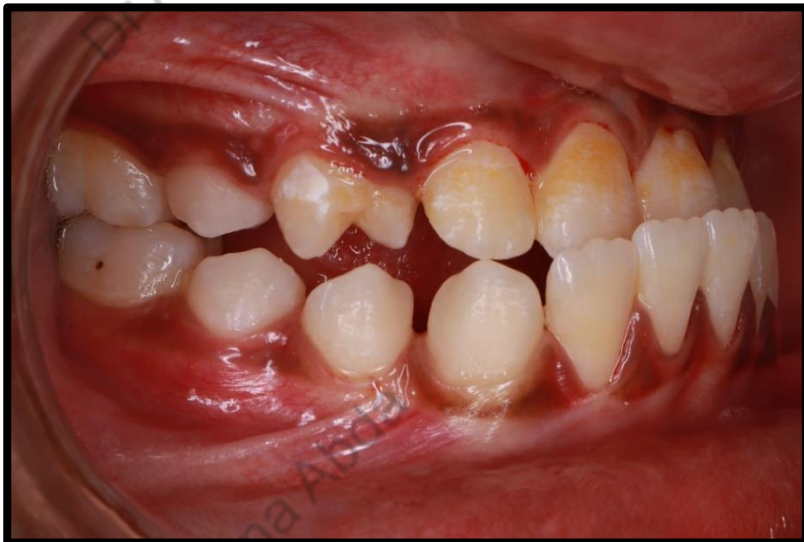# EXTRAORAL COMPARISON PROFILE



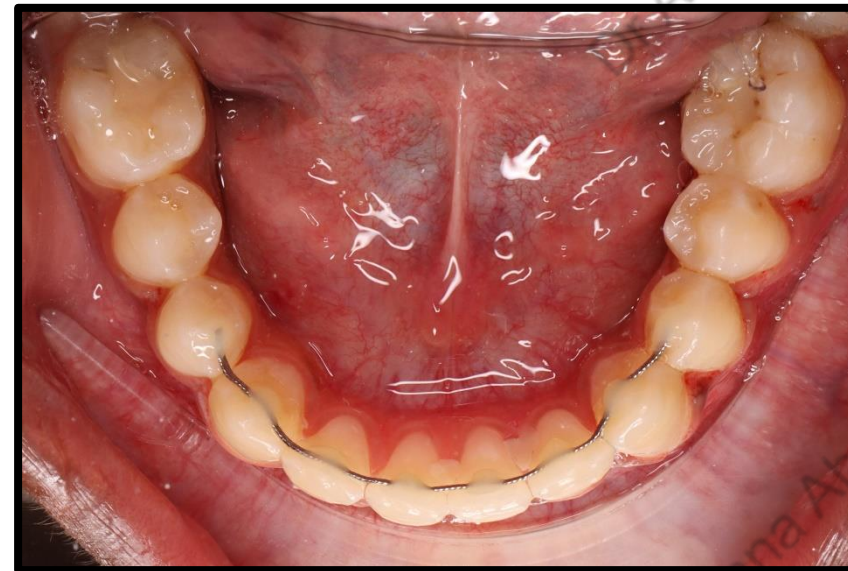
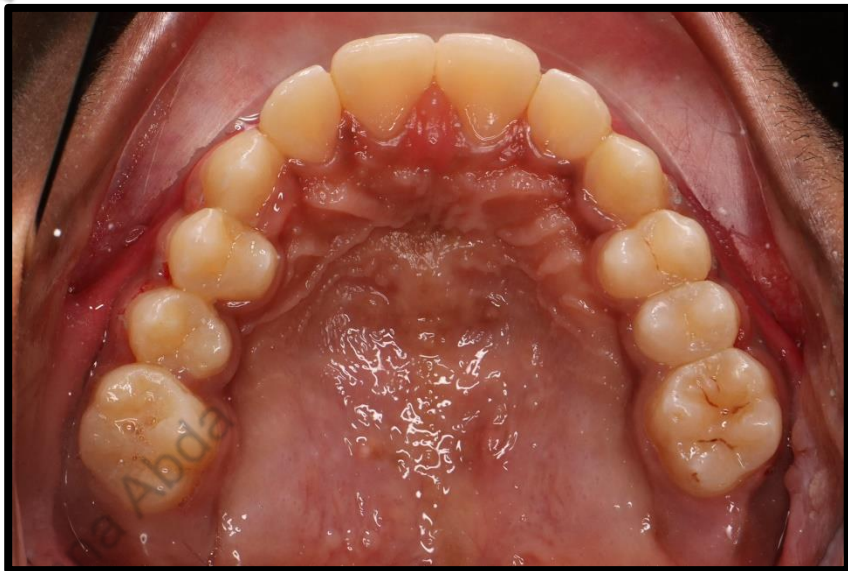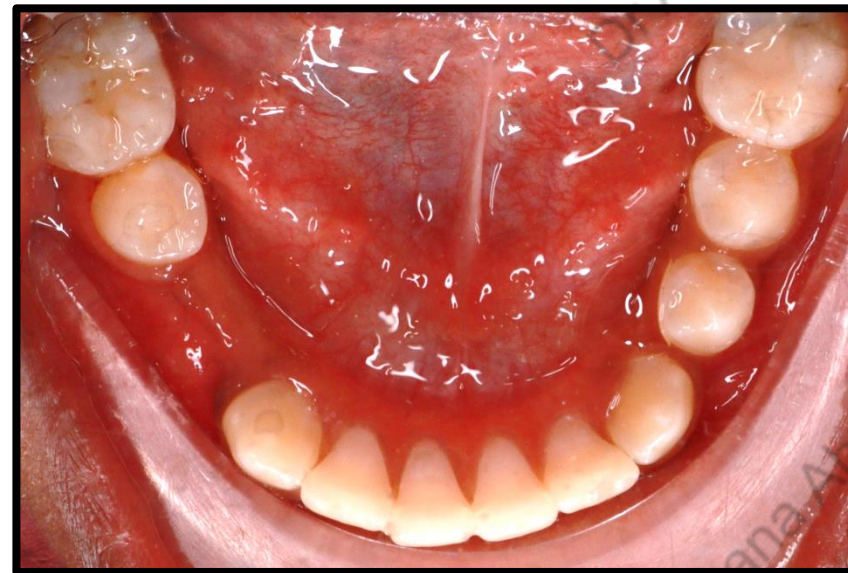
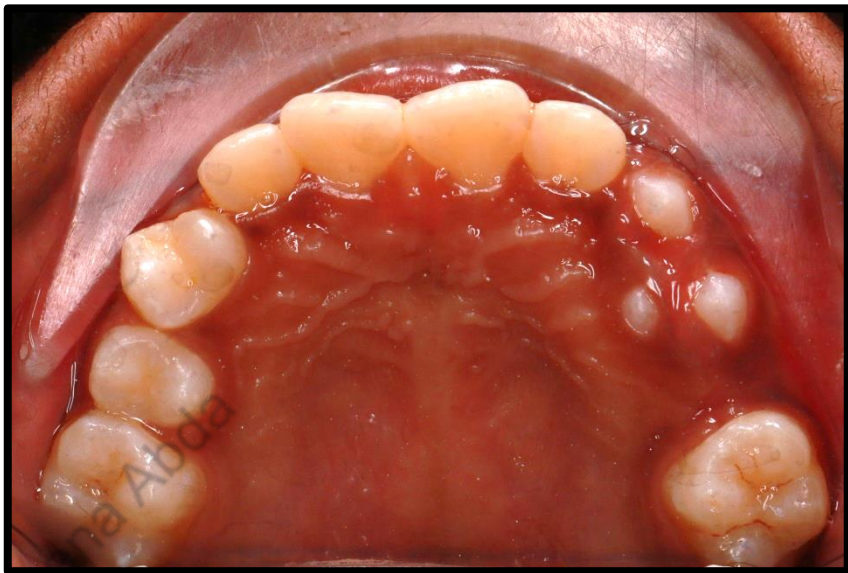# EXTRAORAL COMPARISON FRONTAL



# INTRAORAL COMPARISON



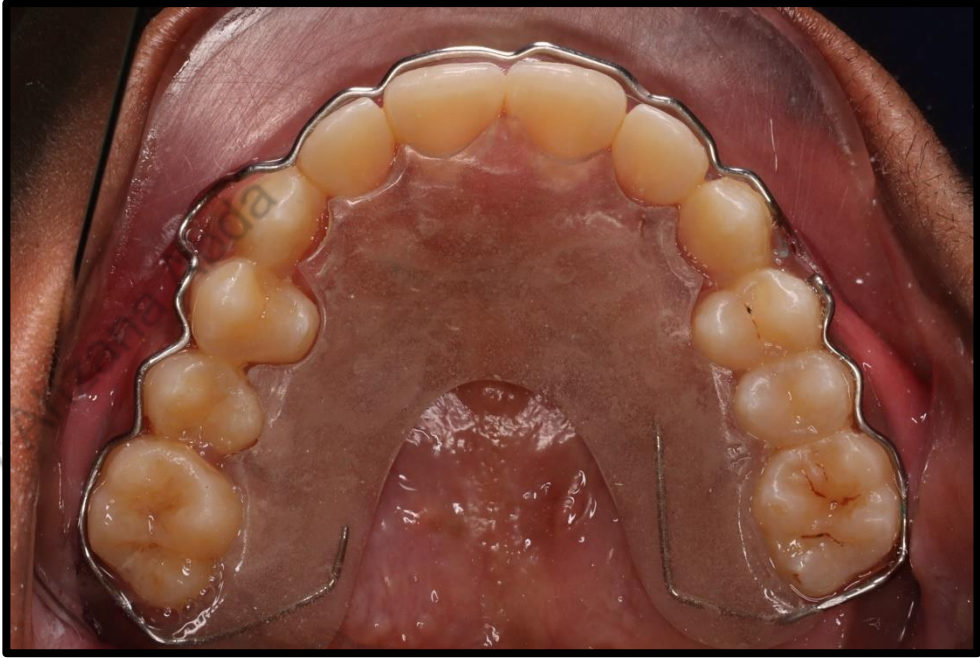
# INTRAORAL COMPARISON



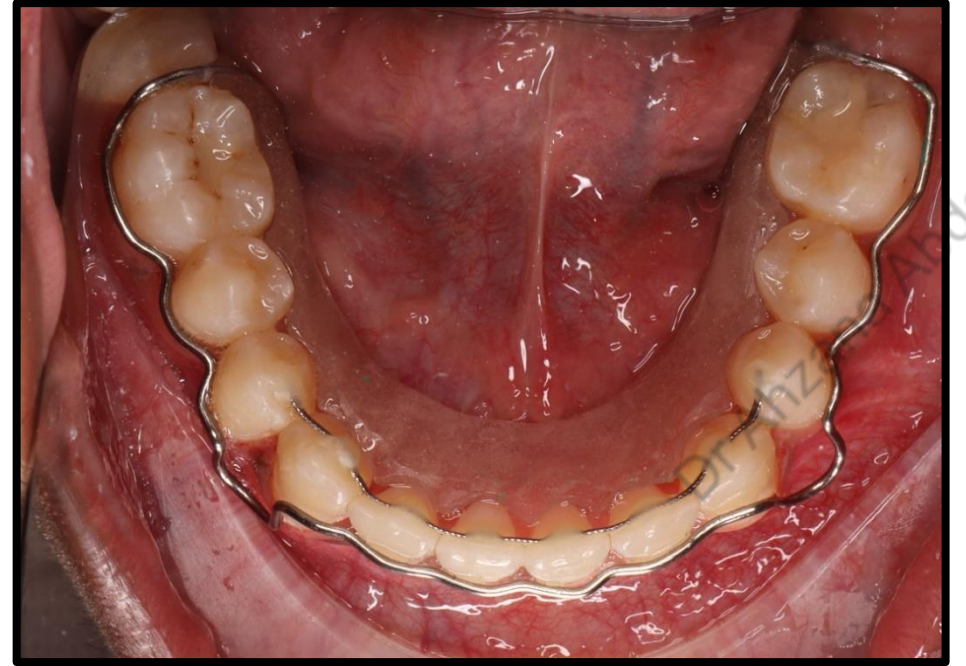
Dr Ahzana Abda

Dr Ahzana Abda

Dr Ahzana Abda



Dr Ahzana Abda

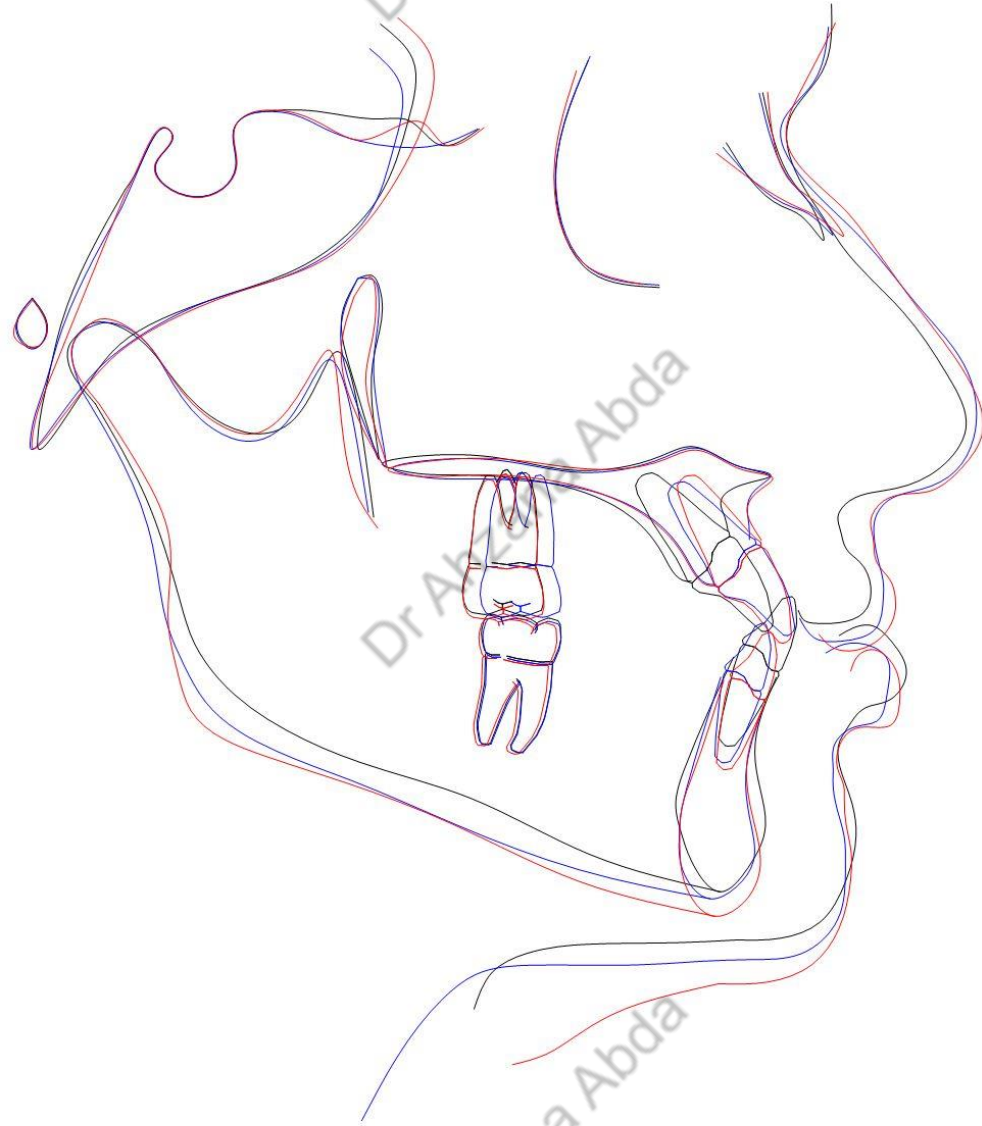


Dr Ahzana Abda

Dr Ahzana Abda

Dr Ahzana Abda

# SUPERIMPOSITION



# CASE IV

**CHINMAY 13/M**

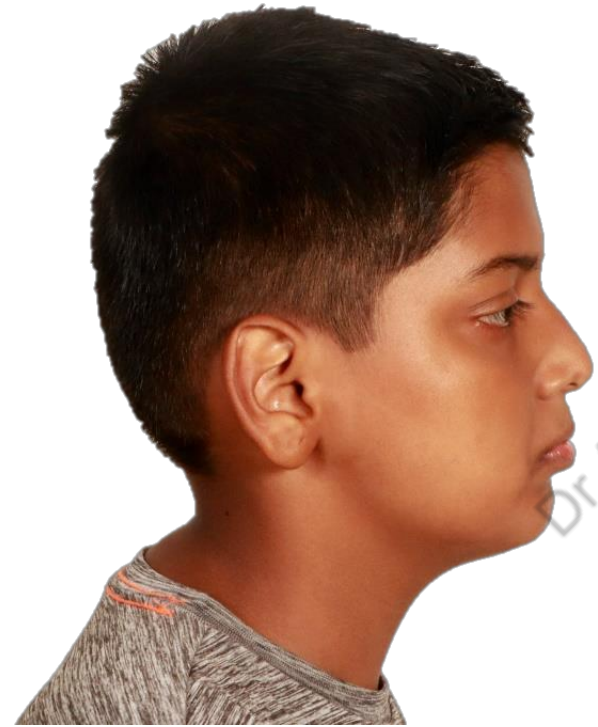**PRE-TREATMENT-EXTRA ORAL**



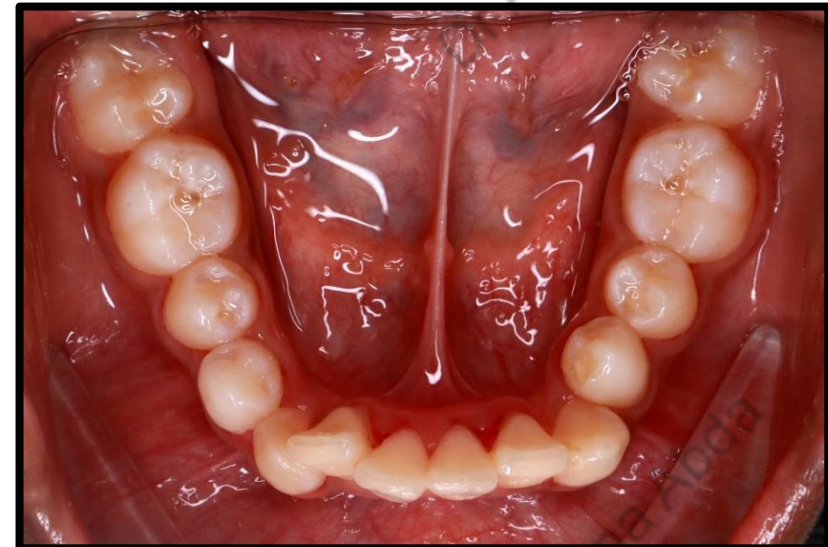
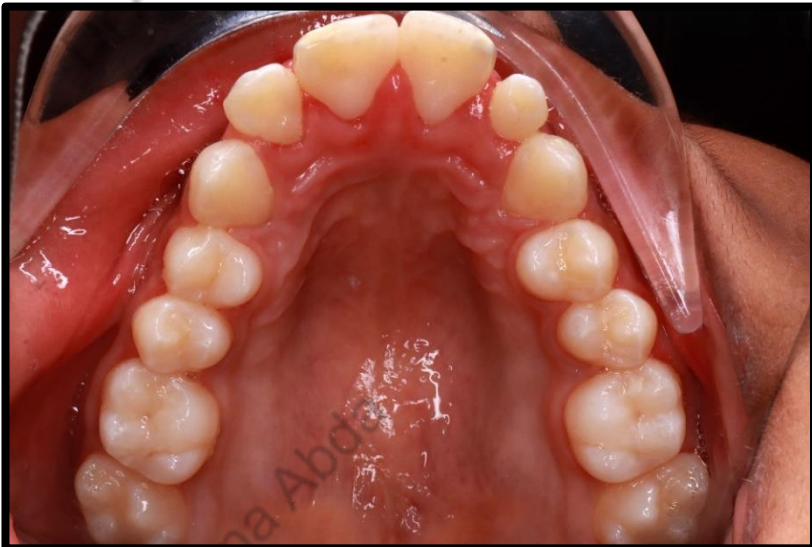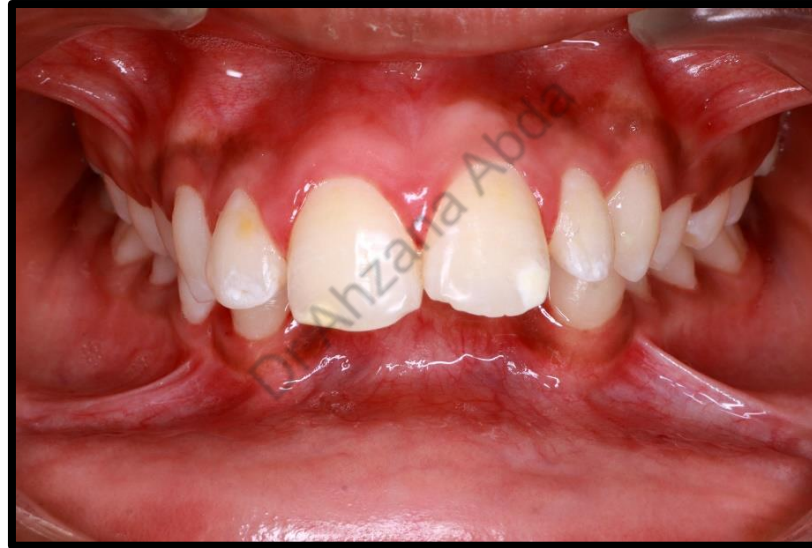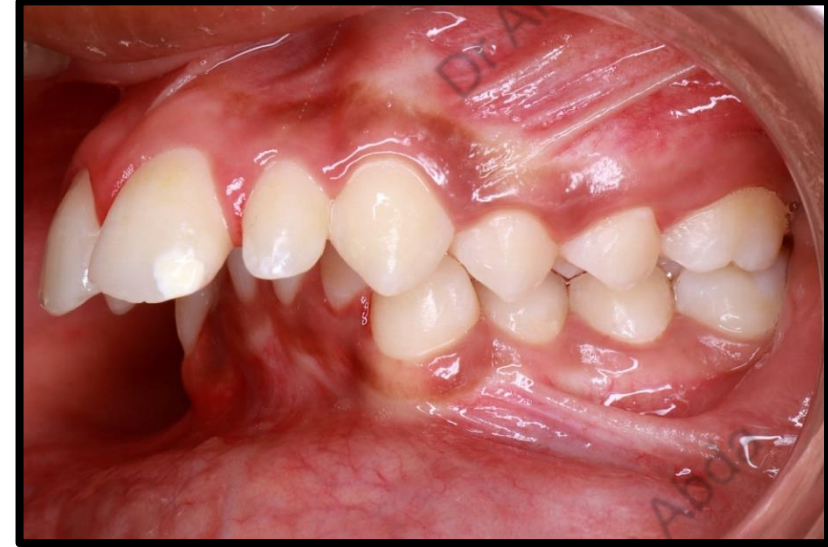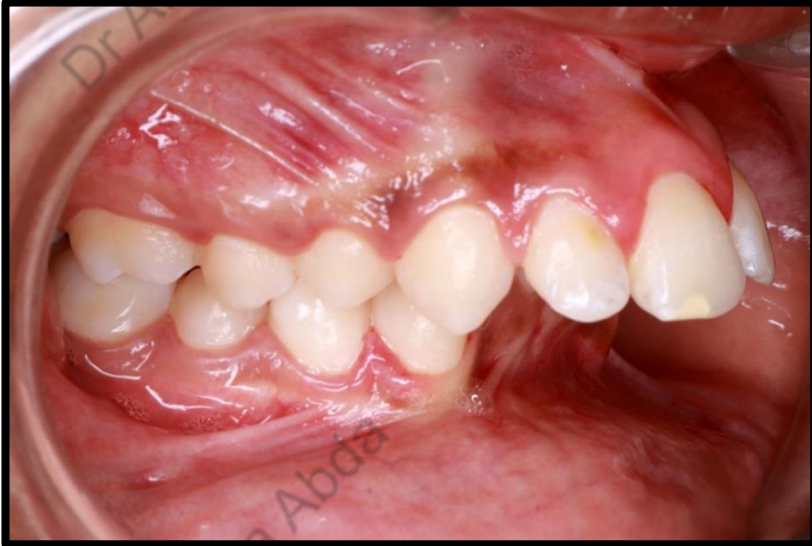**PROFILE**



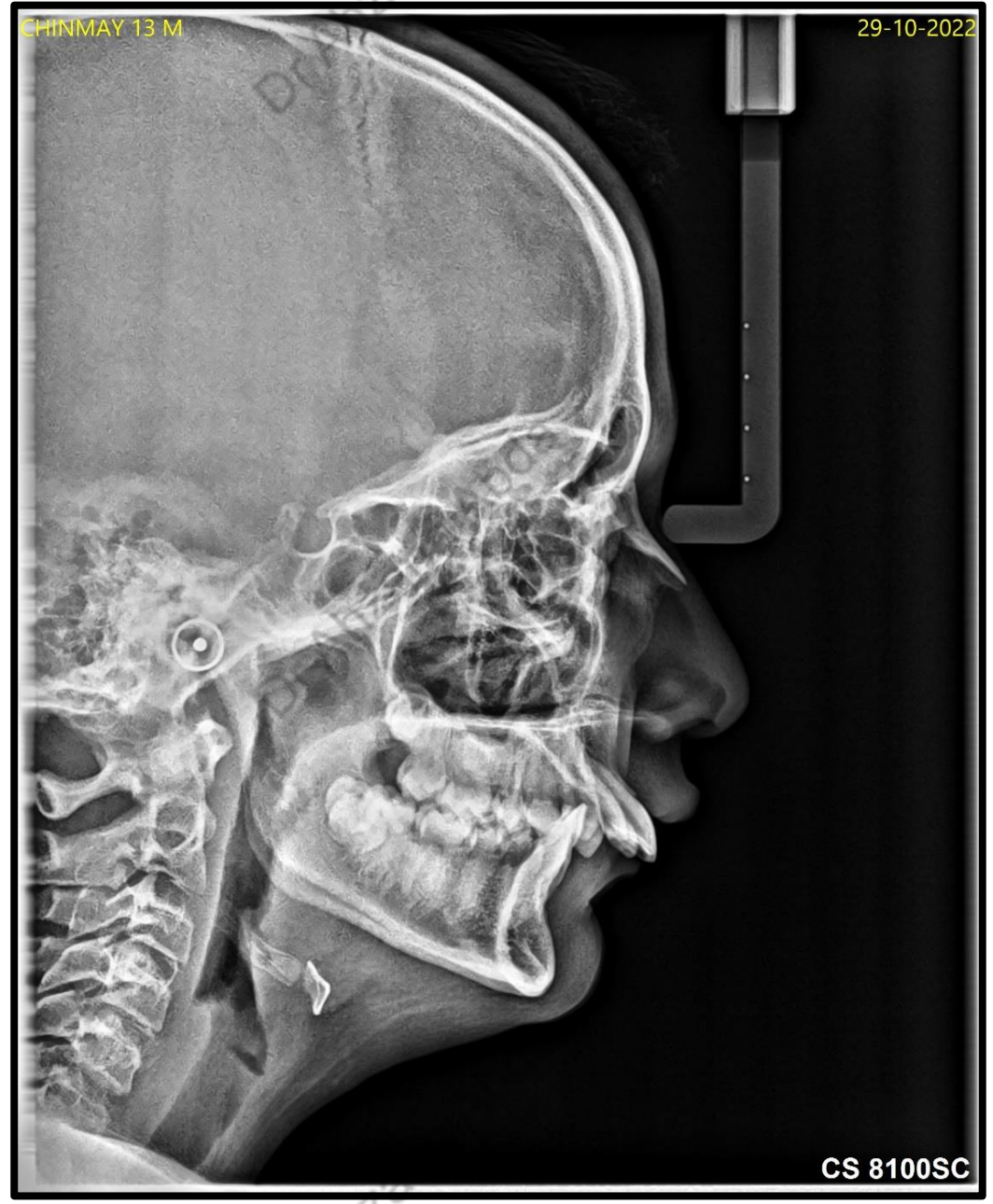
**VTO**



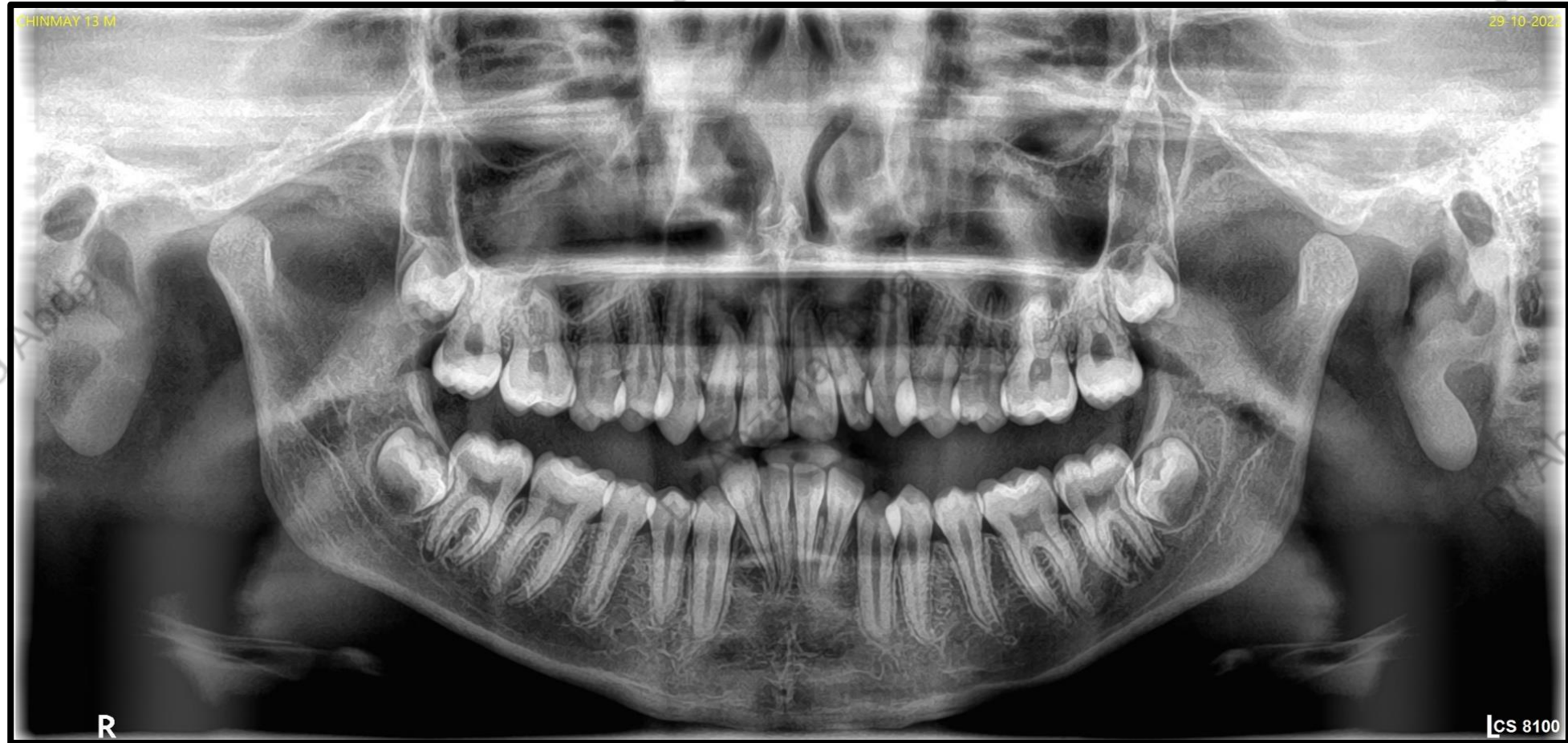**PRE-TREATMENT-INTRAL ORAL**



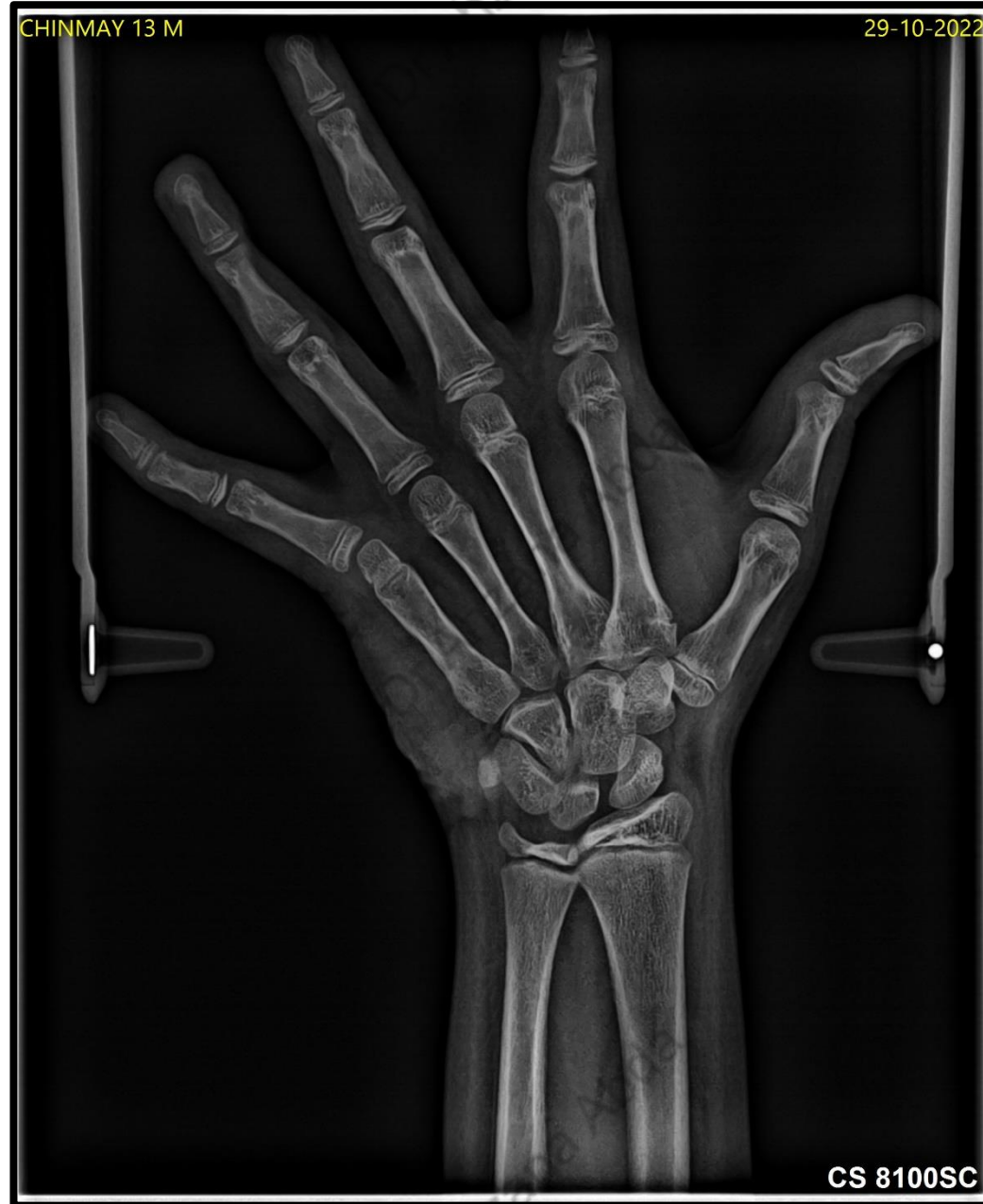# PRE-TREATMENT-LATERAL CEPHALOGRAM



# PRE-TREATMENT- OPG



# PRE TREATMENT-HAND WRIST RADIOGRAPH



## **DIAGNOSIS**

- Class II Skeletal Pattern
- Angle's Class II Malocclusion with bidental proclination
- Average to Horizontal Growth Pattern

## **TREATMENT PLAN**

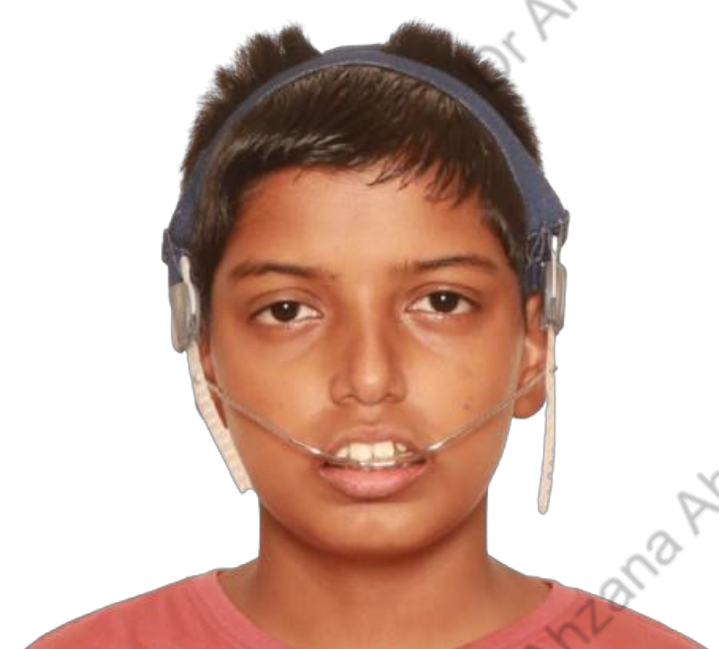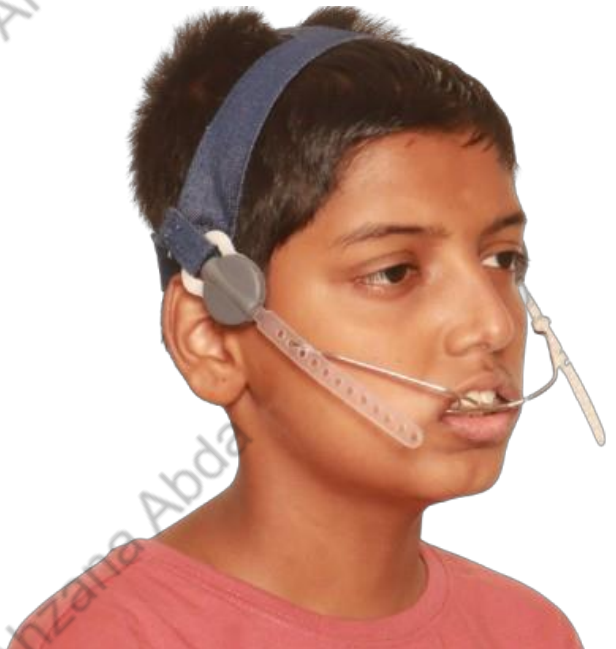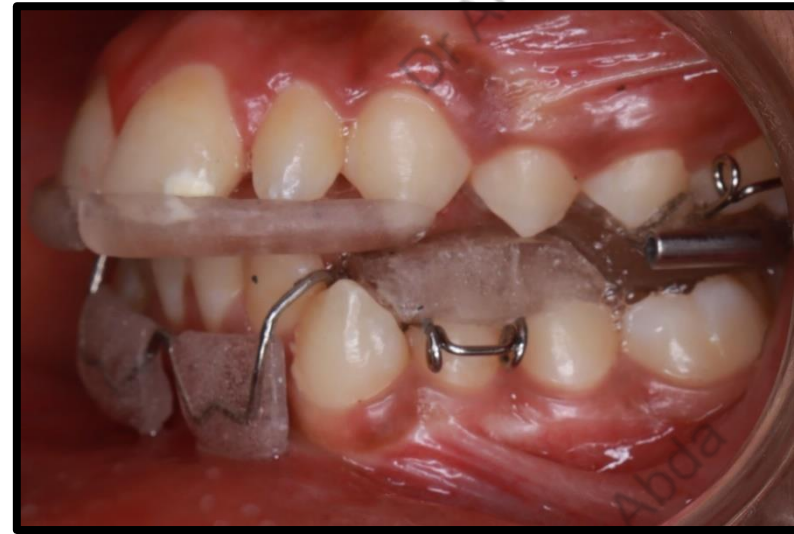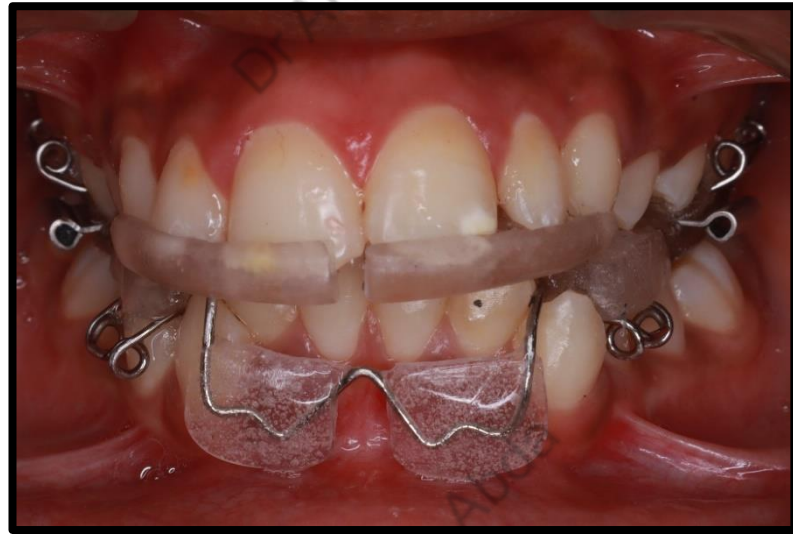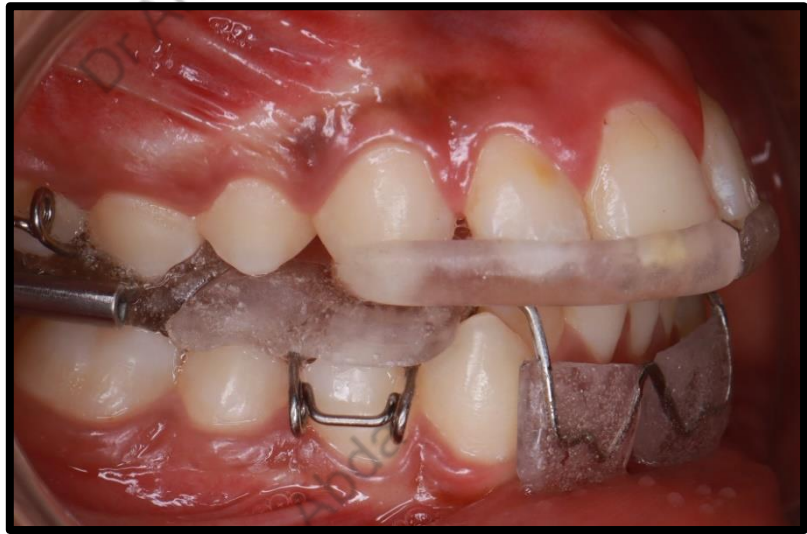- **PHASE I THERAPY**

Twin block appliance with headgear

- **PHASE II THERAPY**

Fixed mechanotherapy

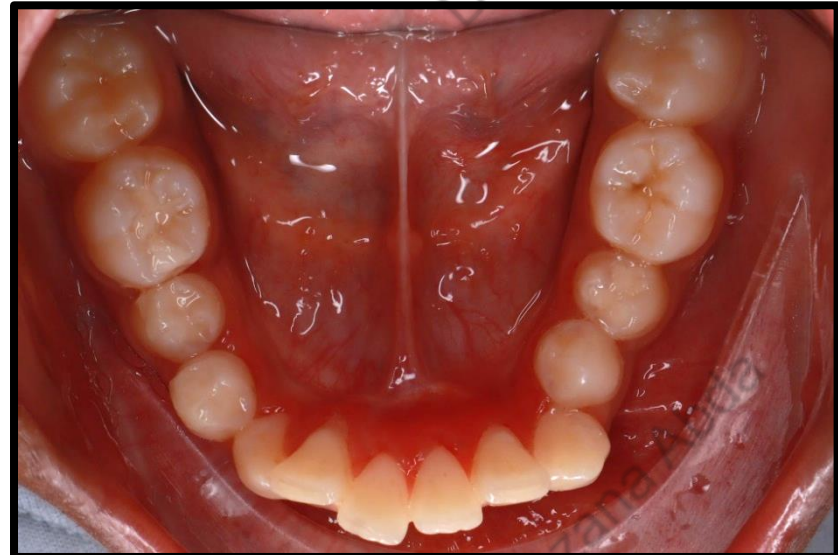
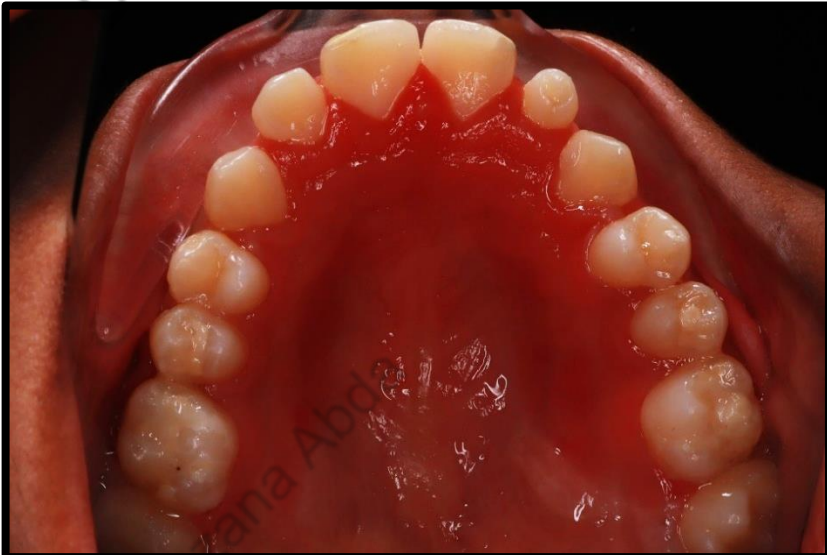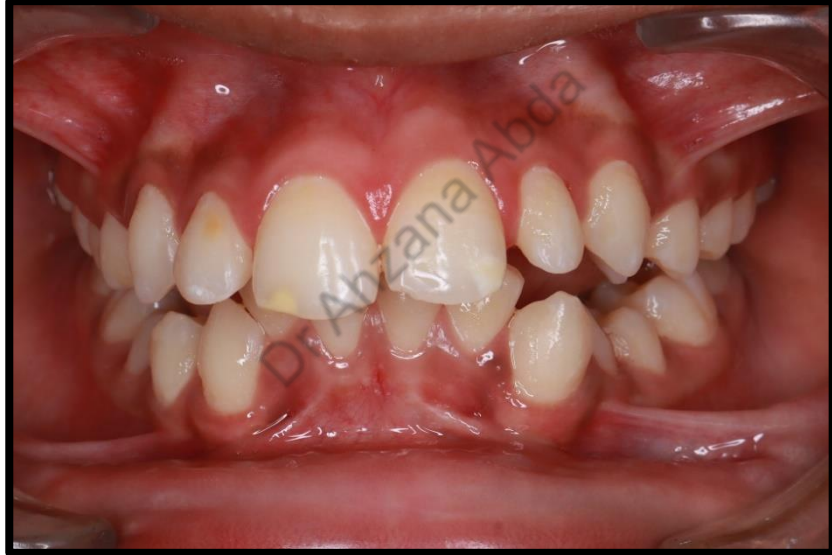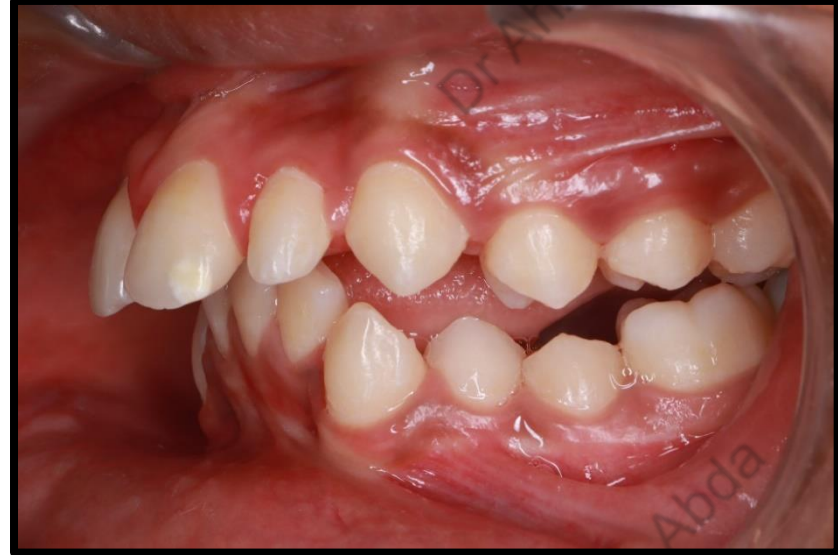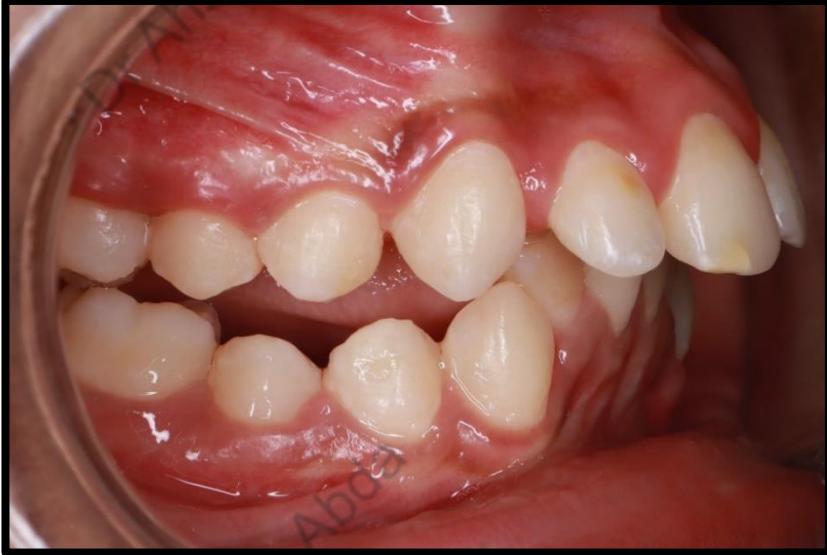# TWINBLOCK WITH HEADGEAR



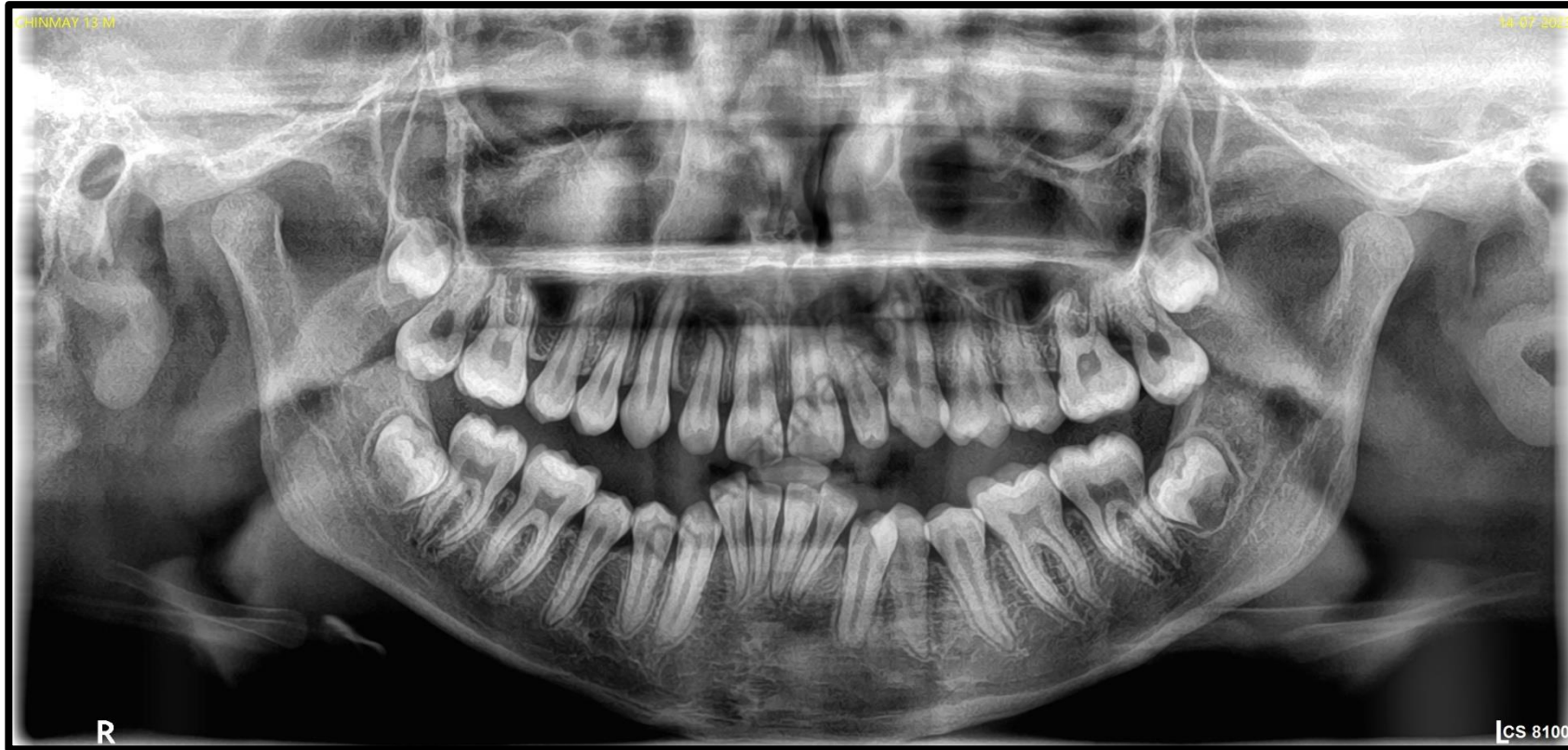**END OF PHASE1**



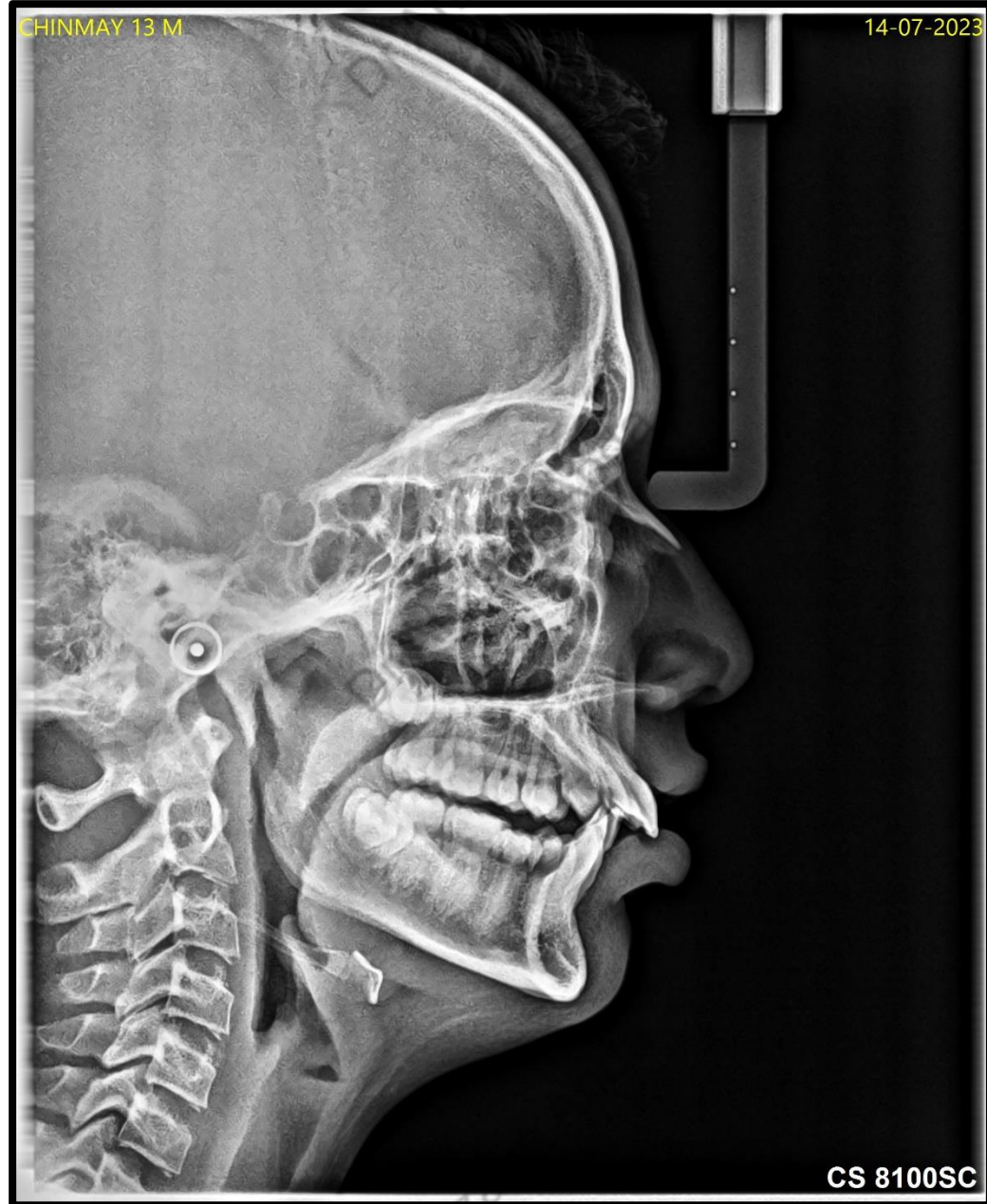
**END OF PHASE1**



# END OF PHASE I (OPG)



# END OF PHASE I (Lateral Cephalogram)



CS 8100SC

**PRE-PROFILE**



**AFTER PHASE I  
-PROFILE**

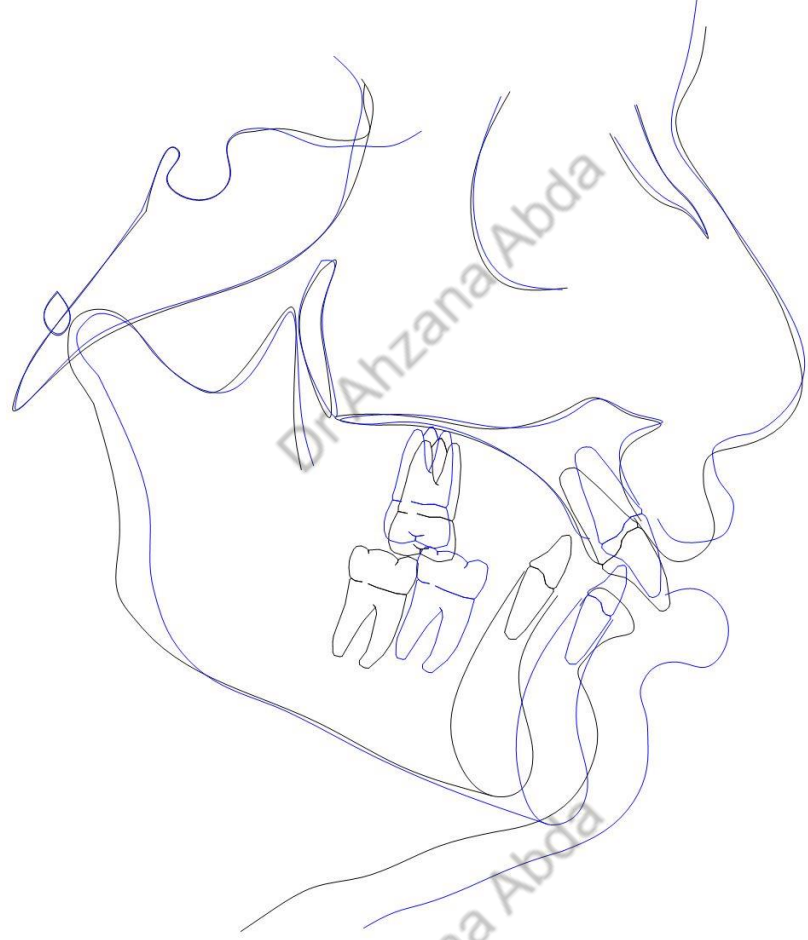


Dr Ahzana Abda

Dr Ahzana Abda

Dr Ahzana Abda

Dr Ahzana Abda



Dr Ahzana Abda

Dr Ahzana Abda

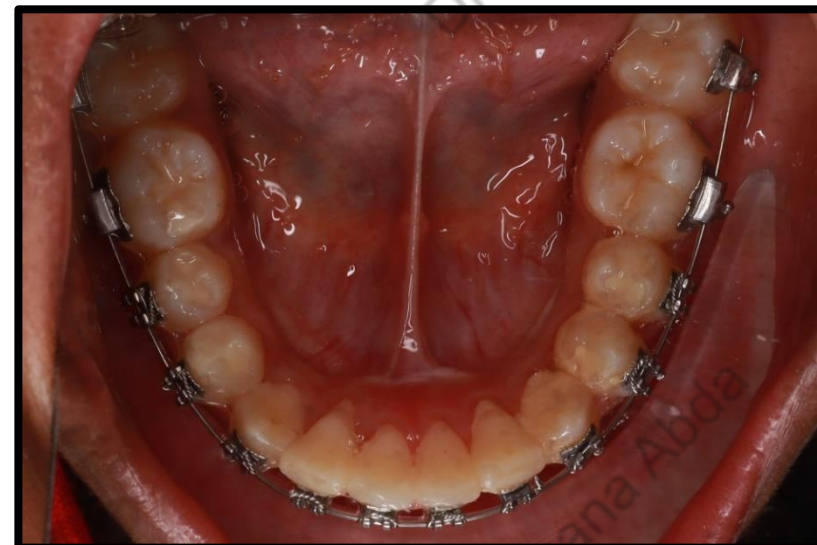
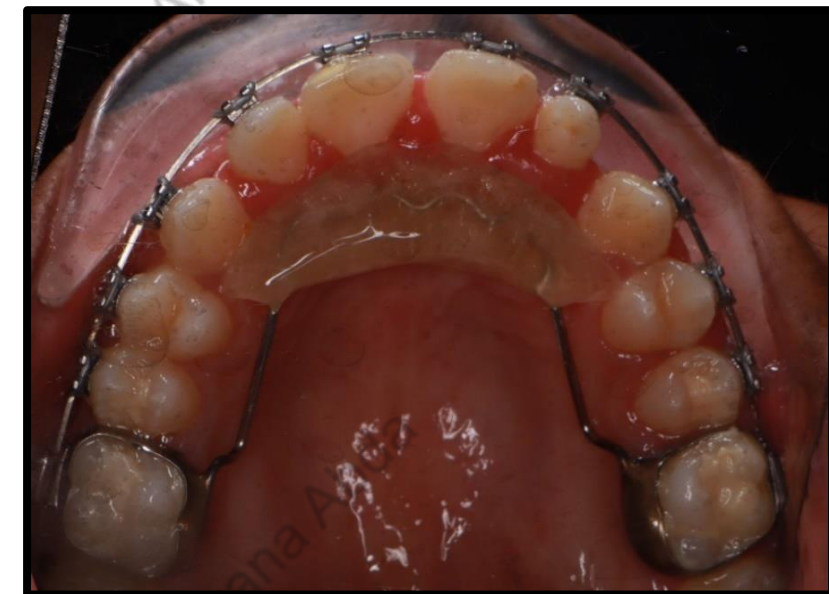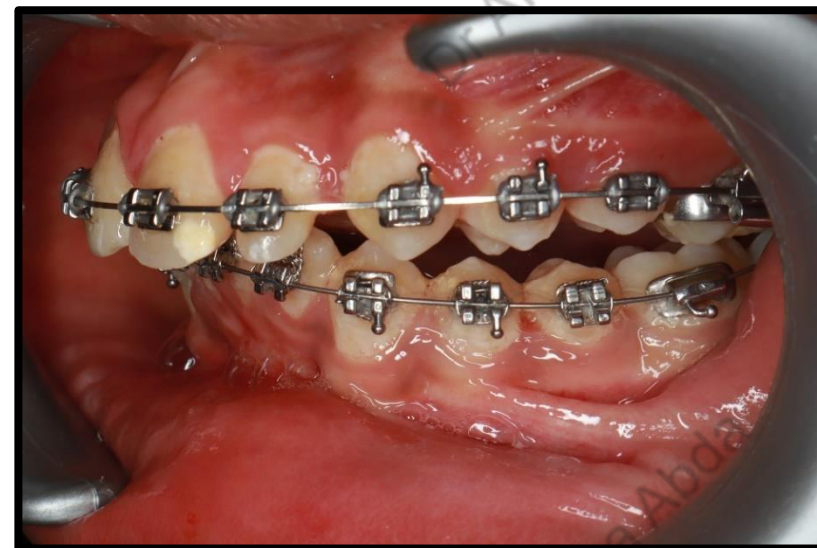
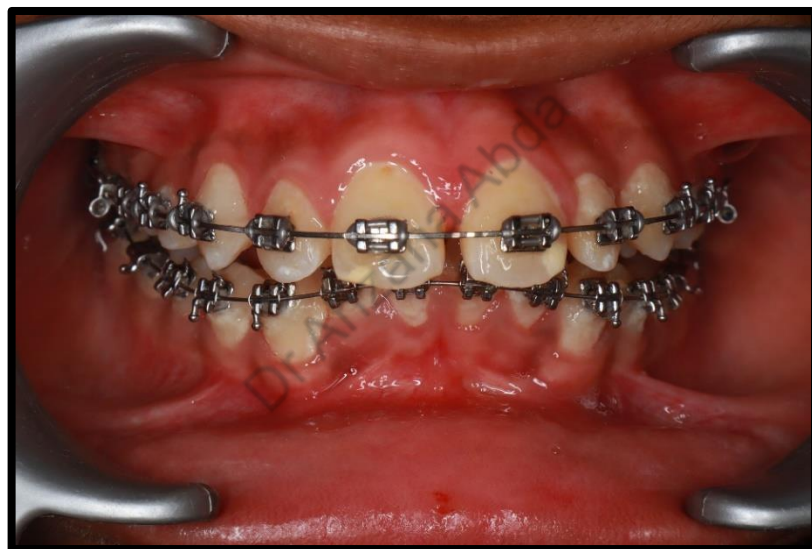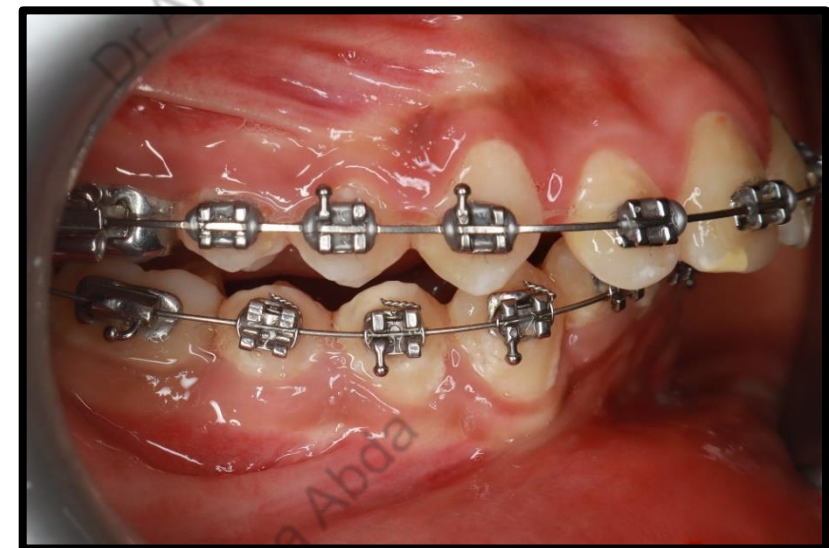
Dr Ahzana Abda

Dr Ahzana Abda

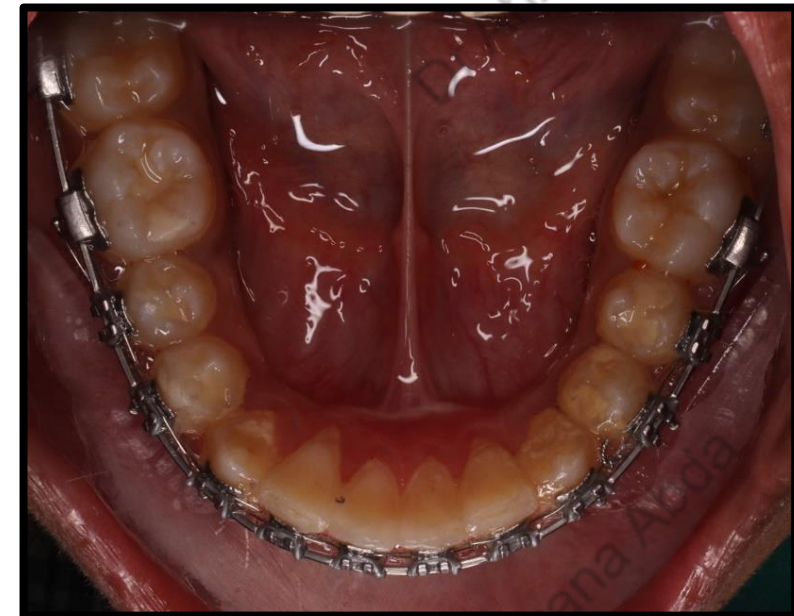
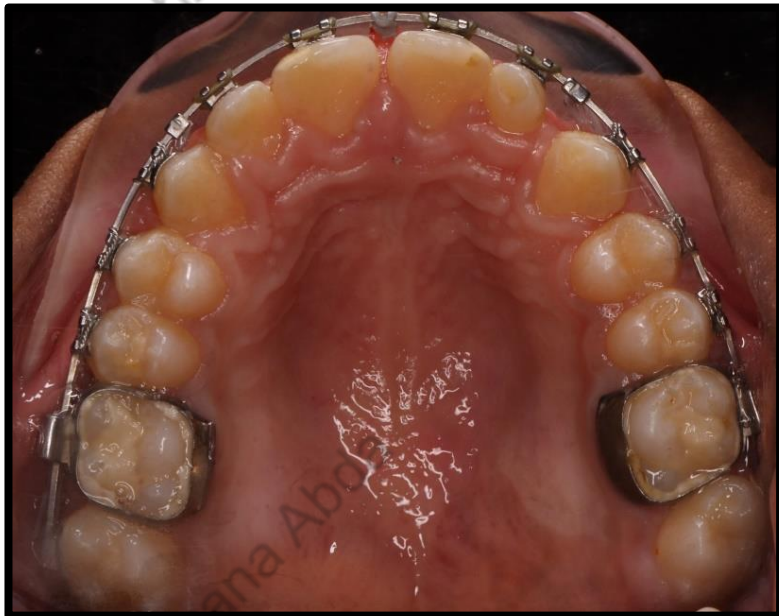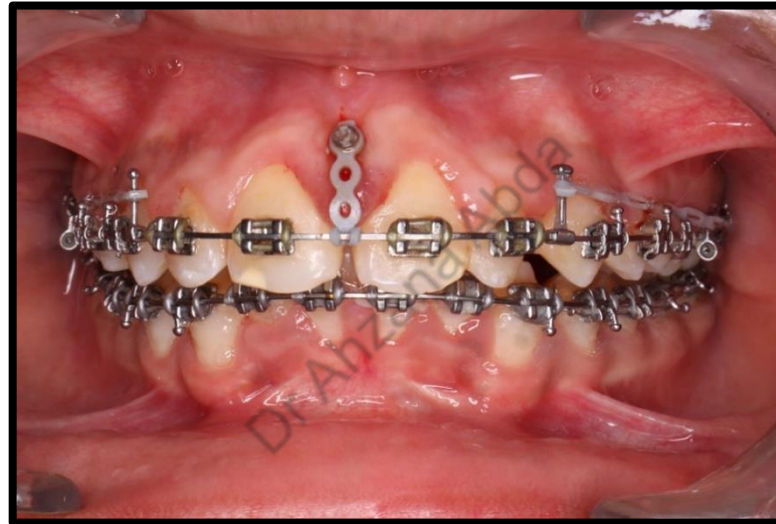
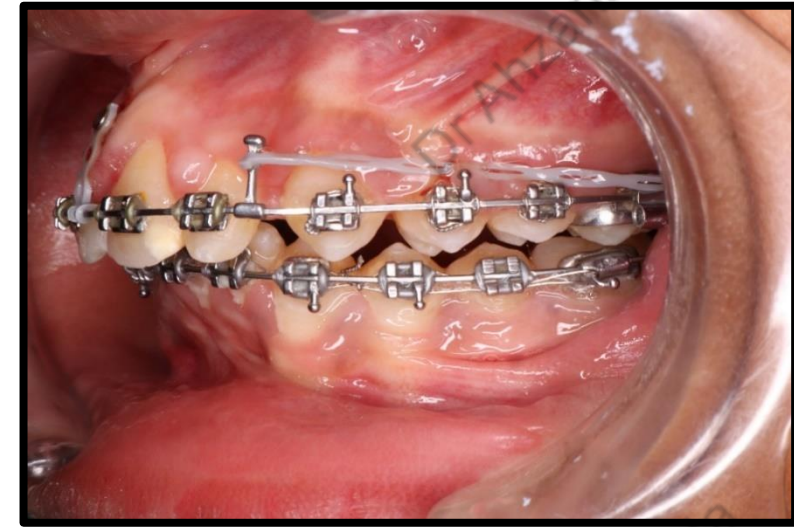
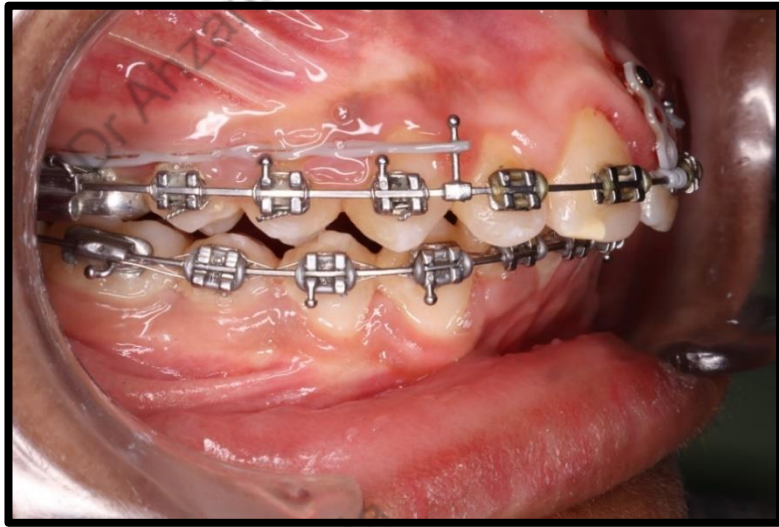
Dr Ahzana Abda

# PRE-END OF PHASE 1 COMPARISON





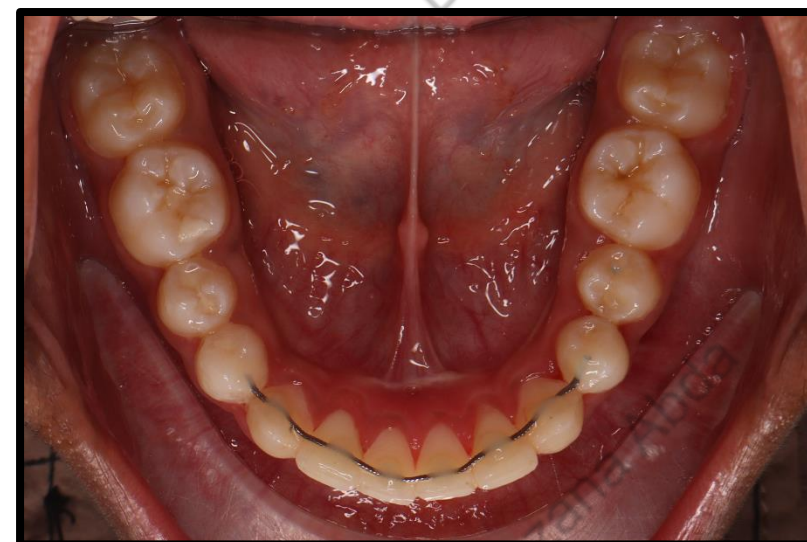
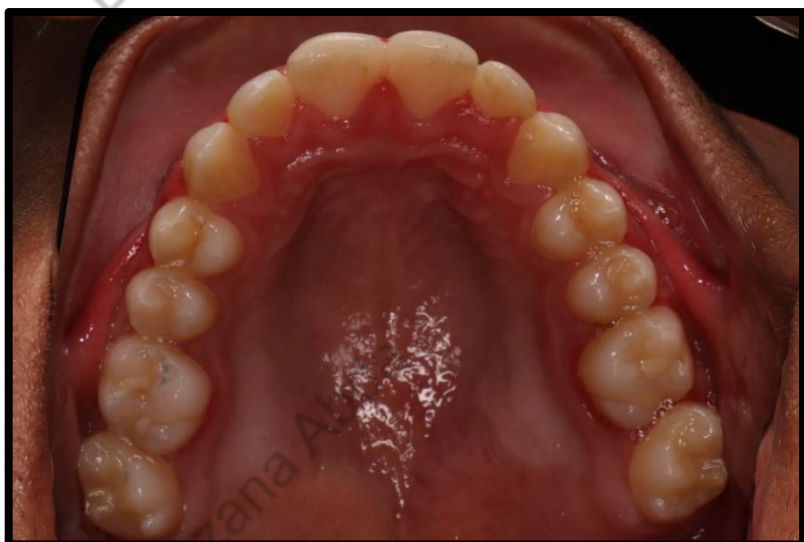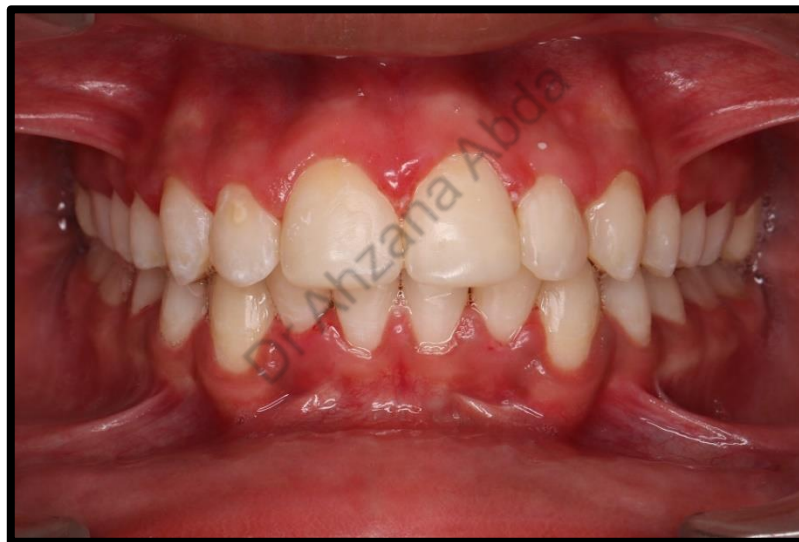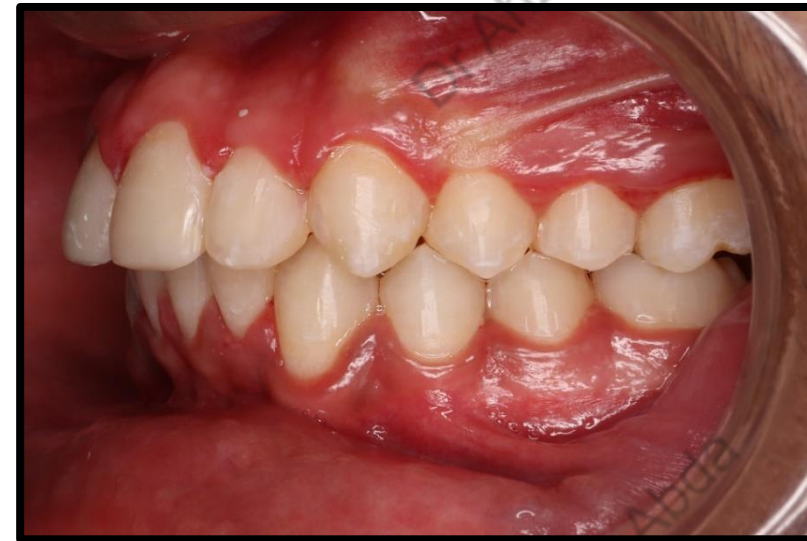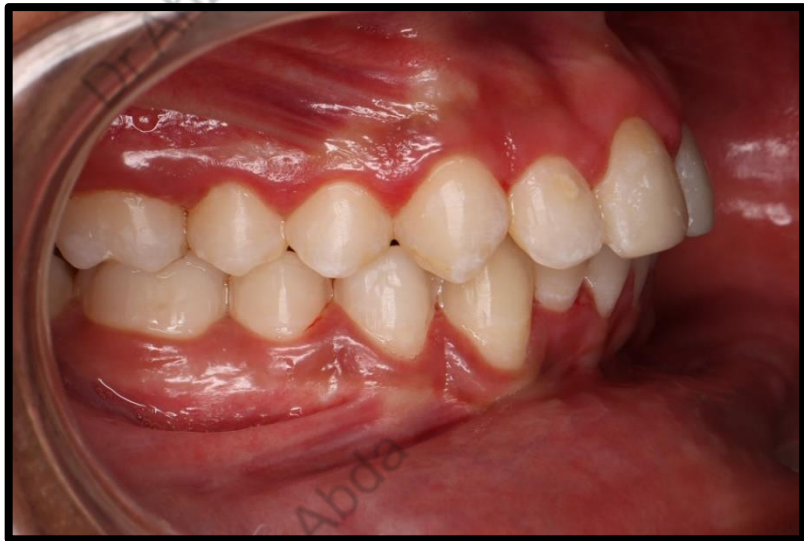# UPPER ANTERIOR INTRUSION USING TADS



**POST-EXTRA ORAL**



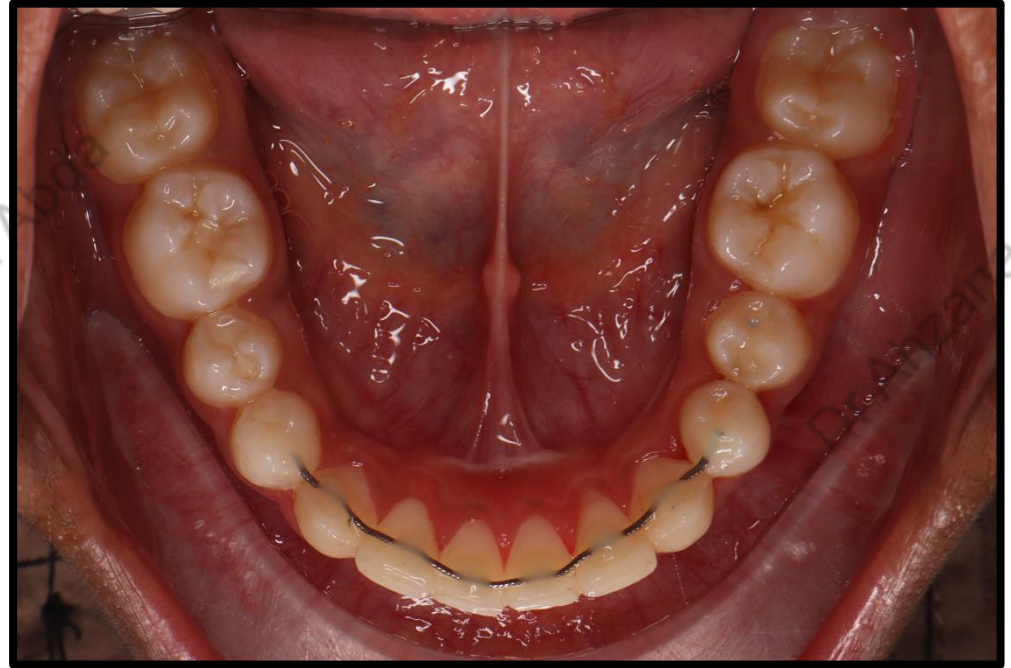
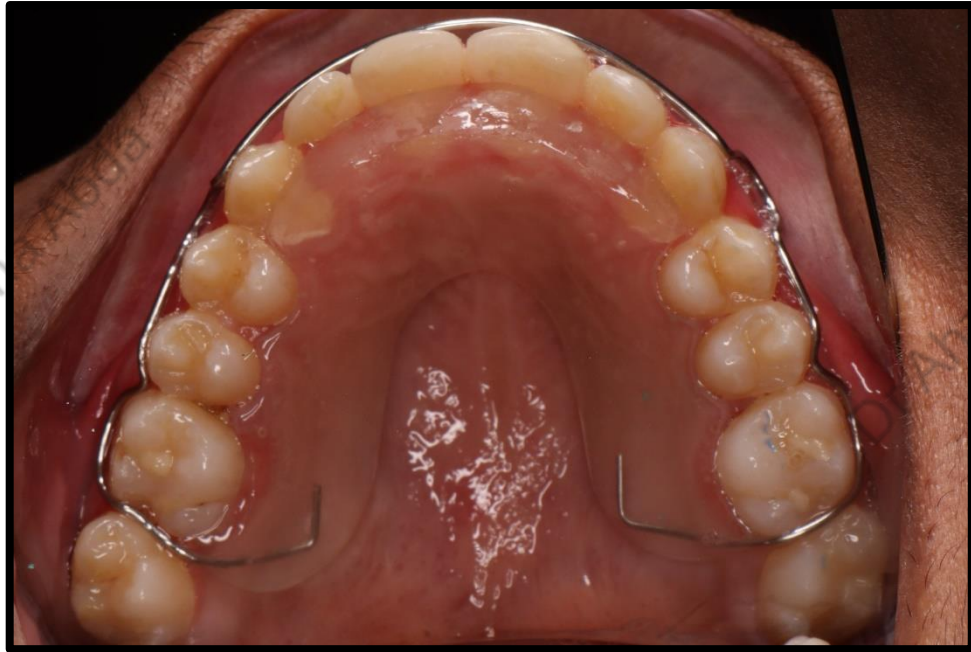**POST-INTRA ORAL**



Dr Ahzana A

Dr Ahzana A

Dr Ahzana A



Dr Ahzana A

Lana A

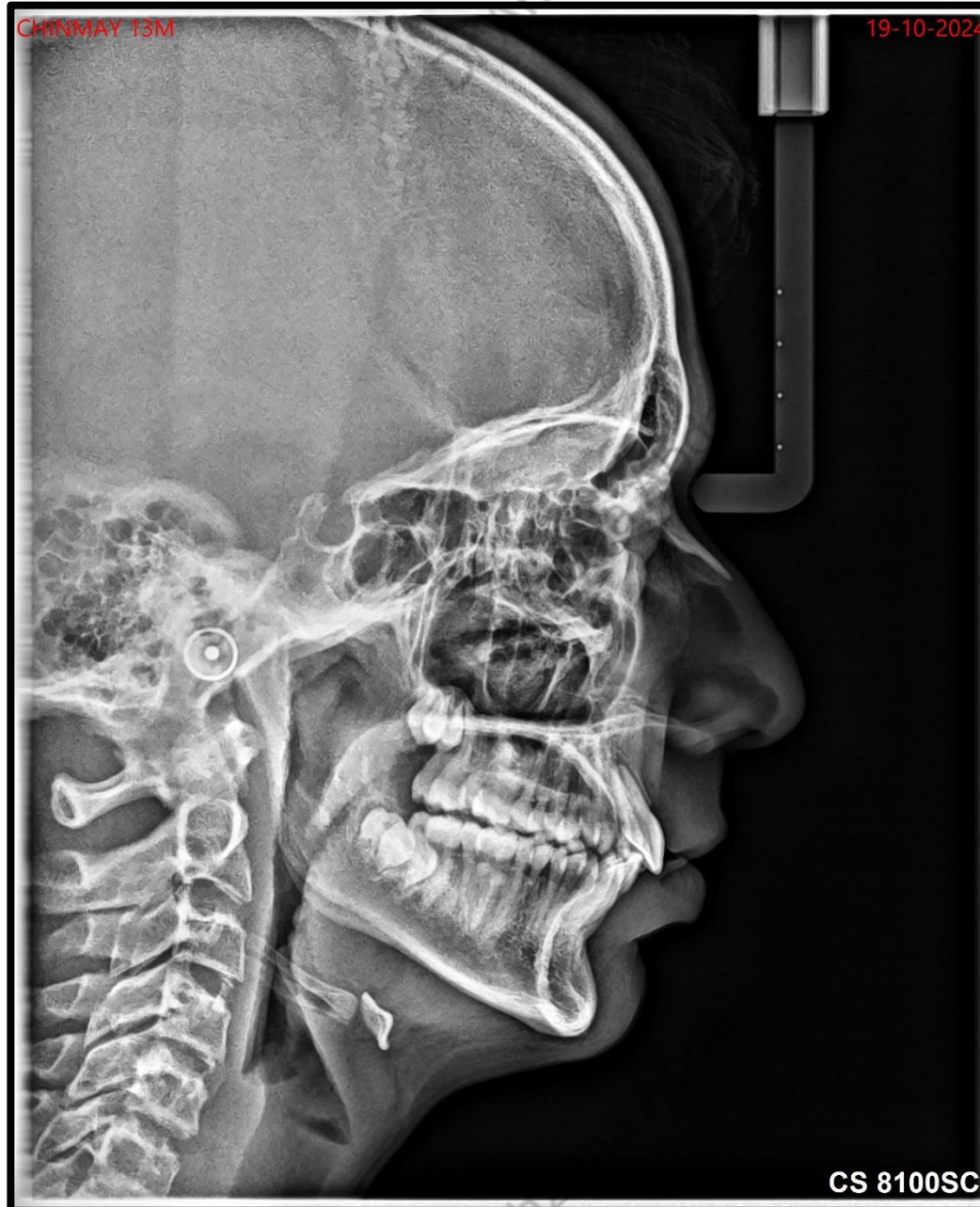Abda

Ahzana Abda

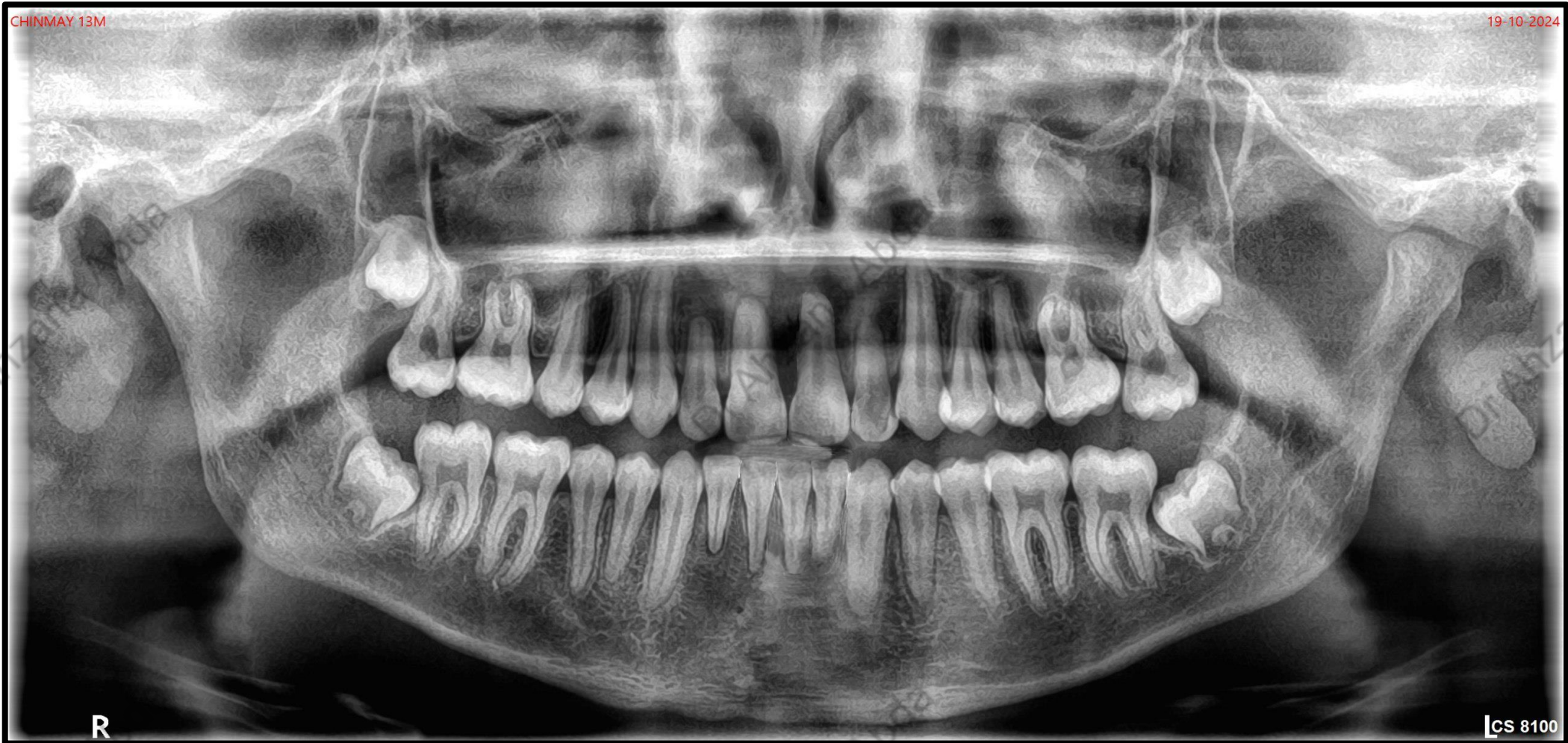Ahzana Abda

Ahzana Abda

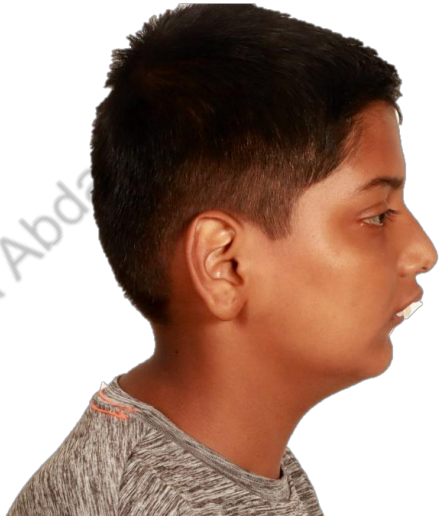# POST TREATMENT (Lateral Cephalogram)



**POST TREATMENT  
(OPG)**



**PRE**

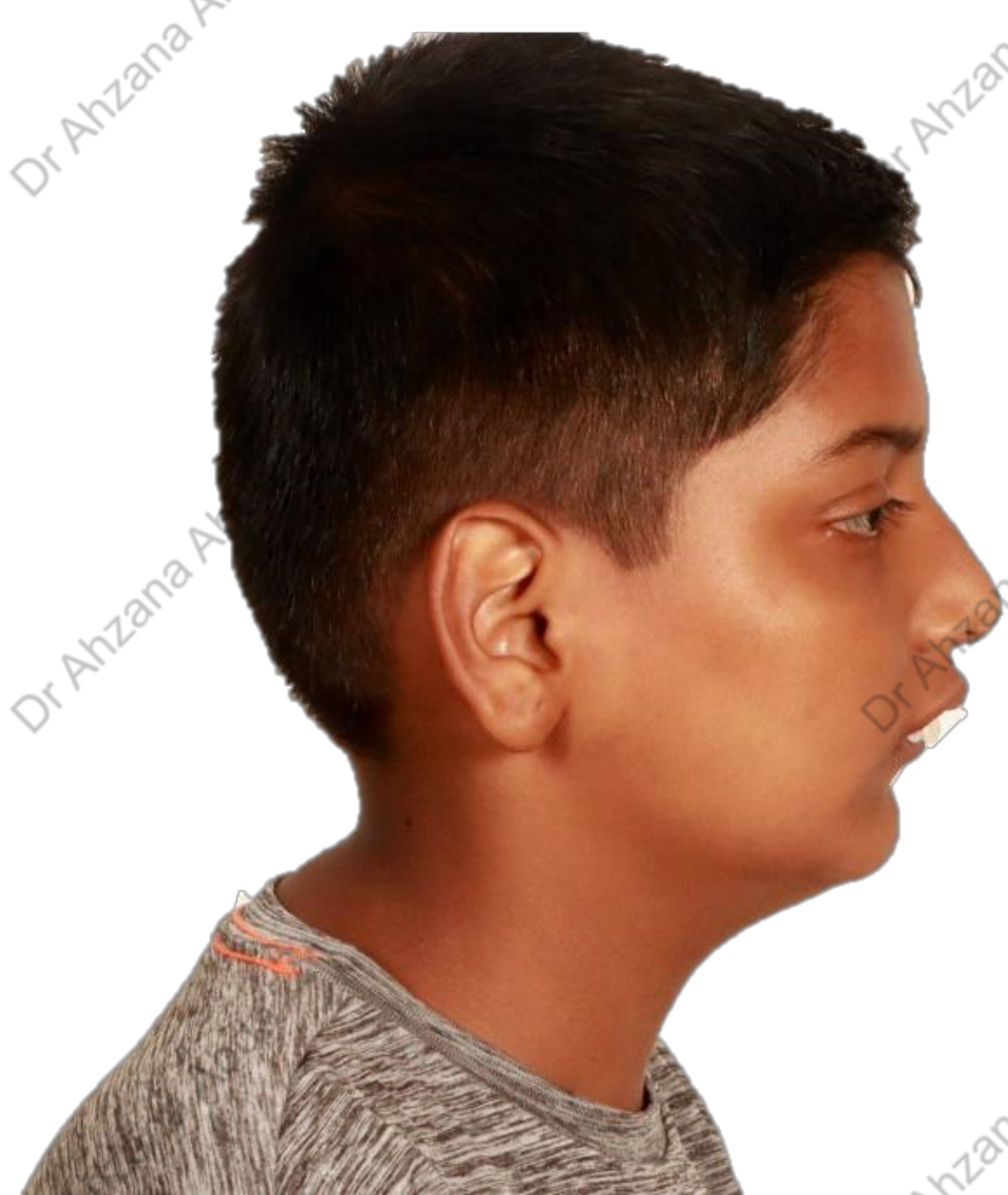

**AFTER PHASE I**

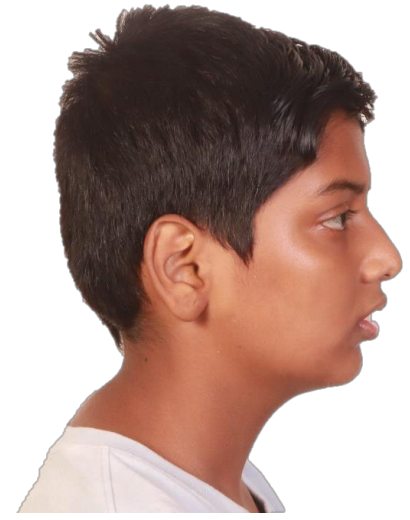

**POST**





**AFTER PHASE I**



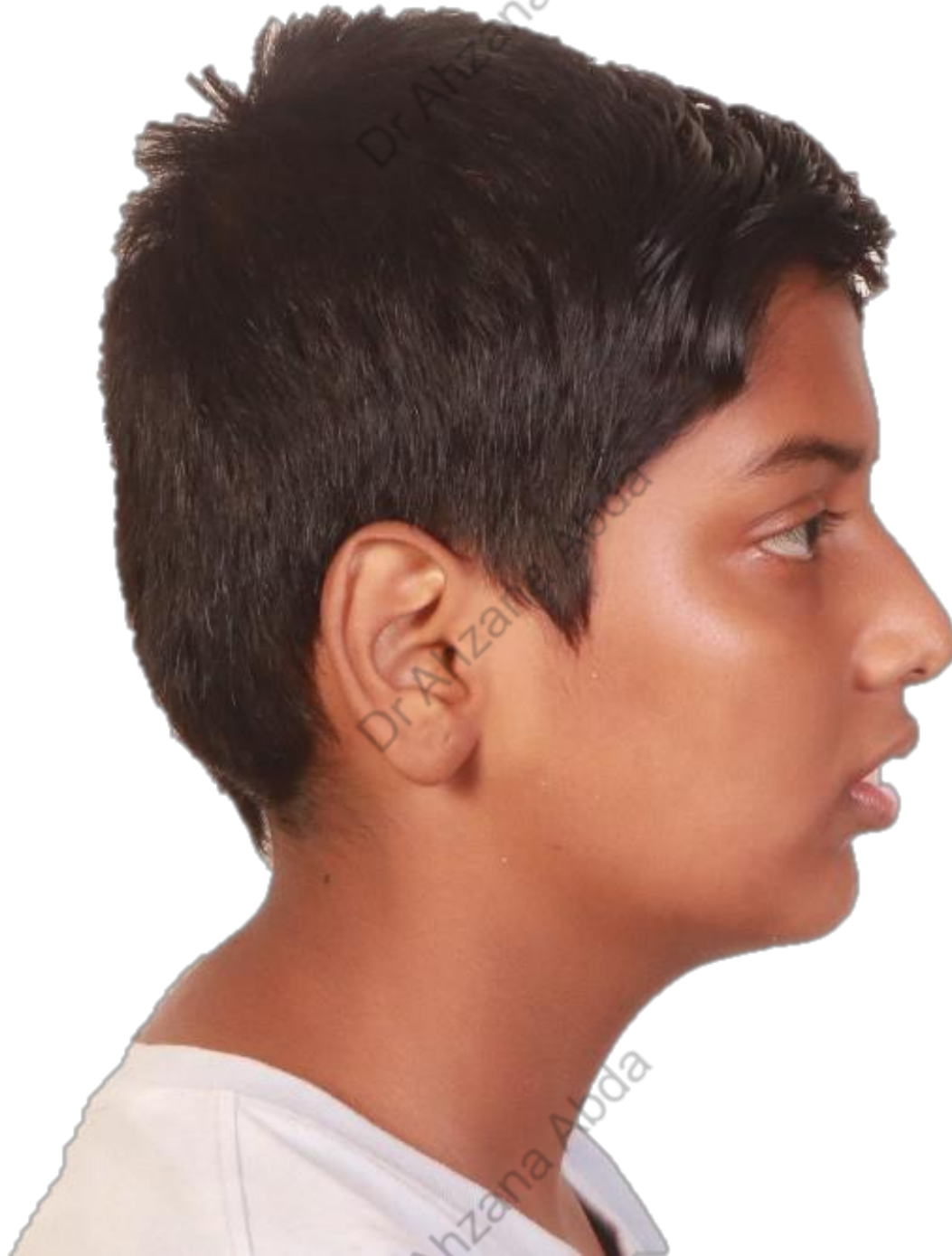**POST**



**PRE**



**POST**



**PRE**



**AFTER PHASE I**



**PRE**



**AFTER PHASE I**



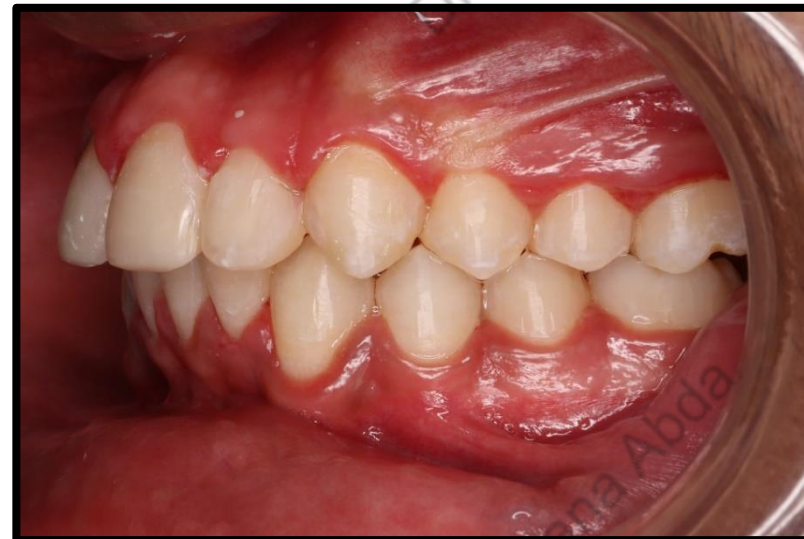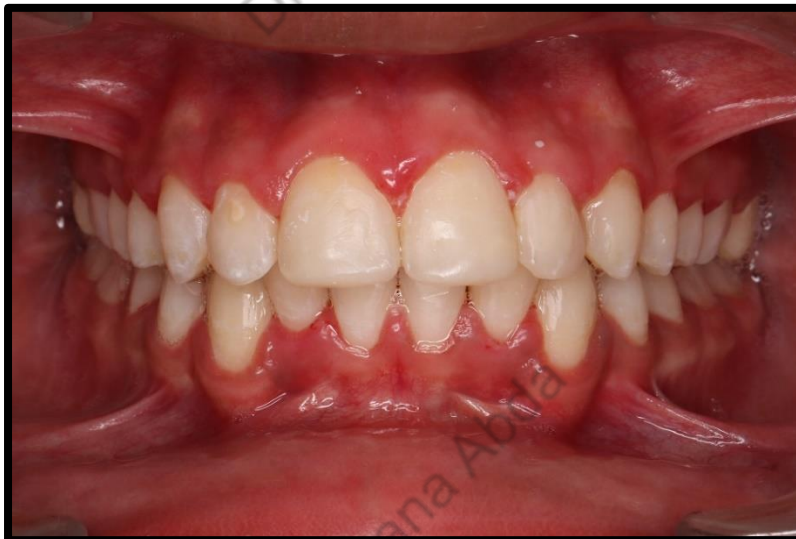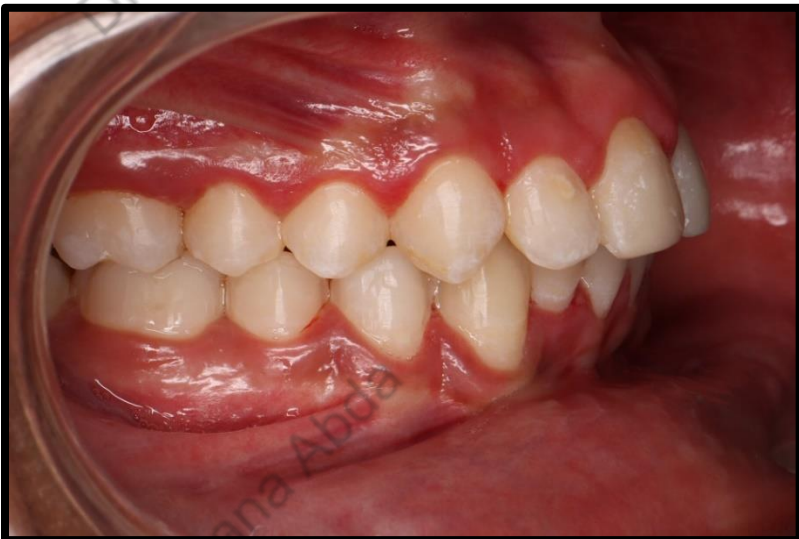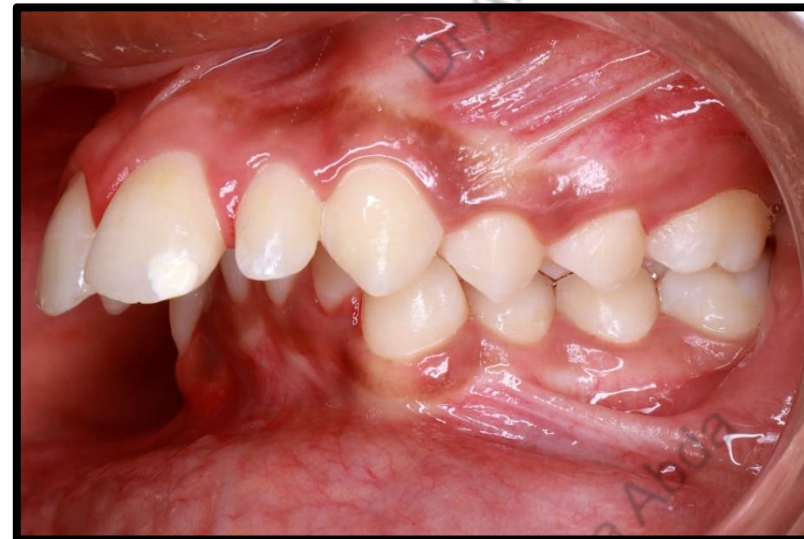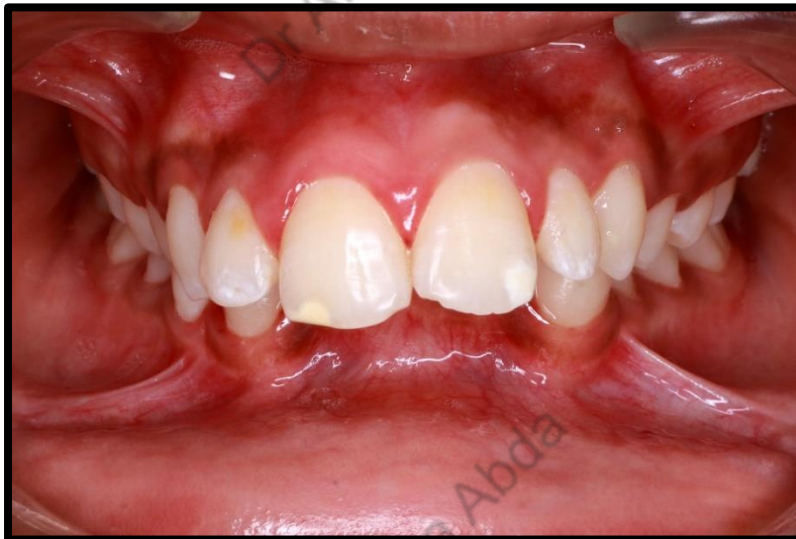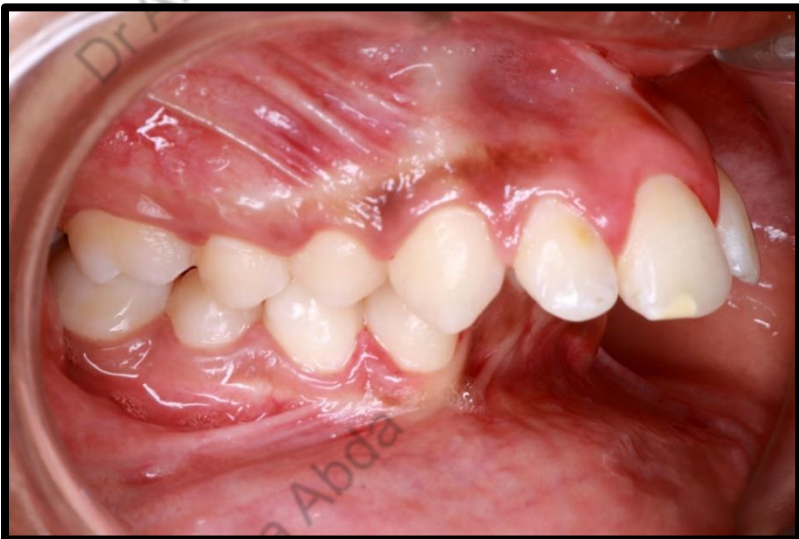**POST**



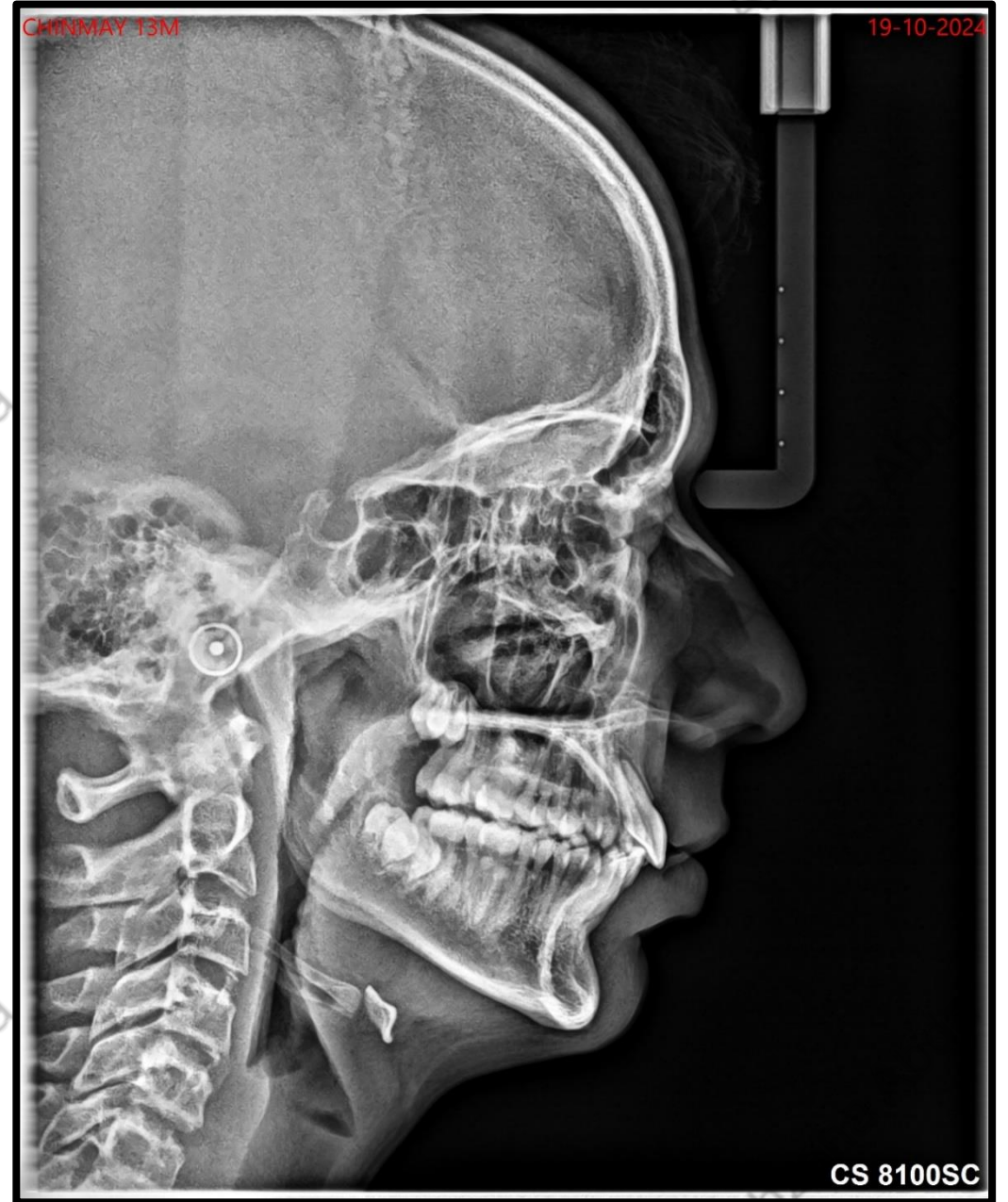
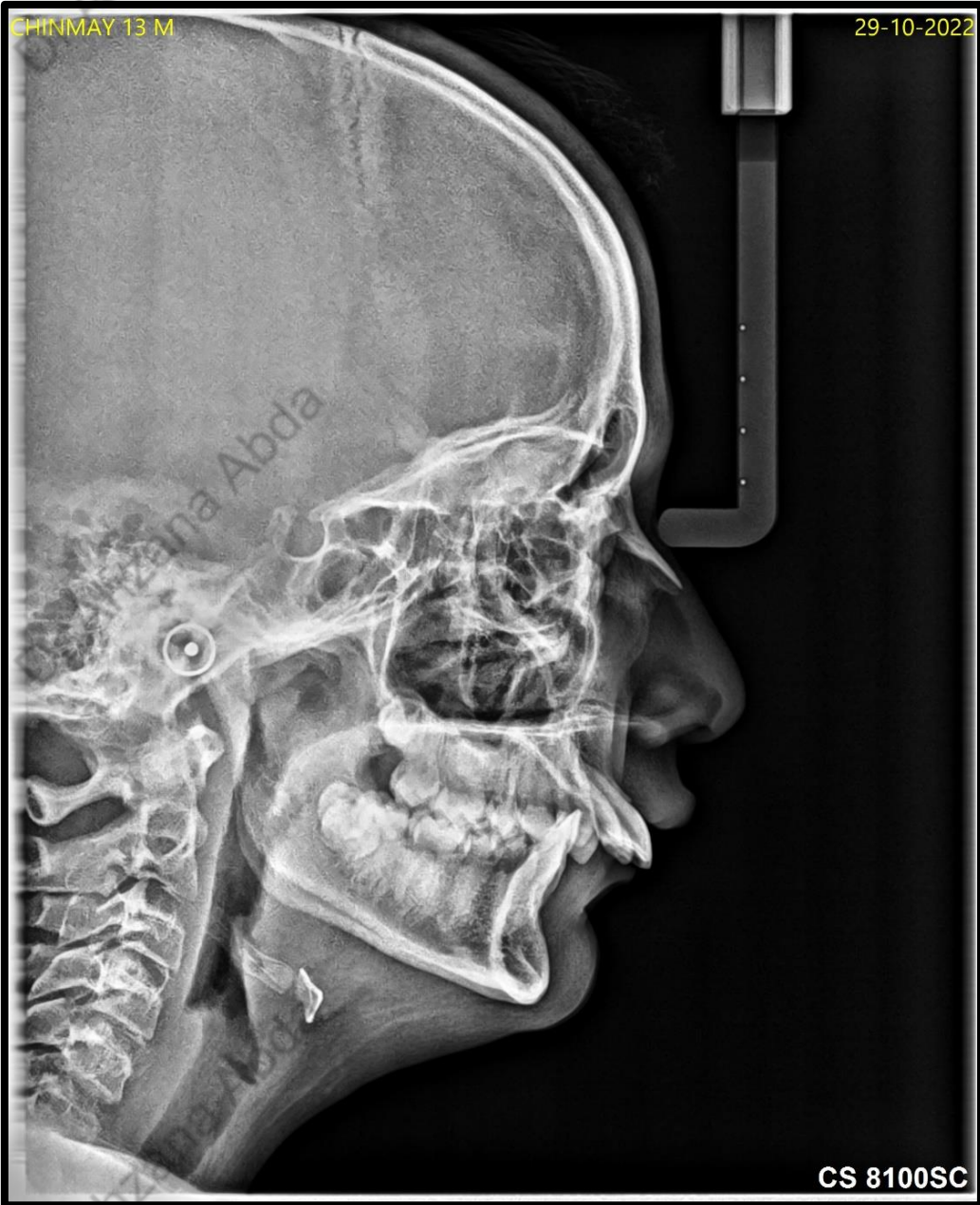# PRE AND POST COMPARISON



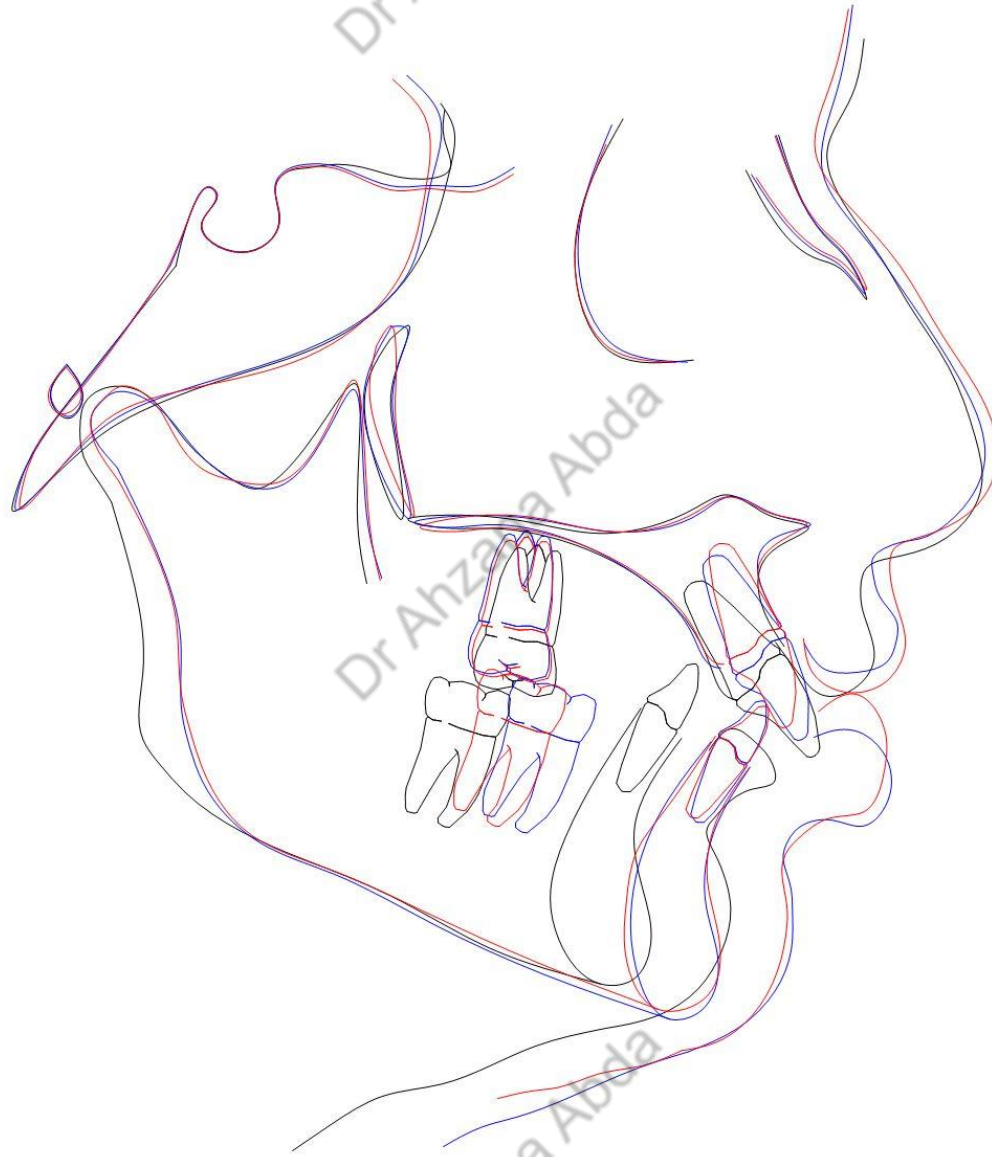
# PRE AND POST COMPARISON



# PRE-POST TREATMENT (Lateral Cephalogram)



# SUPERIMPOSITION



# CASE V

**Abhiram 21/M**

**PRE-TREATMENT-EXTRA ORAL**



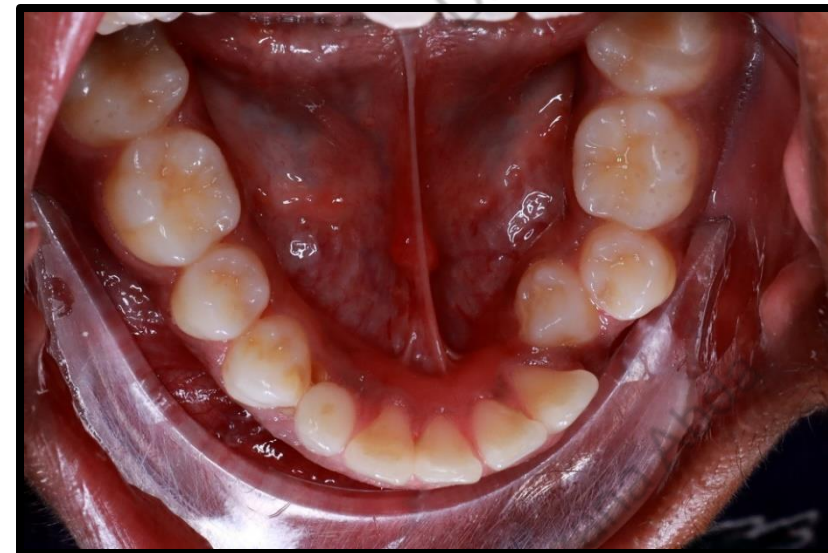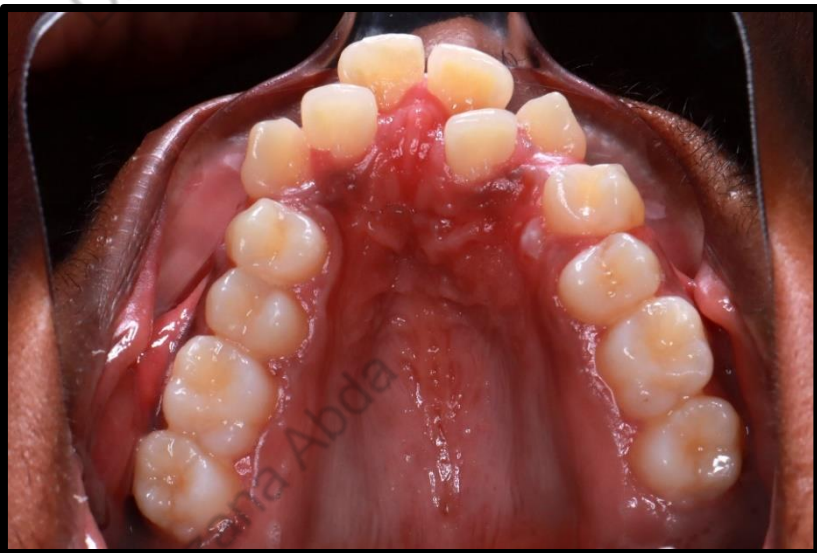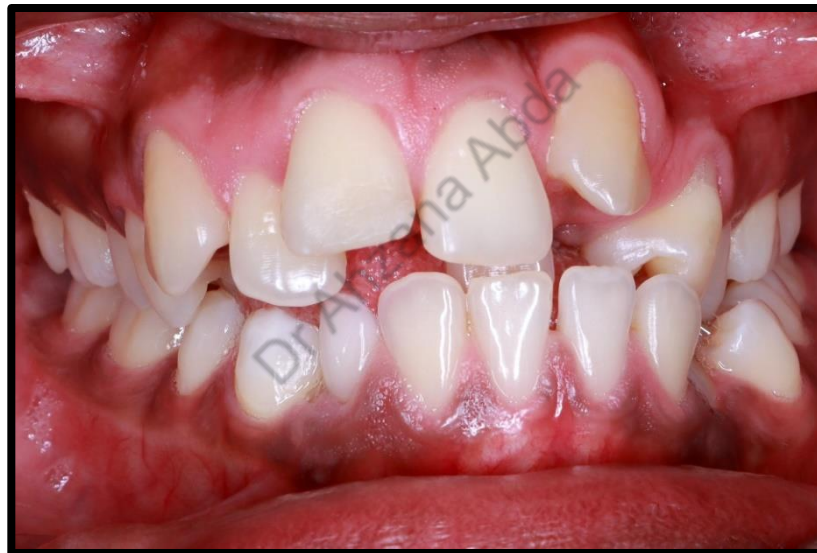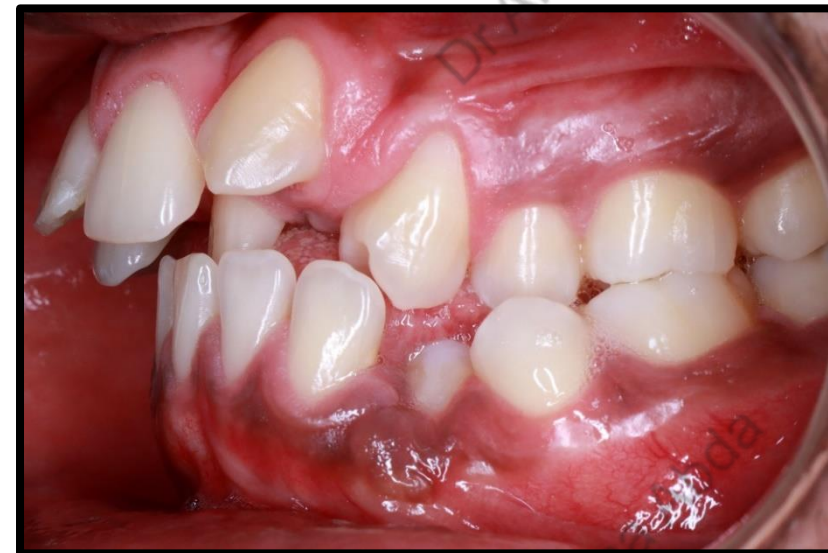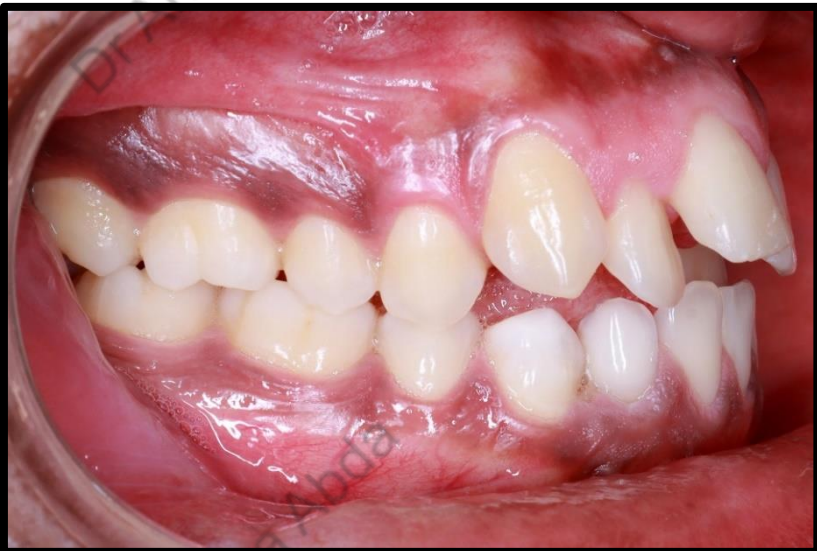# PRE TREATMENT EXTRAORAL PROFILE



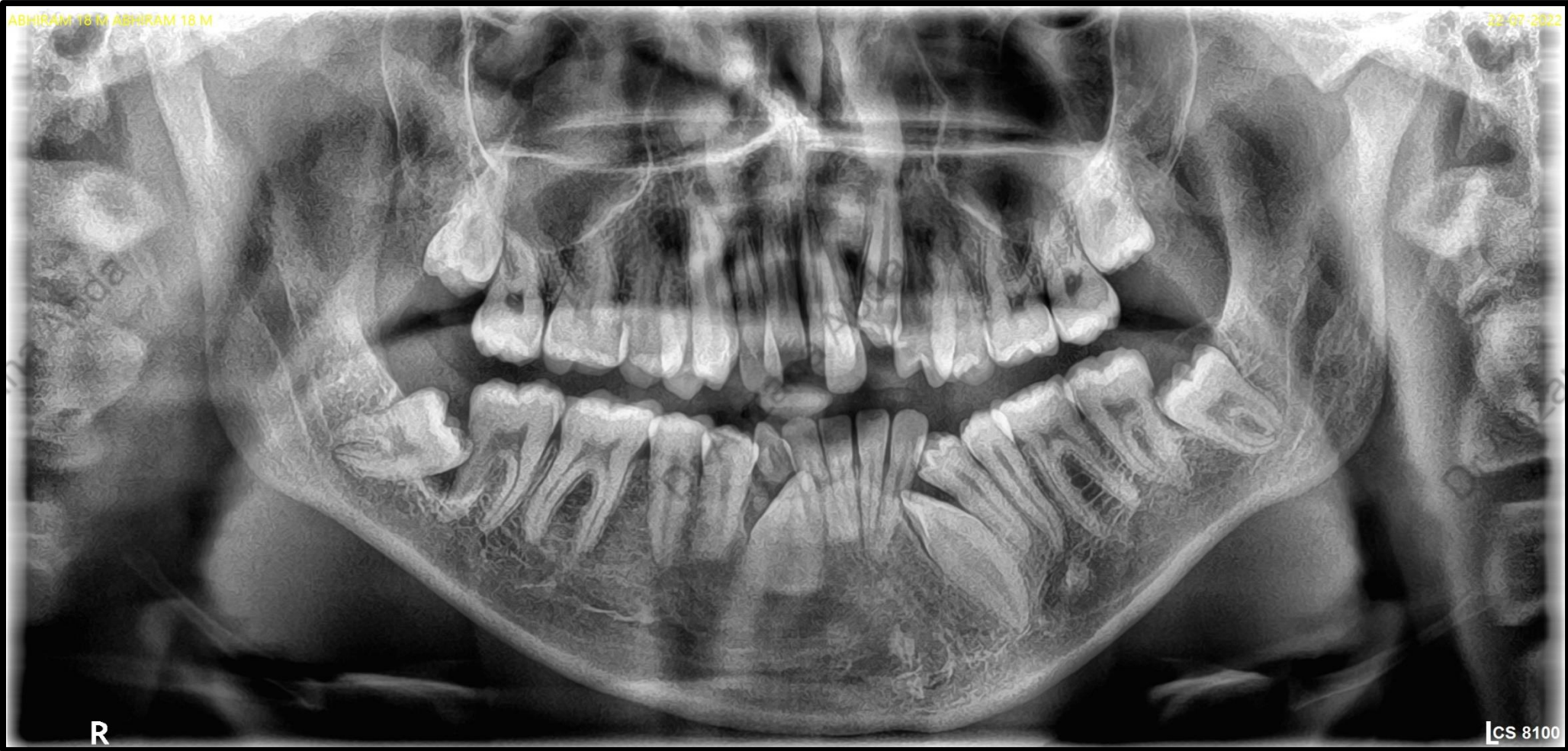# FACIAL MIDLINE DISCREPANCY



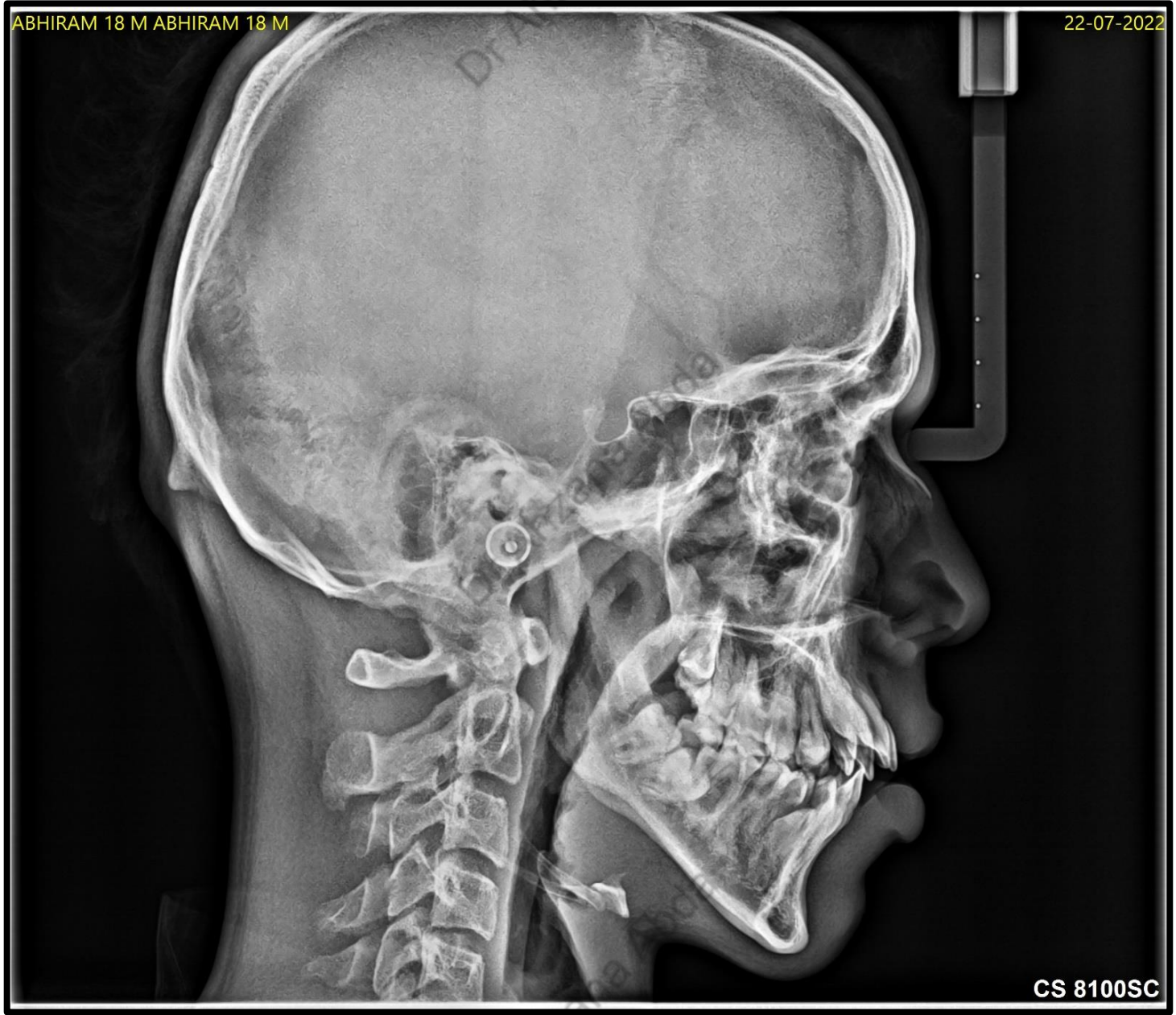
# PRE-TREATMENT-INTRA ORAL



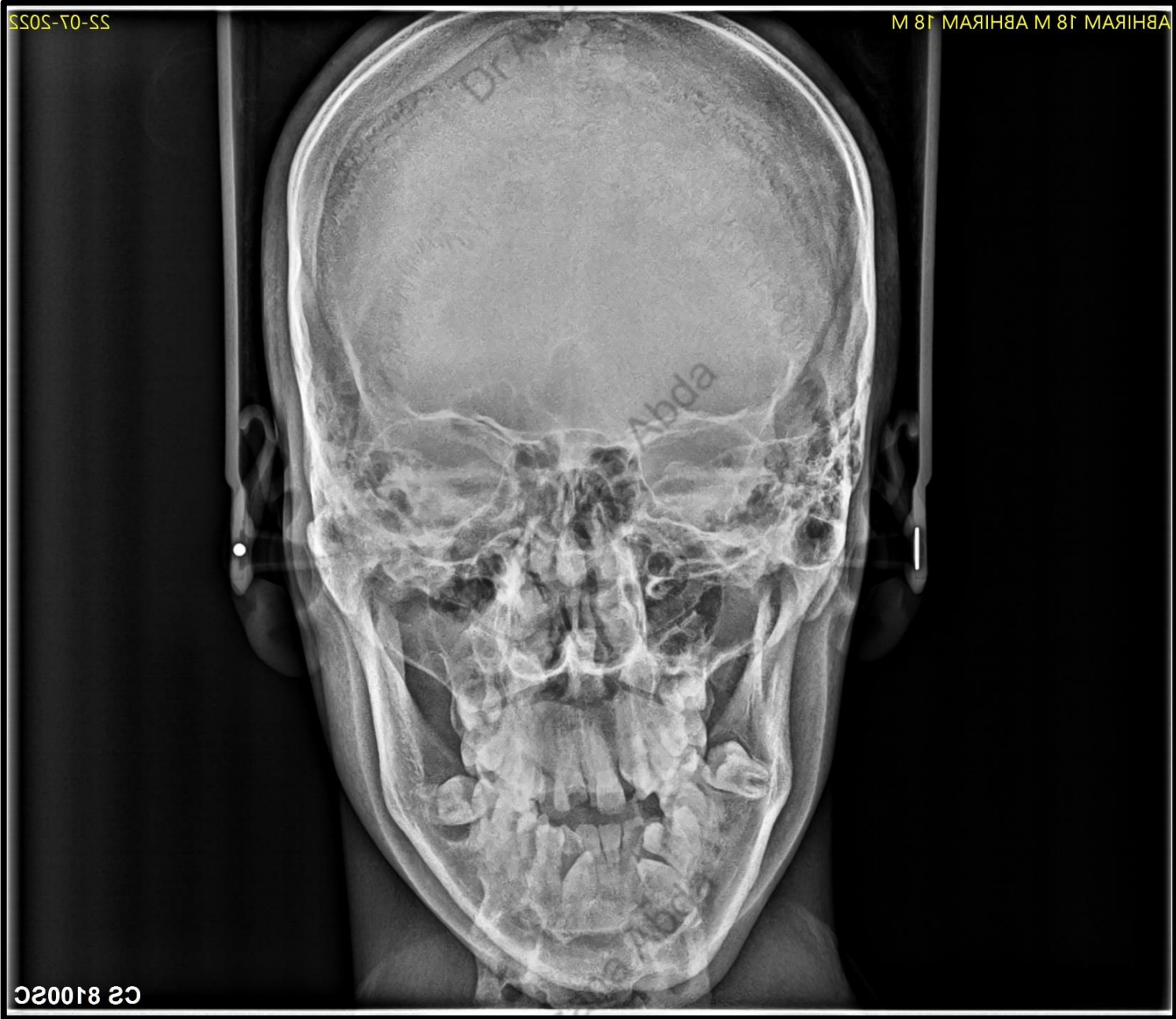**PRE-TREATMENT-OPG**



# PRE-TREATMENT-LATERAL CEPHALOGRAM



# PRE-TREATMENT-PA CEPHALOGRAM





# YENEPOYA MEDICAL COLLEGE HOSPITAL

(A CONSTITUENT COLLEGE OF YENEPOYA DEENDEBOORE UNIVERSITY), Recognized under Sec 3 (U) of the UGC Act, 1956  
Accredited by NAAC with 'A+' Grade

University Road, Deralakatte, Mangalore - 575 018. Ph. : 2204668 / 68 / 73, Fax : 0824 - 2202153



College No. 4019499  
Number 31, 322 - April 18, 2018

NAME	Mr. ABHIRAM N V	STUDY DATE	18-07-2023 14:55:12
AGE	019Yrs	HOSPITAL NO	4881610
SEX	M	MODALITY	NM
REPORTED ON	18-07-2023 16:56:43	REFERRED BY	Dept. of Orthodontics, YMCH

## REGIONAL SKELETAL SCINTIGRAPHY WITH SPECT REPORT

### TECHNIQUE:

Regional Skeletal Scintigraphy was performed after i.v. administration of 20 mCi of <sup>99m</sup>Tc-MDP. Anterior, Right lateral and Left lateral images of the head and neck region were acquired 3 hours after tracer administration. In addition, SPECT imaging of the head and neck was acquired in addition.

### OBSERVATION:

- Images reveal gross asymmetry in the uptake of radiotracer by the mandibular condyles. Significantly increased tracer uptake noted in the mandibular condyle on the right side. Normal tracer uptake noted in the mandibular condyle on the left side.
- No definite focus of abnormal tracer uptake in rest of the imaged portion of study.

### IMPRESSION:

- Scintigraphic picture is highly suggestive of mandibular condylar hyperplasia on the right side.
- No definite focus of abnormal tracer uptake in rest of the imaged portion of study.

*Dr. M.S. Senthilnathan*

Dr. M.S. Senthilnathan  
MBBS, MD (Nuclear Medicine)  
Consultant in Nuclear Medicine

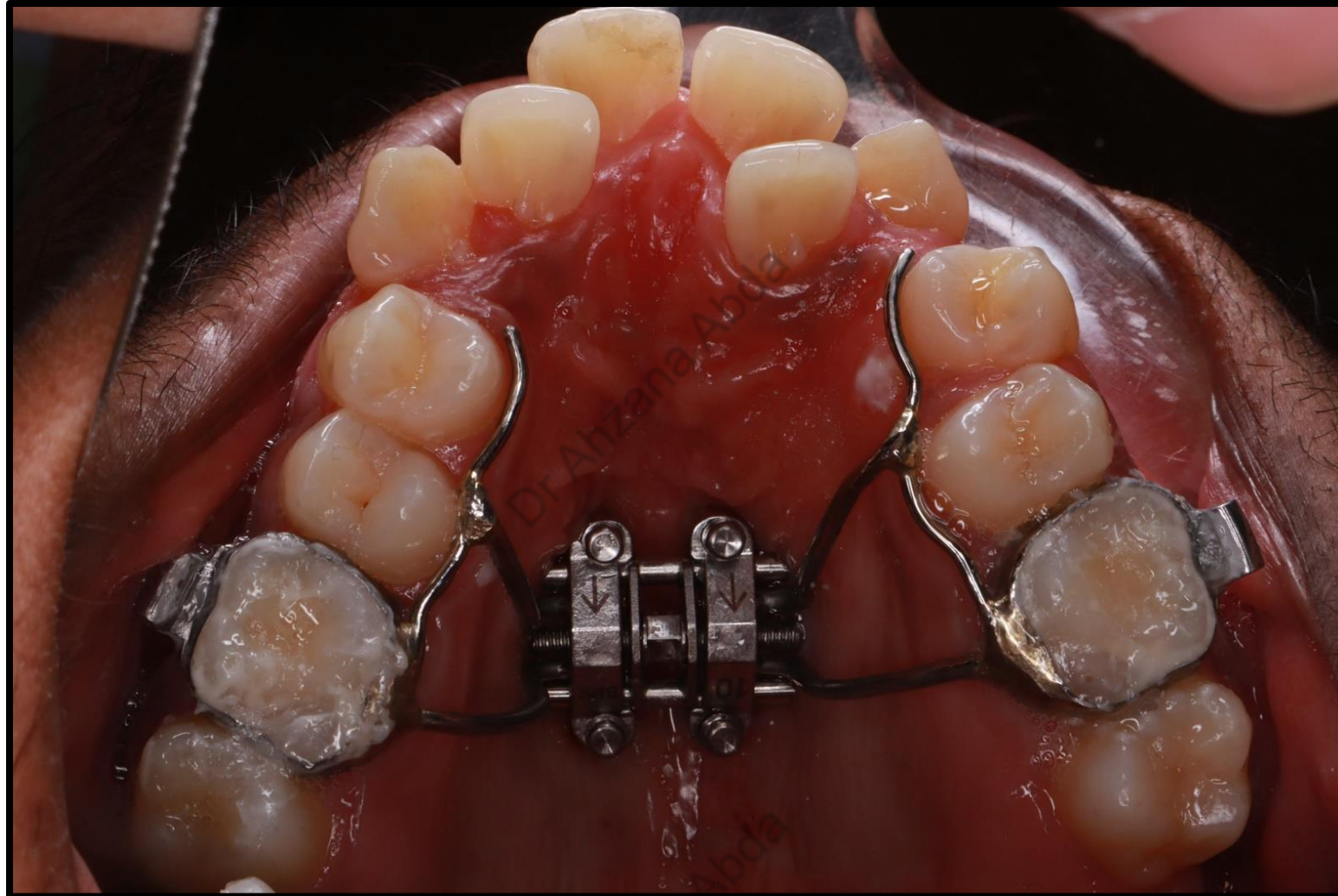
Percentage uptake for the Right side & Left side  
are 55.2% and 44.8% respectively - Suggesting  
Condylar hyperplasia on the Right side

DR. M.S. SENTHILNATHAN  
MBBS, MD (Nuclear Medicine)  
NIC Reg. No. 347473  
Consultant of Nuclear Medicine  
Yenepoya Medical College

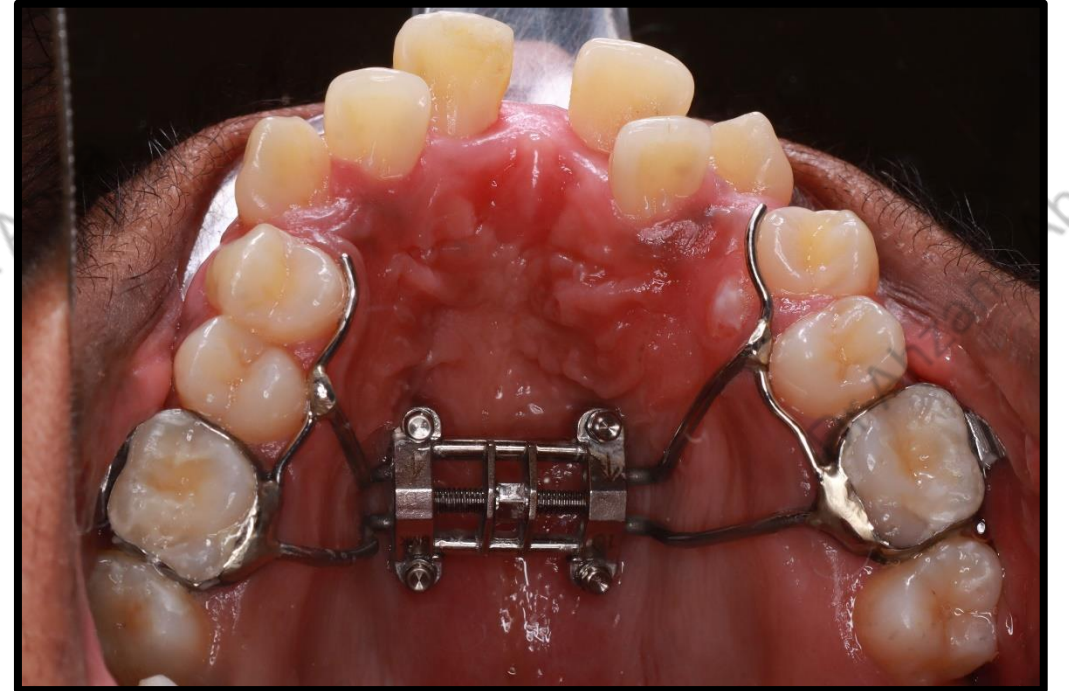
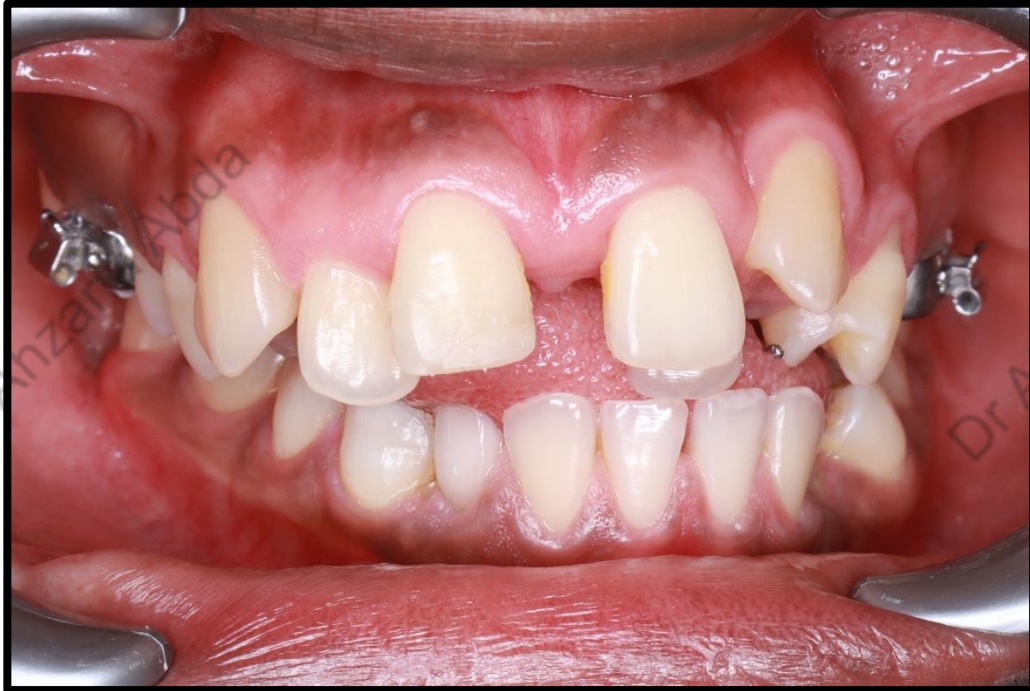## **TREATMENT OBJECTIVES**

1. Correction of mouth breathing habit
2. Correction of the skeletal base
3. Correction of laterognathy
4. Correction of facial asymmetry
5. Correction of constricted upper and lower arch
6. Correction of midline
7. Correction of open bite
8. Correction of crossbite irt 22,24,25
9. Correction of canine impaction 33,43
10. Correction of occlusal cant
11. Correction of upper and lower anterior crowding
12. Correction of upper anterior proclination
13. Correction of rotation irt 24,25
14. Correction of molar relation and canine relation
15. Correction of overjet
16. Correction of overbite

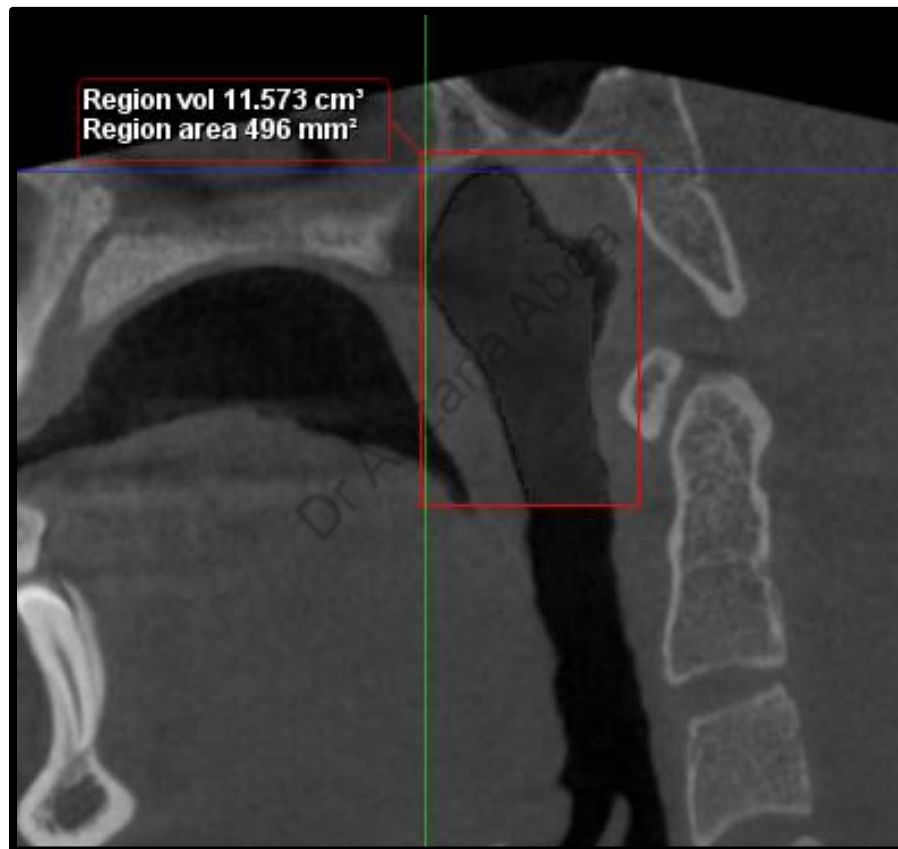## MSE (MAXILLARY SKELETAL EXPANDER)



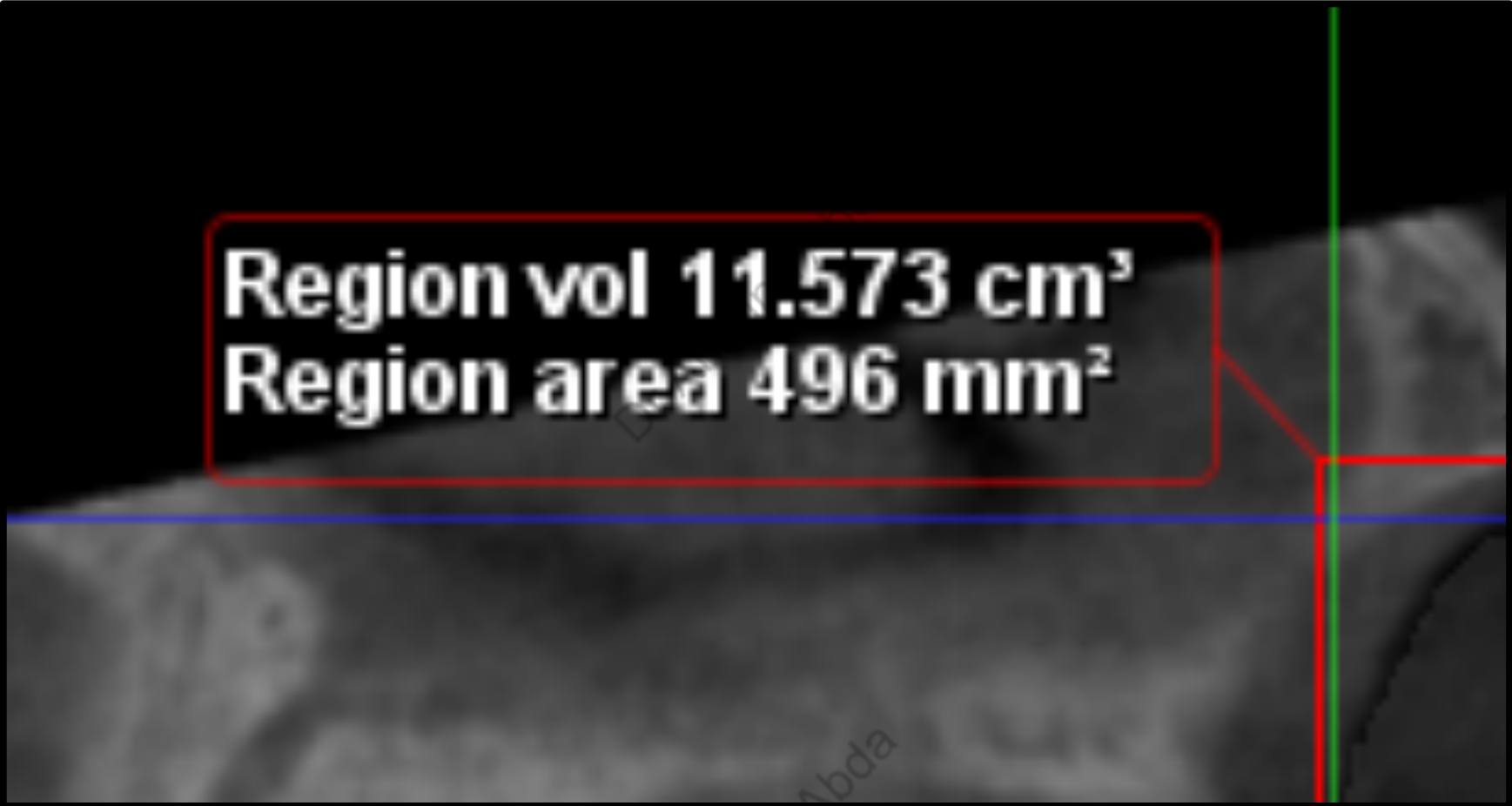
# POST EXPANSION



# PRE-POST EXPANSION

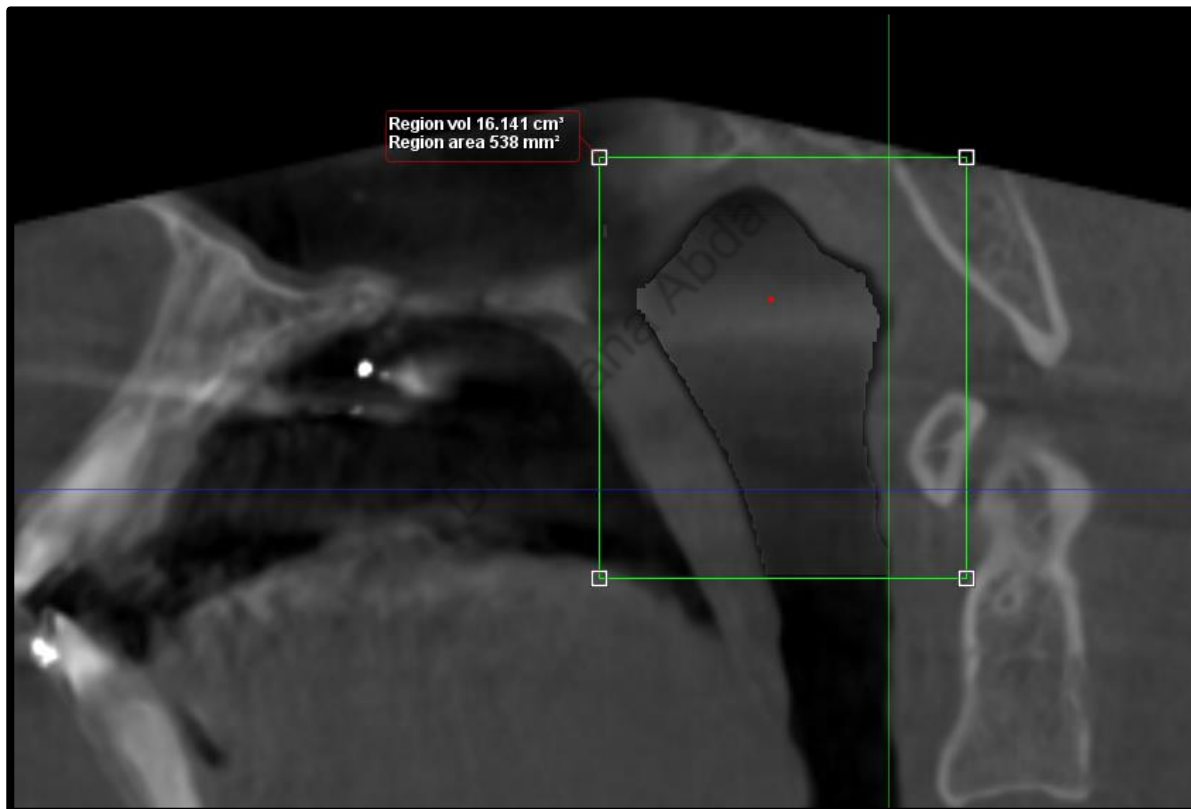


## PRE-POST EXPANSION




**Region vol 11.573 cm<sup>3</sup>**  
**Region area 496 mm<sup>2</sup>**

# PRE-POST EXPANSION

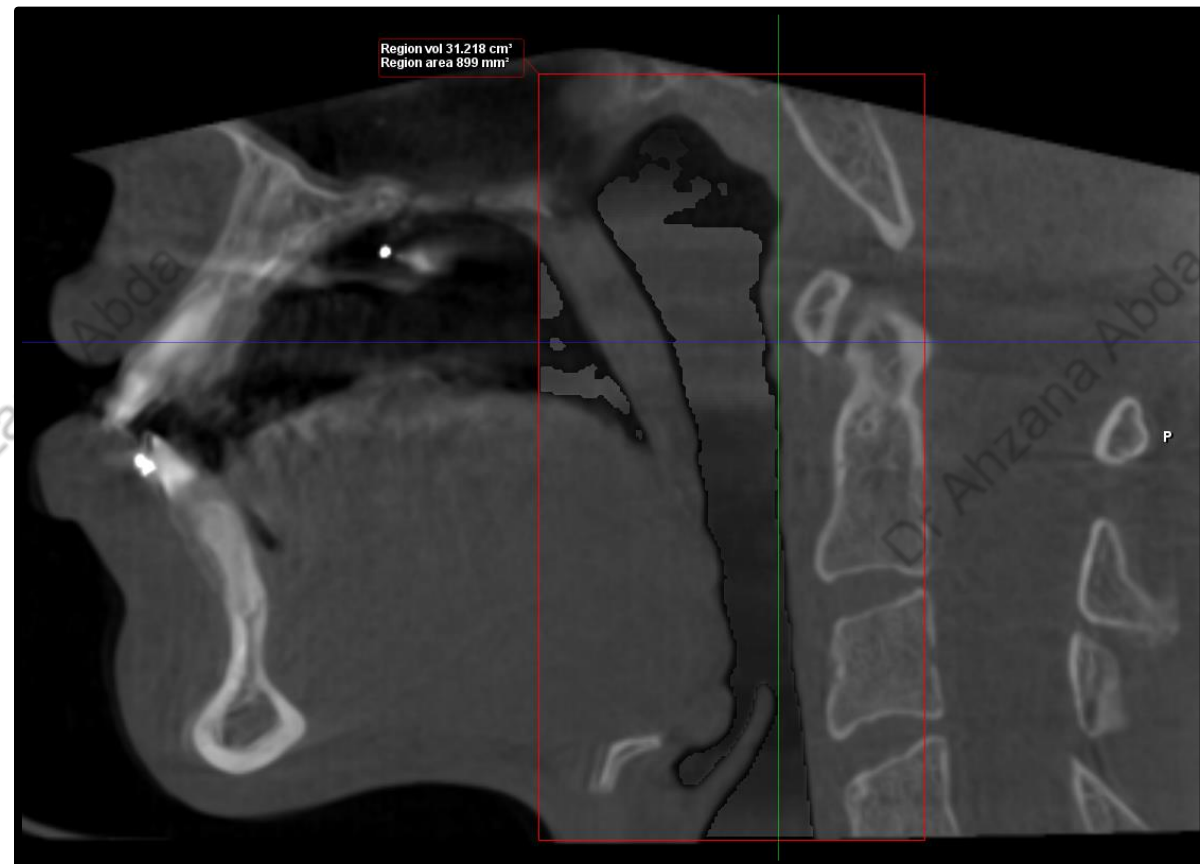
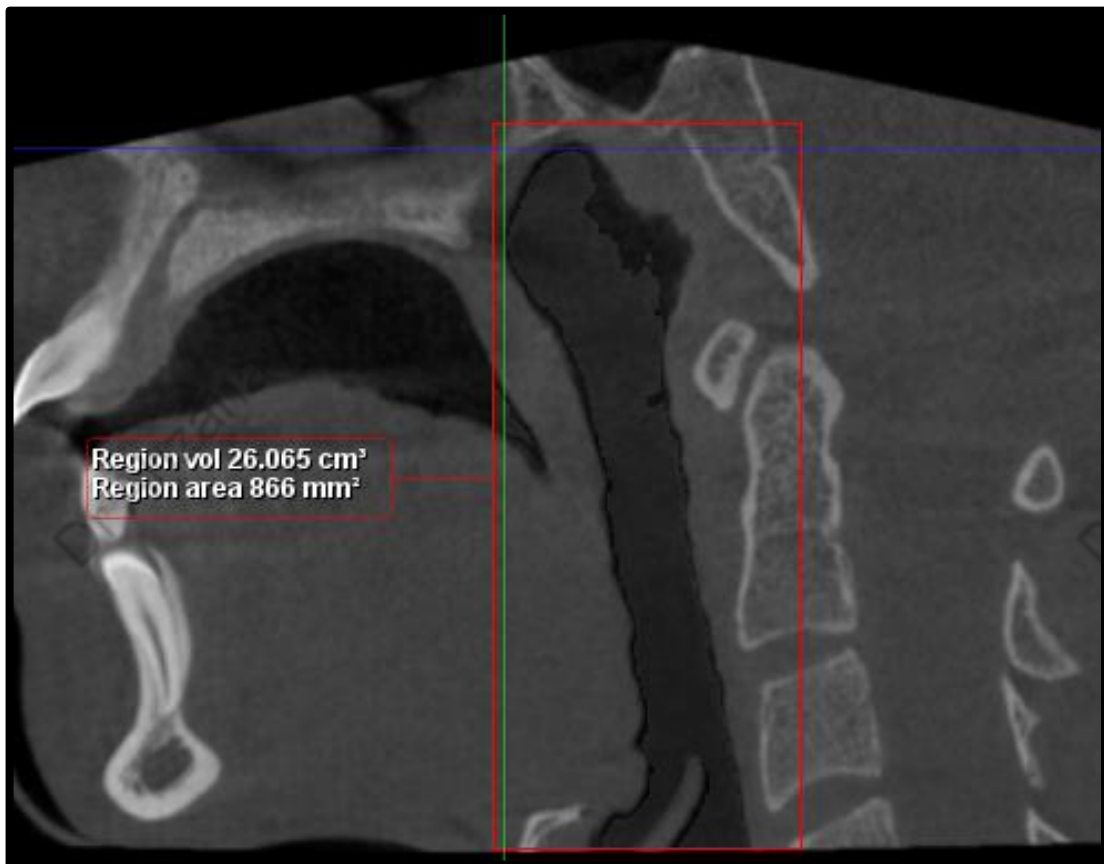
## PRE-POST EXPANSION




**Region vol 16.141 cm<sup>3</sup>**  
**Region area 538 mm<sup>2</sup>**

# AIRWAY CHANGES PRE-POST EXPANSION

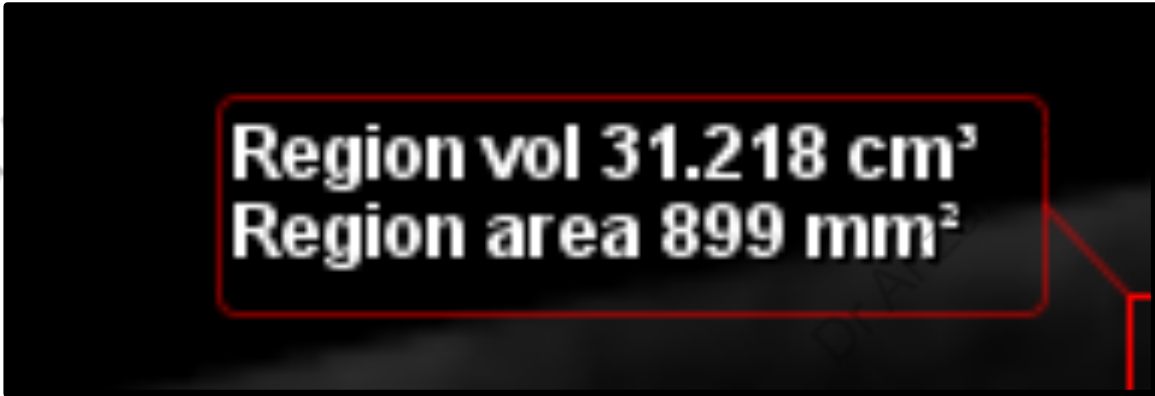


## AIRWAY CHANGES PRE-POST EXPANSION



Region vol 26.065 cm<sup>3</sup>  
Region area 866 mm<sup>2</sup>

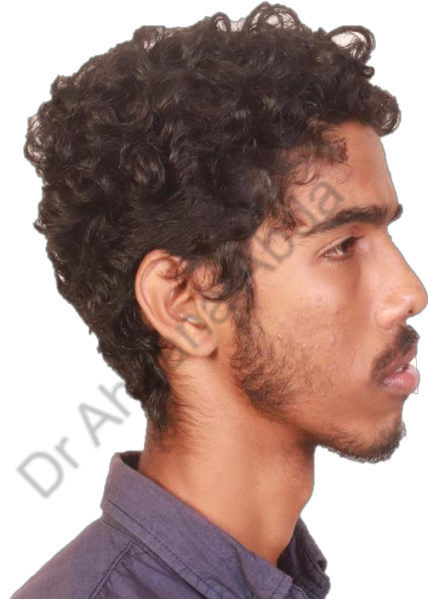This image shows a cross-sectional scan of an airway before expansion. A red rectangular box highlights the text indicating a volume of 26.065 cm<sup>3</sup> and an area of 866 mm<sup>2</sup>. The background is a dark, grayscale medical scan.



Region vol 31.218 cm<sup>3</sup>  
Region area 899 mm<sup>2</sup>

This image shows a cross-sectional scan of the same airway after expansion. A red rectangular box highlights the text indicating an increased volume of 31.218 cm<sup>3</sup> and an area of 899 mm<sup>2</sup>. The background is a dark, grayscale medical scan.

# MID TREATMENT-EXTRAORAL

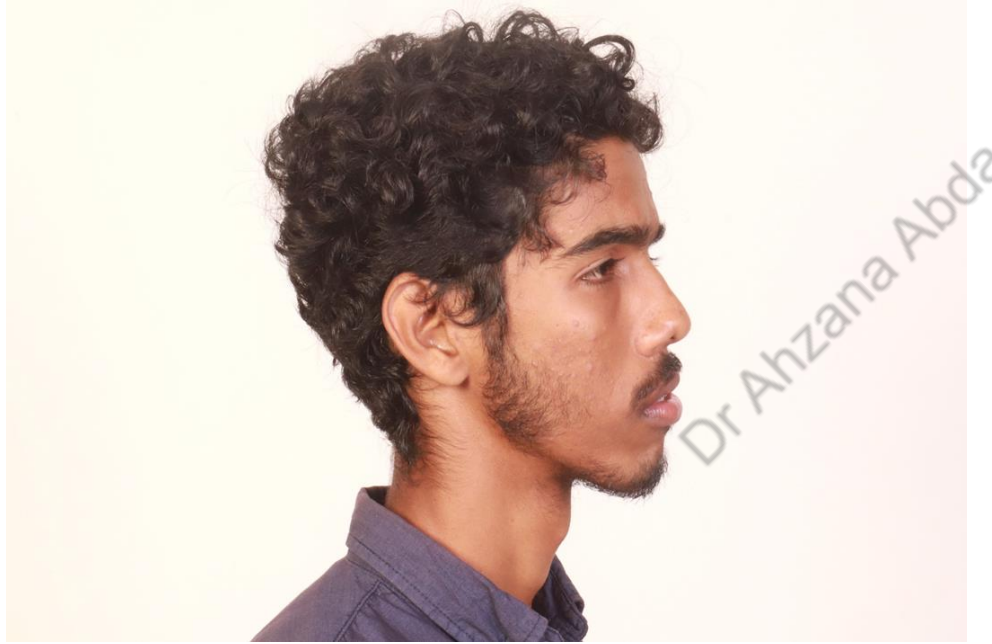



Dr Ahzana A

Dr Ahzana A

Dr Ahzana A



Dr Ahzana Abda

Dr Ahzana Abda

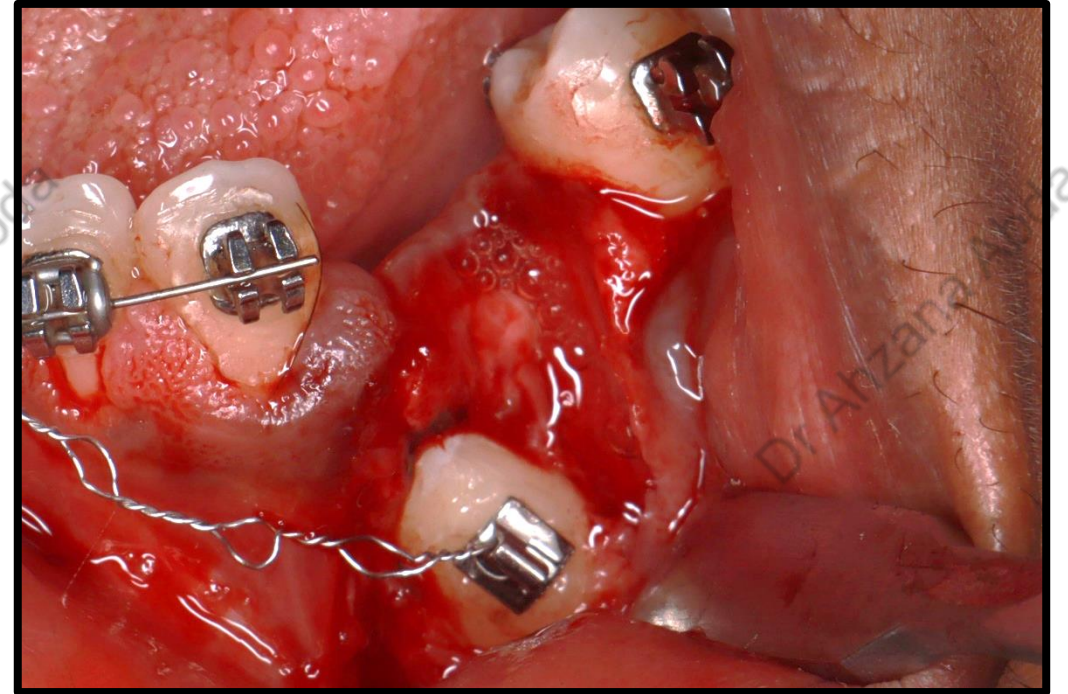
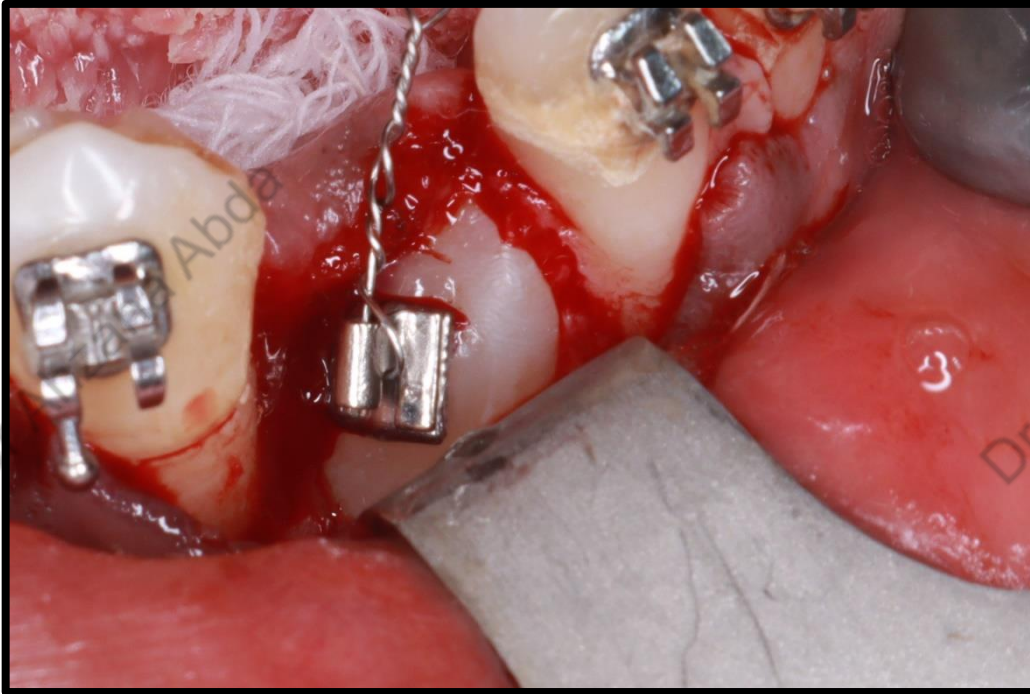
Dr Ahzana Abda

Dr Ahzana Abda

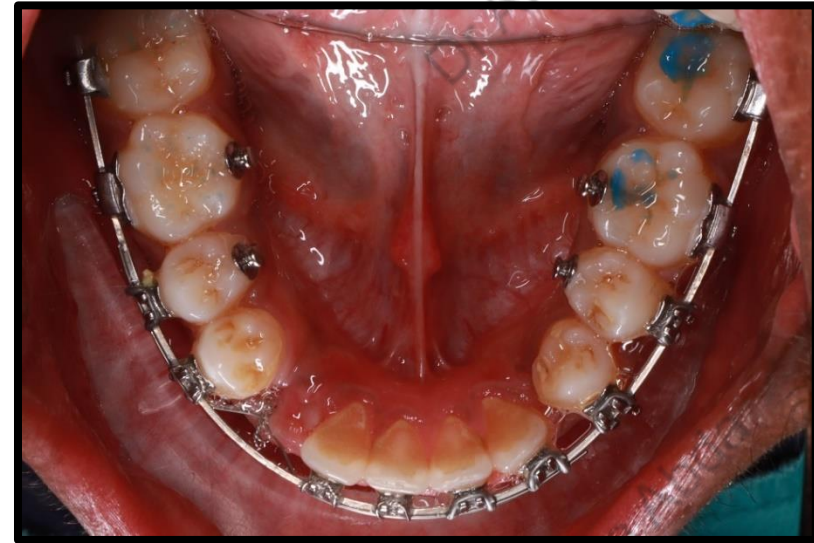
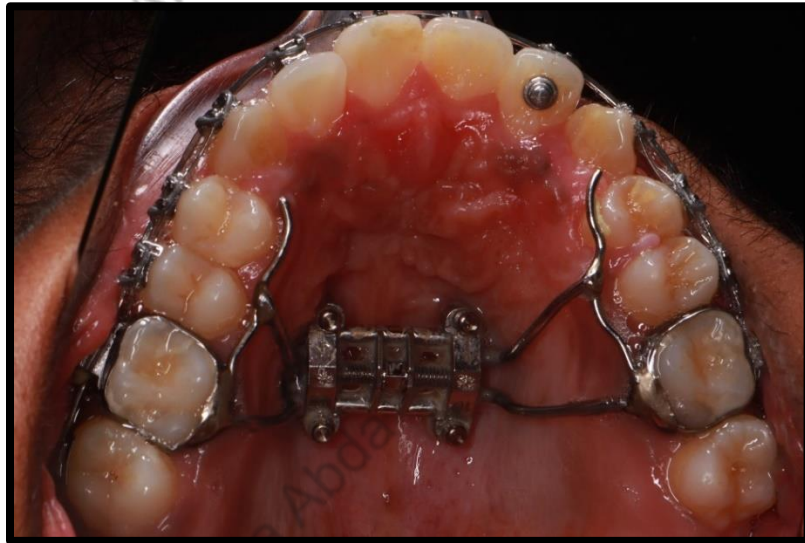
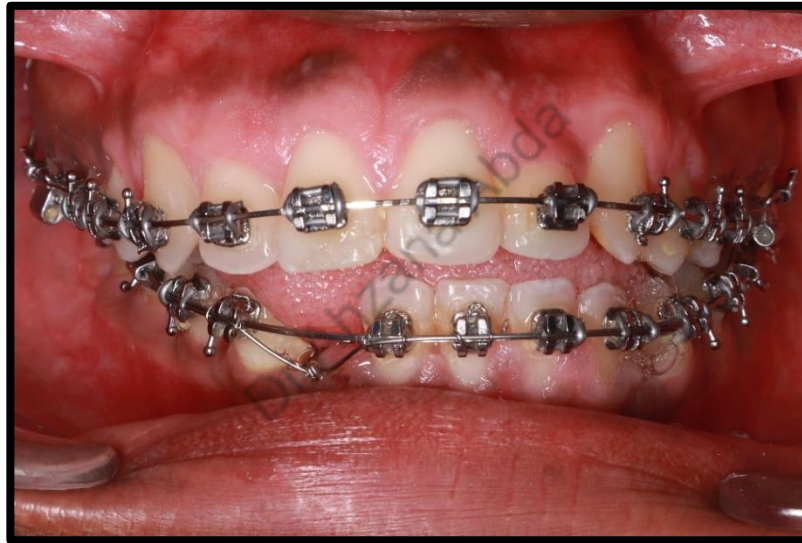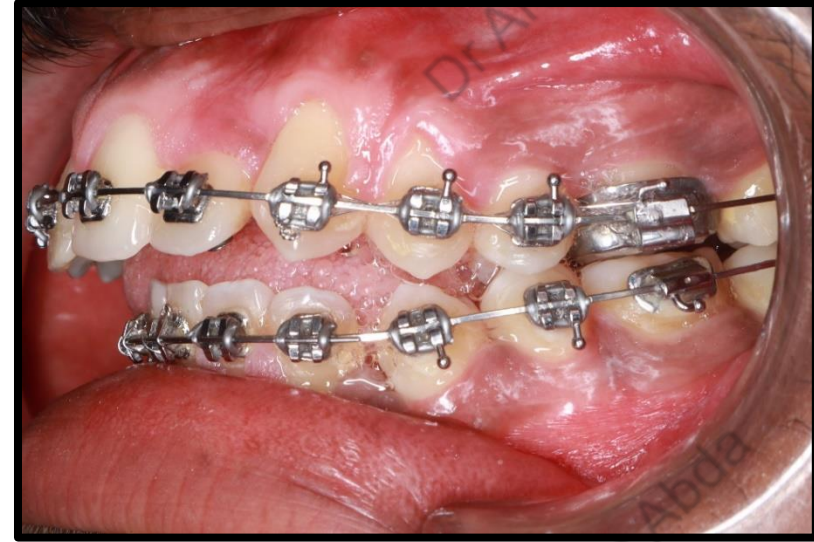
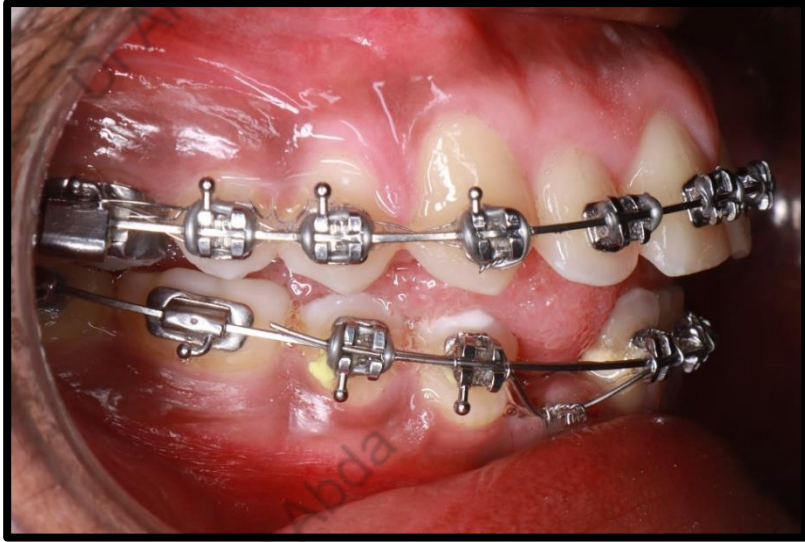
Dr Ahzana Abda

Dr Ahzana Abda

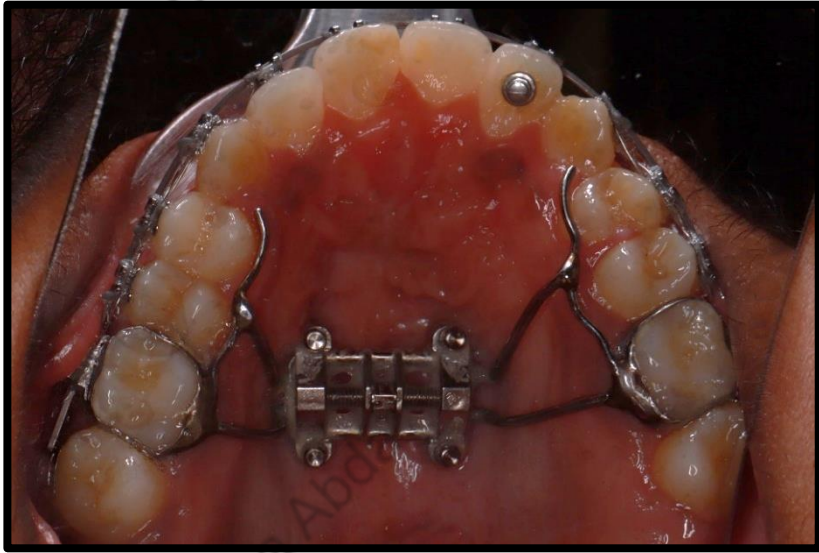
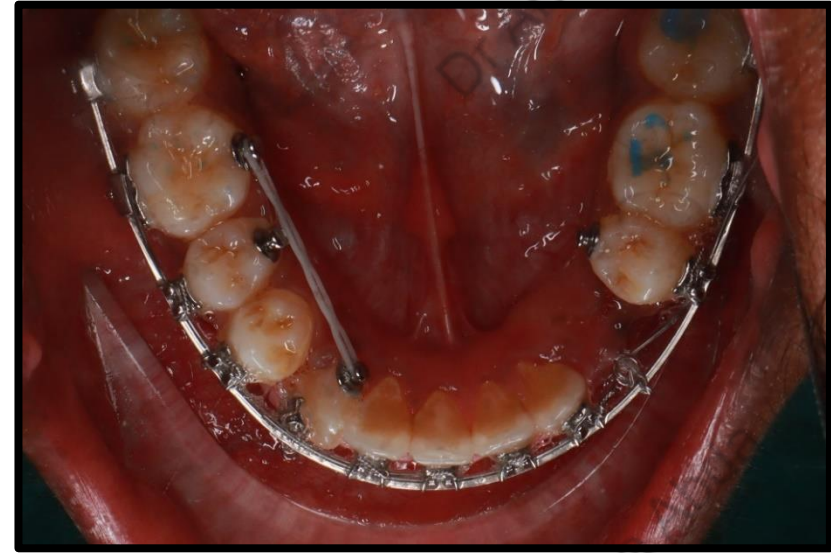
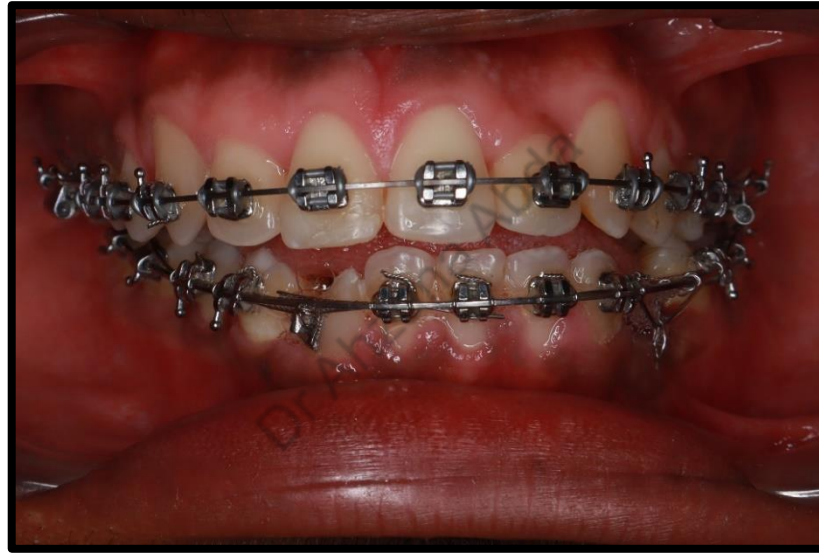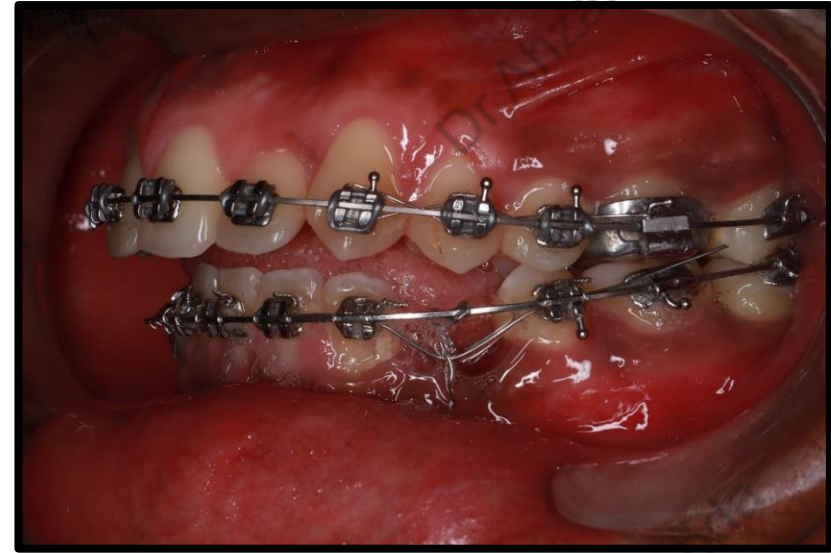
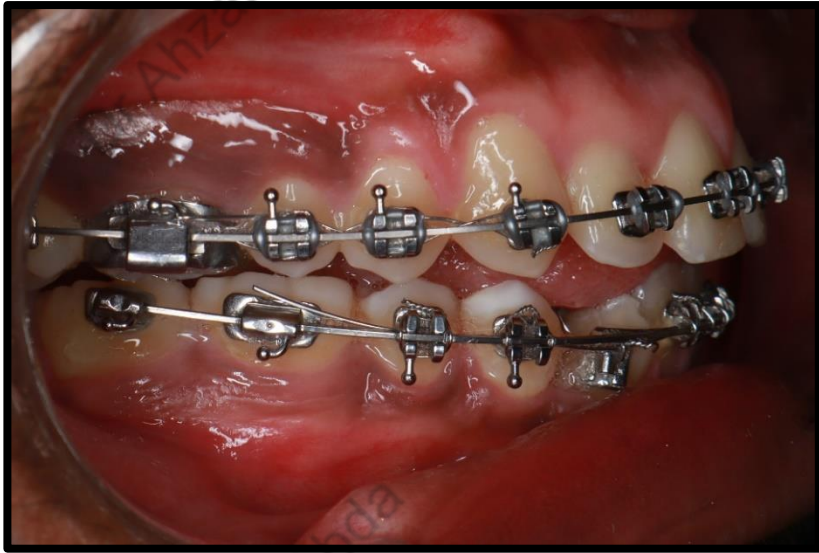# DISIMPACTION OF 33 AND 43



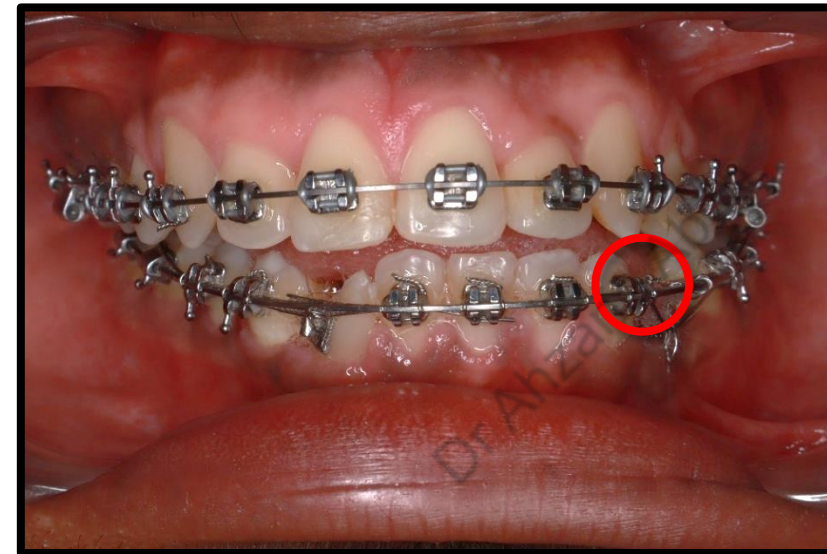
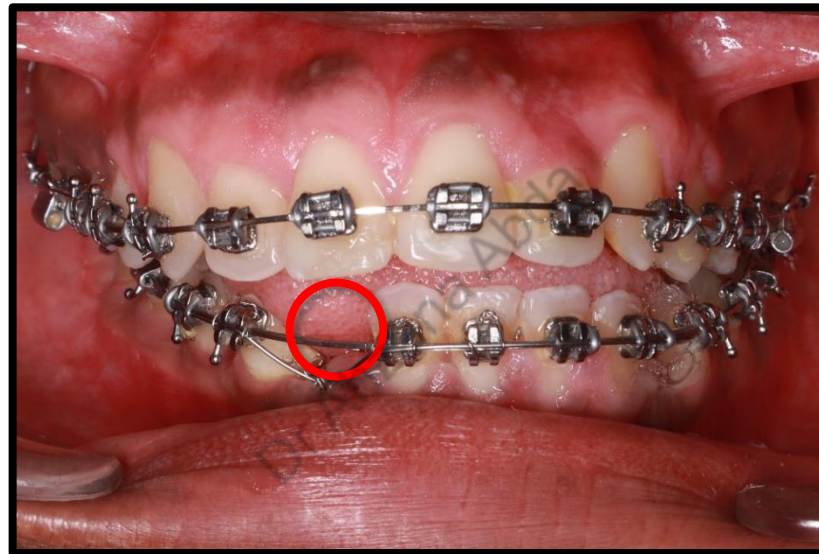
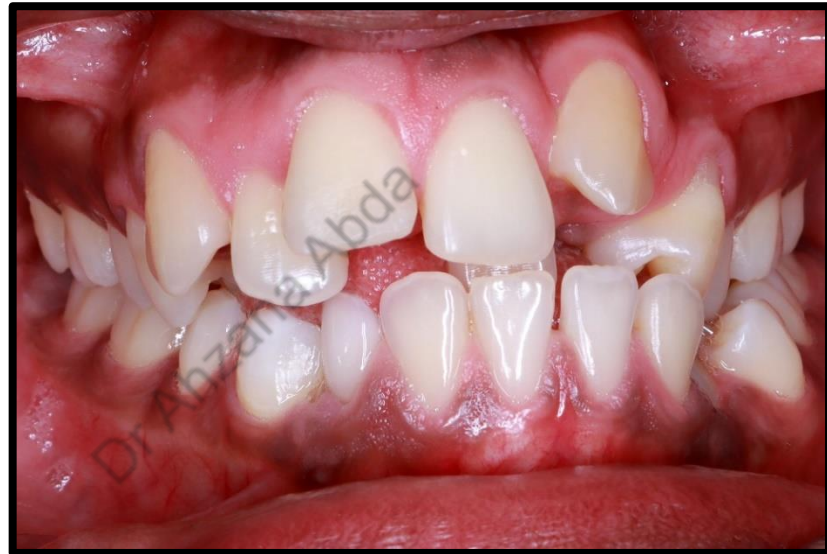# DISIMPACTION OF 43

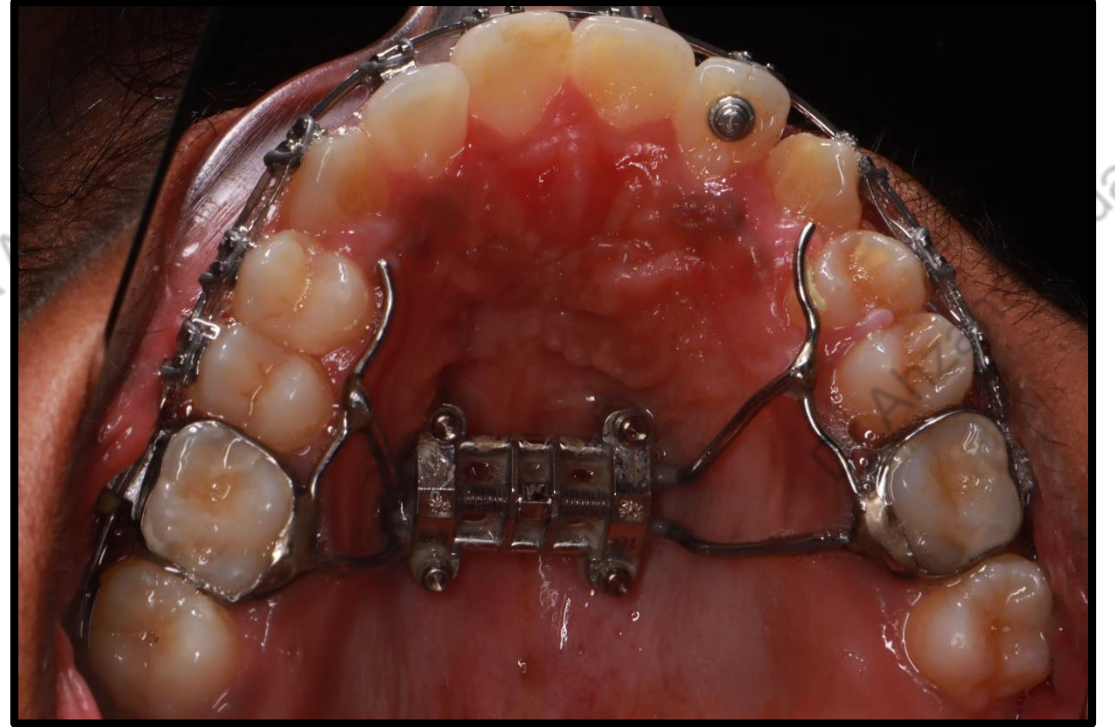
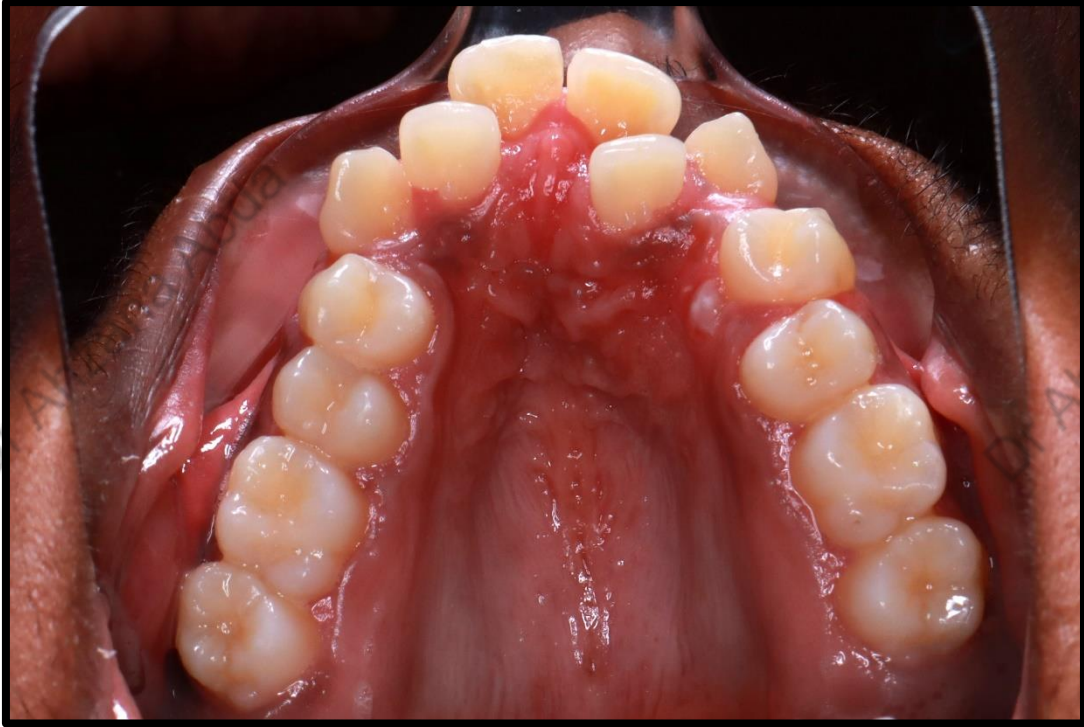


# DISIMPACTION OF 33 AND 43

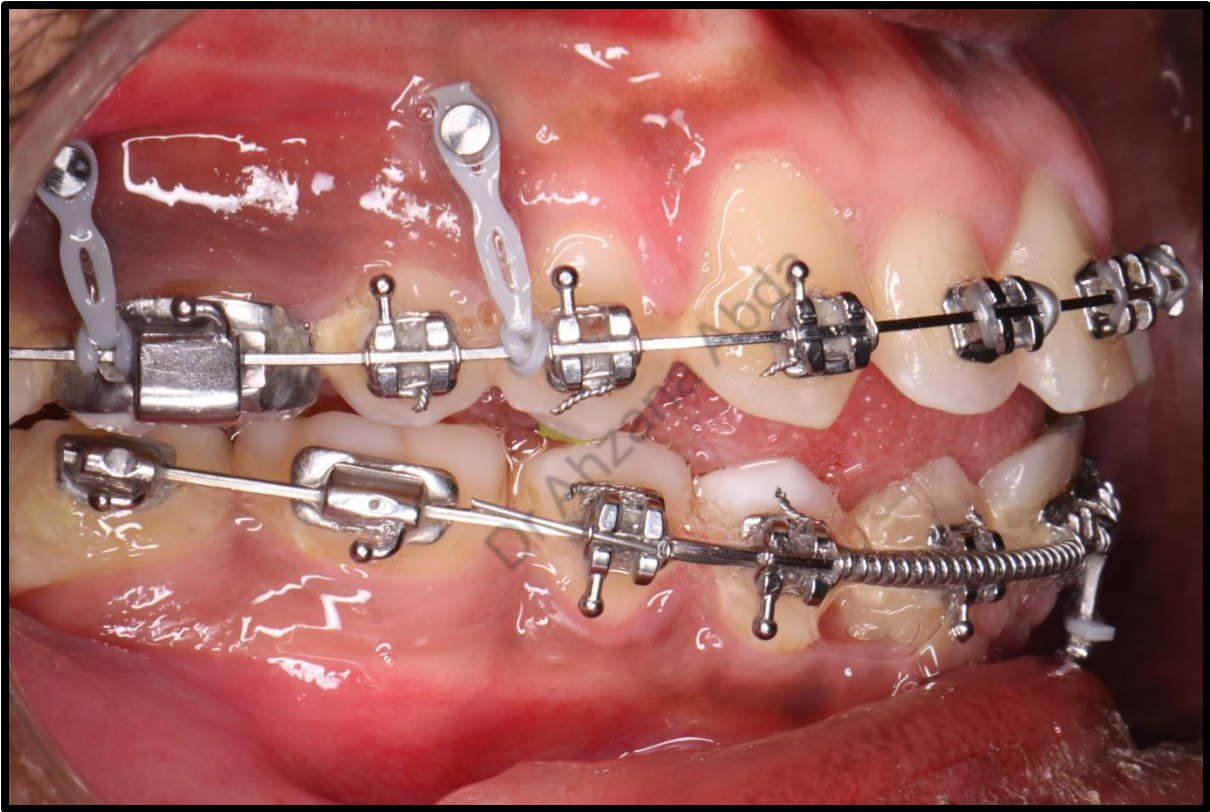


# DISIMPACTION OF 33 AND 43

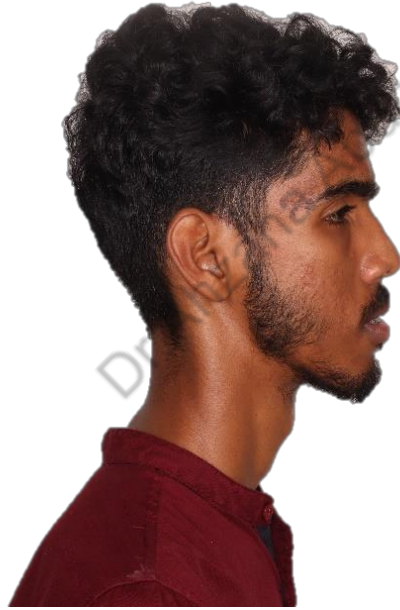



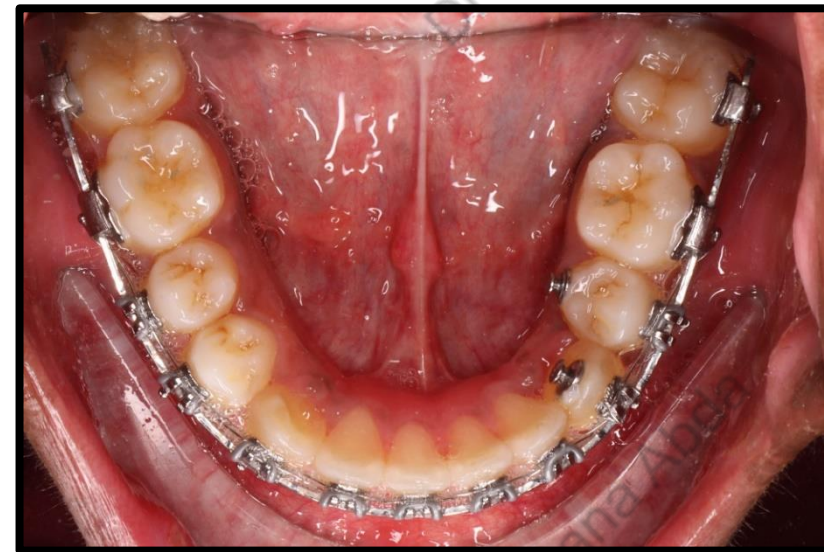
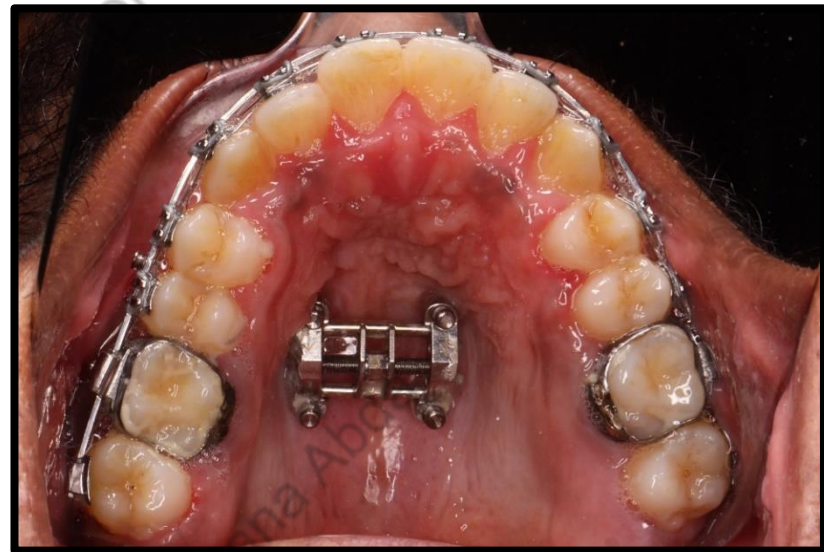
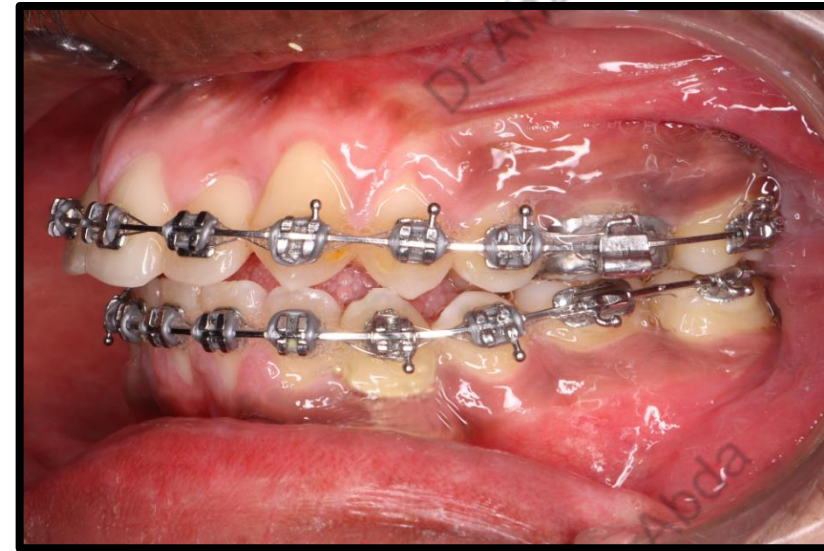
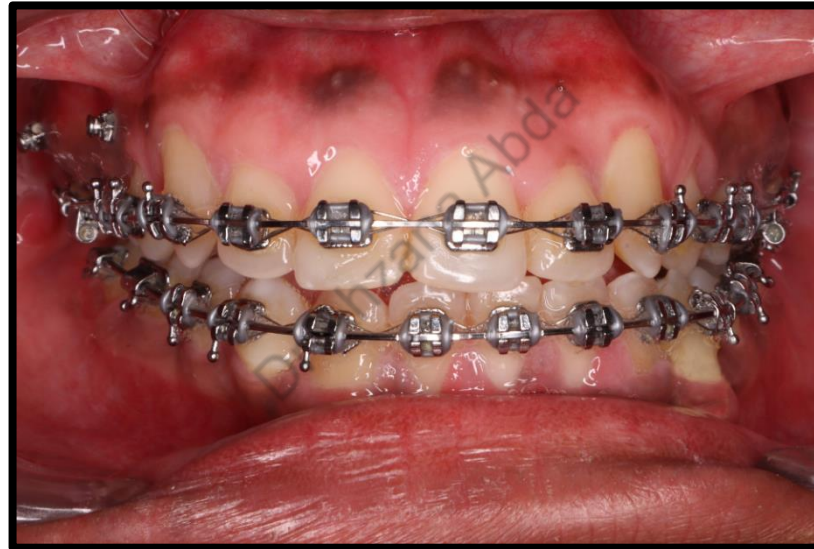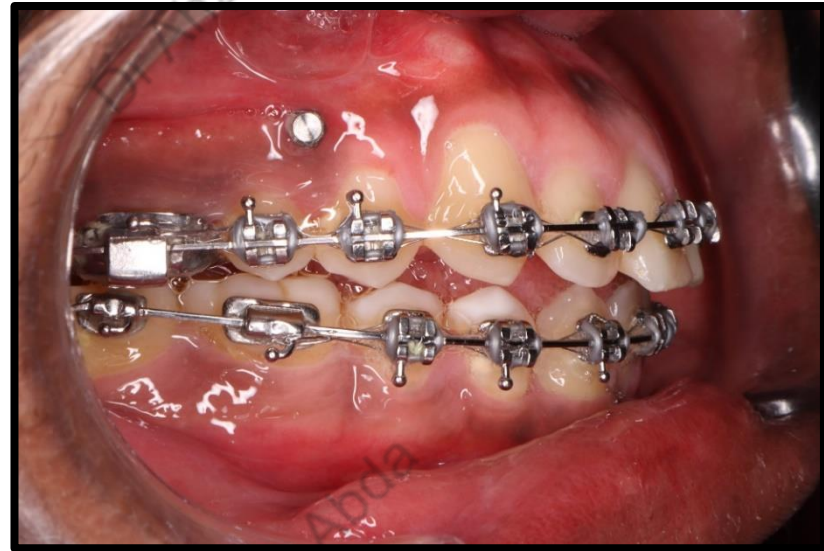
**CORRECTION OF CANT**



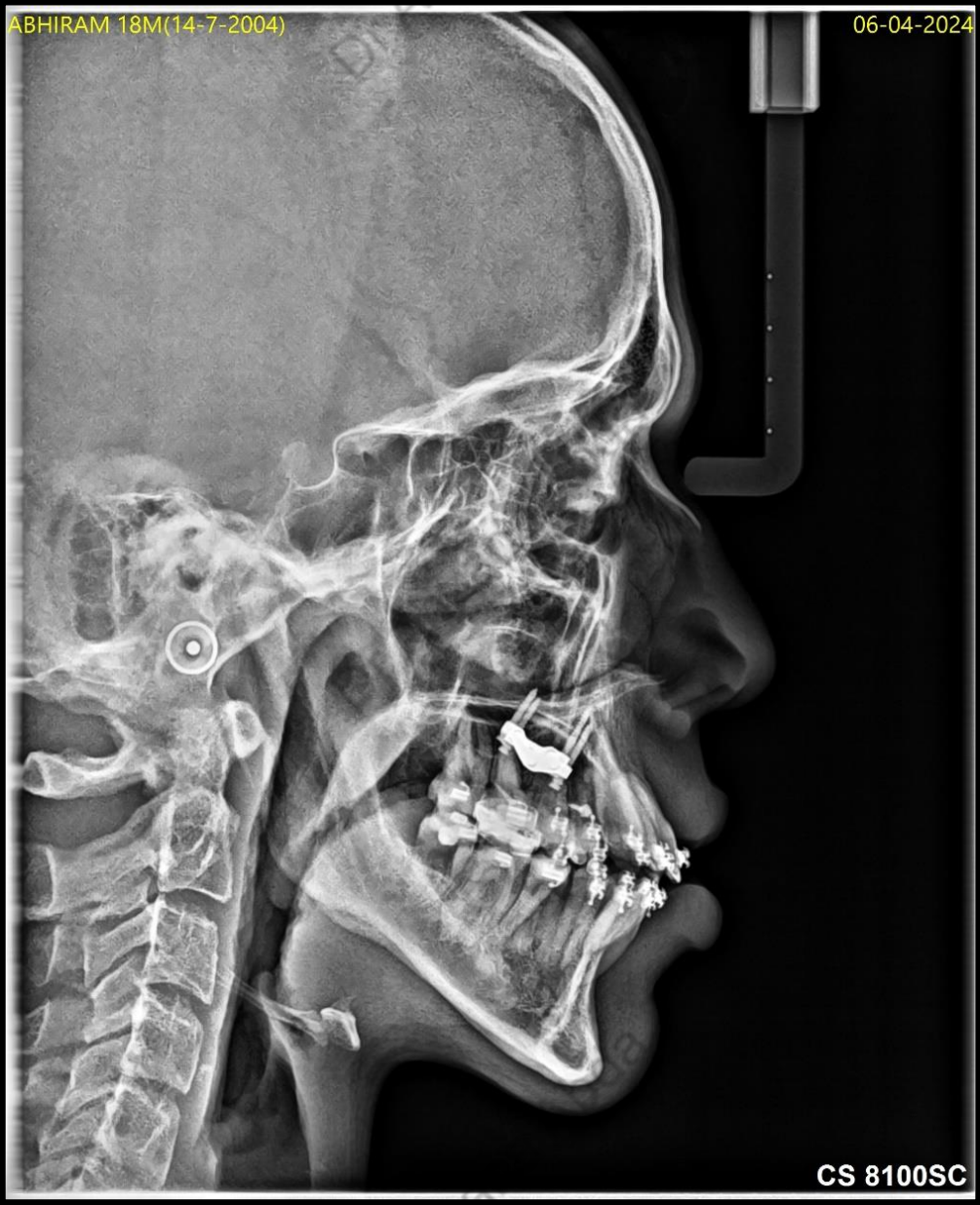# POST DECOMPENSATION –EXTRA ORAL



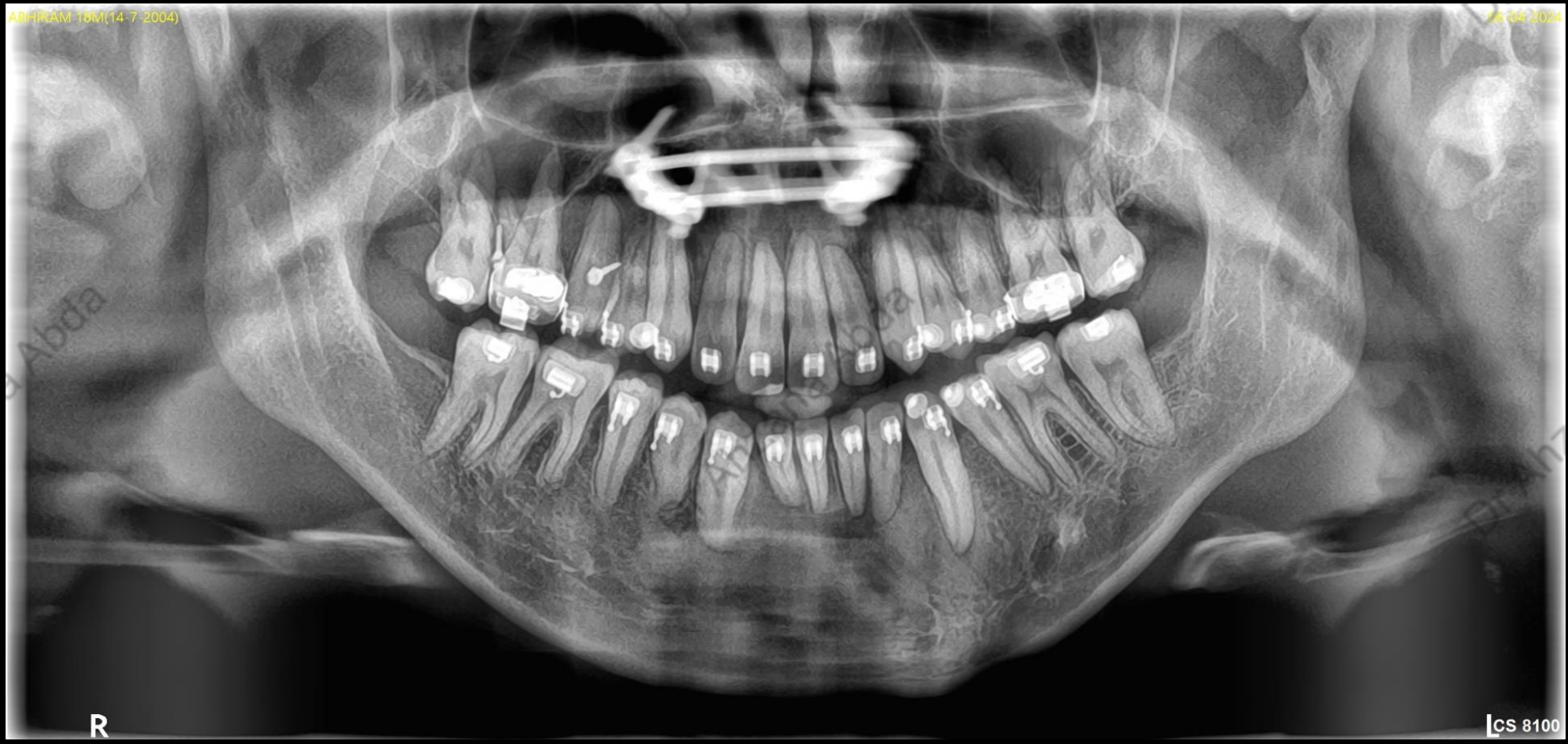
# AFTER DECOMPENSATION - INTRA ORAL



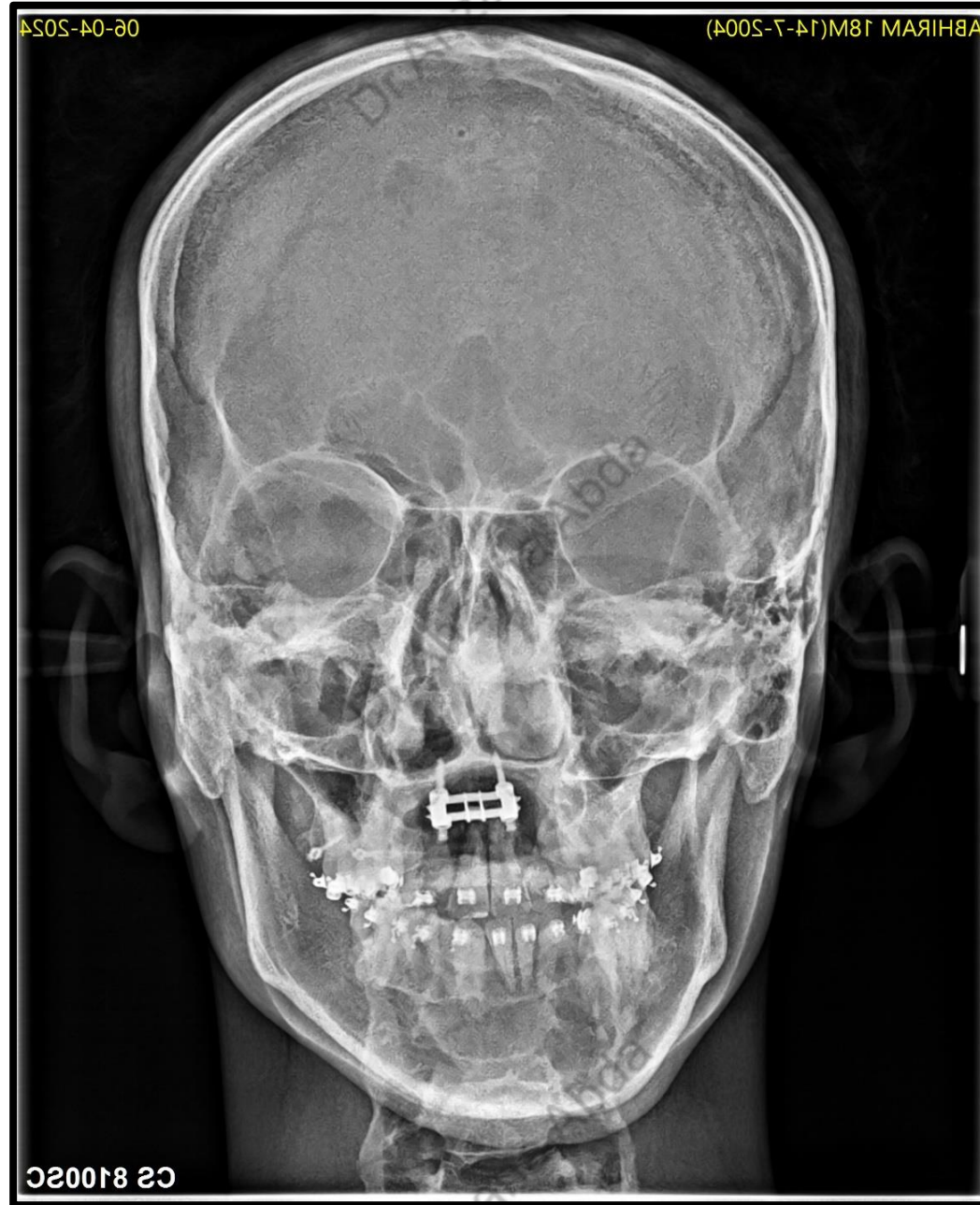
# POST DECOMPENSATION LATERAL CEPHALOGRAM



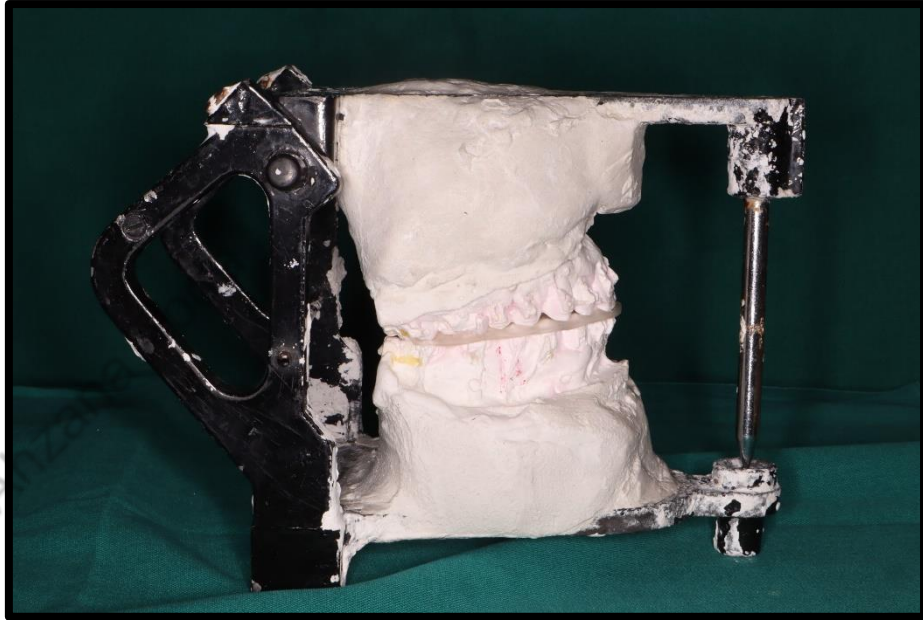
**POST DECOMPENSATION OPG**



# POST DECOMPENSATION PA VIEW

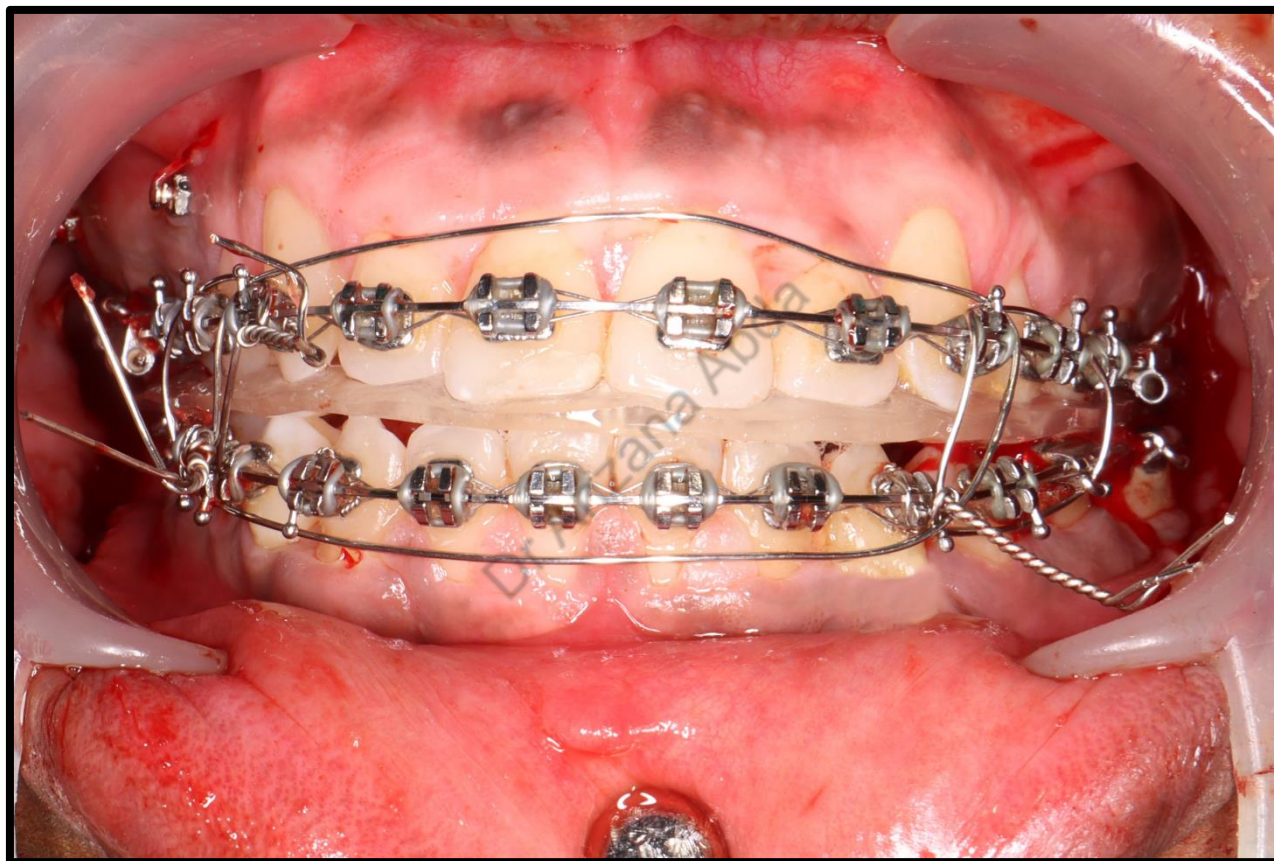


## SPLINT FABRICATION



Asymmetric BSSO with 9 mm mandibular advancement on left side and 4mm mandibular set back on right side

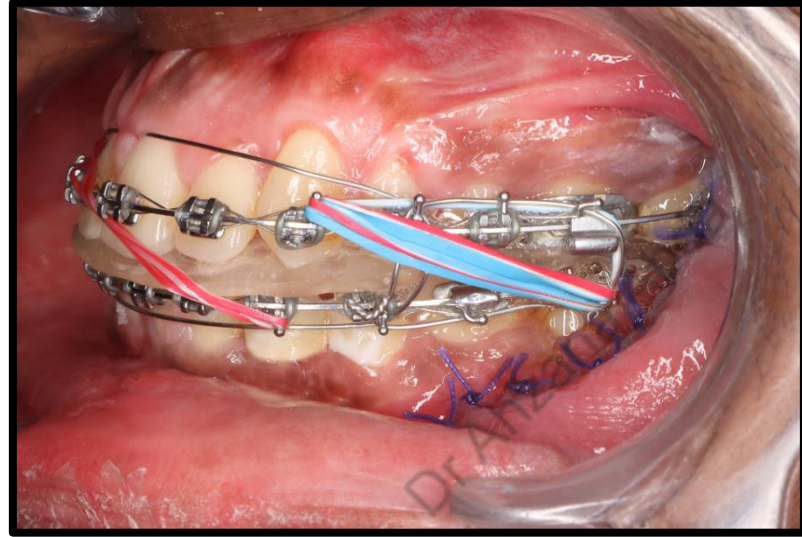
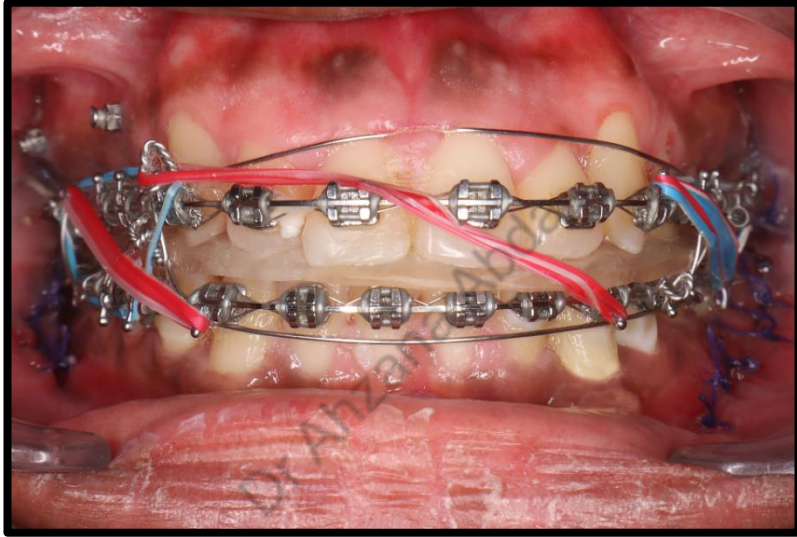
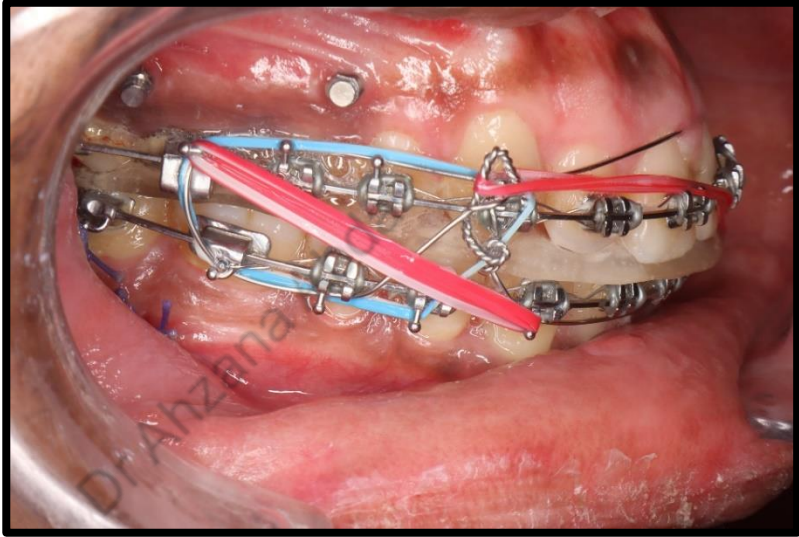
# SPLINT IN PLACE AND INTERMAXILLARY FIXATION



**7 DAYS POSTSURGERY-EXTRA ORAL**



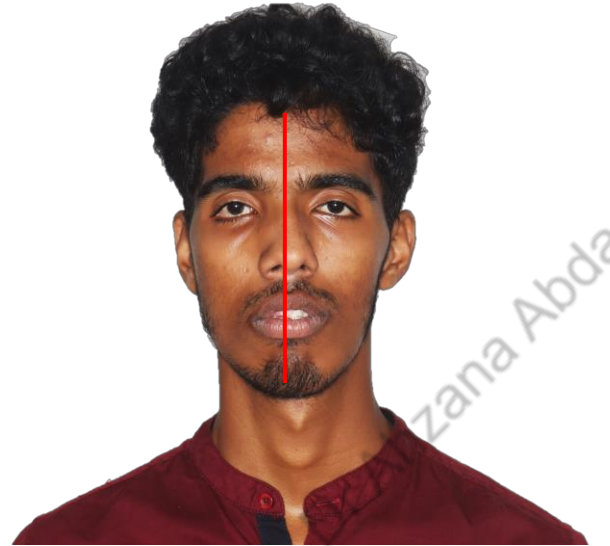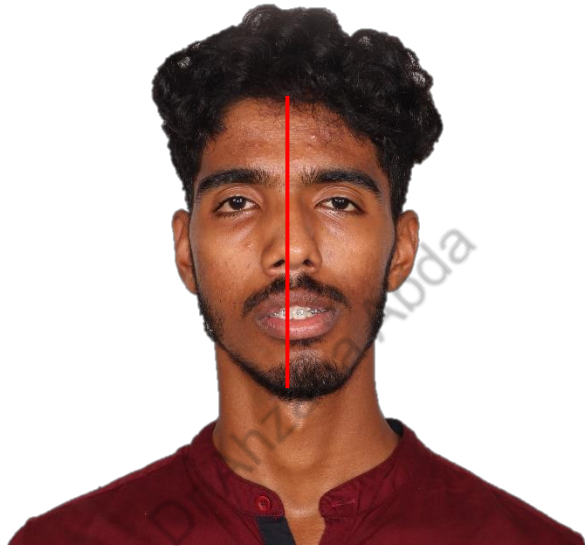
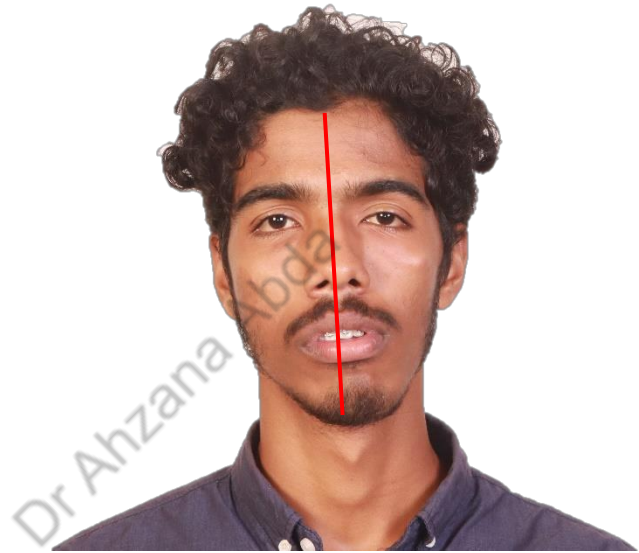**7 DAYS POST SURGERY-INTRA ORAL**



Dr Ahzana Abda

Dr Ahzana Abda

Dr Ahzana Abda

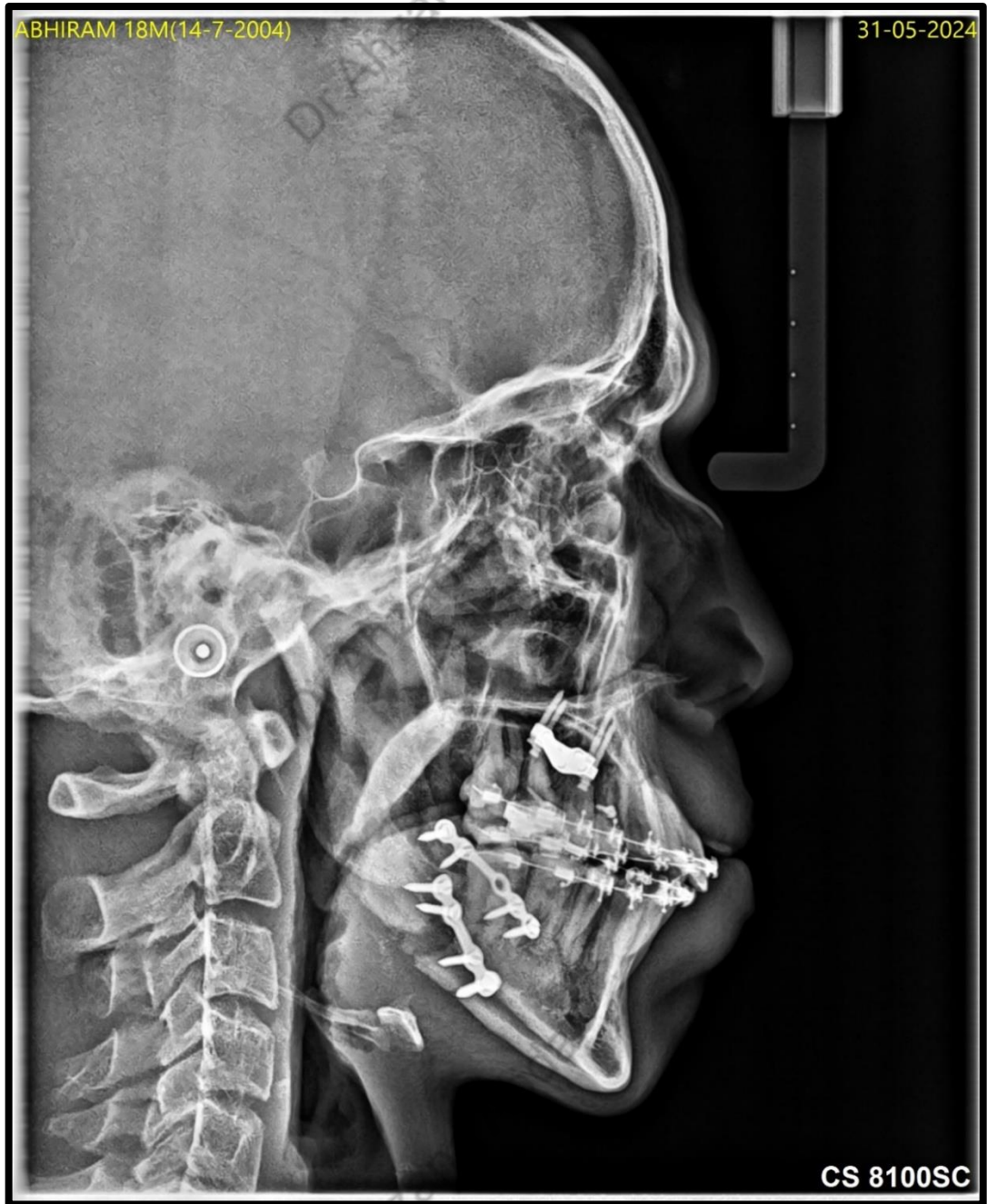

Dr Ahzana Abda

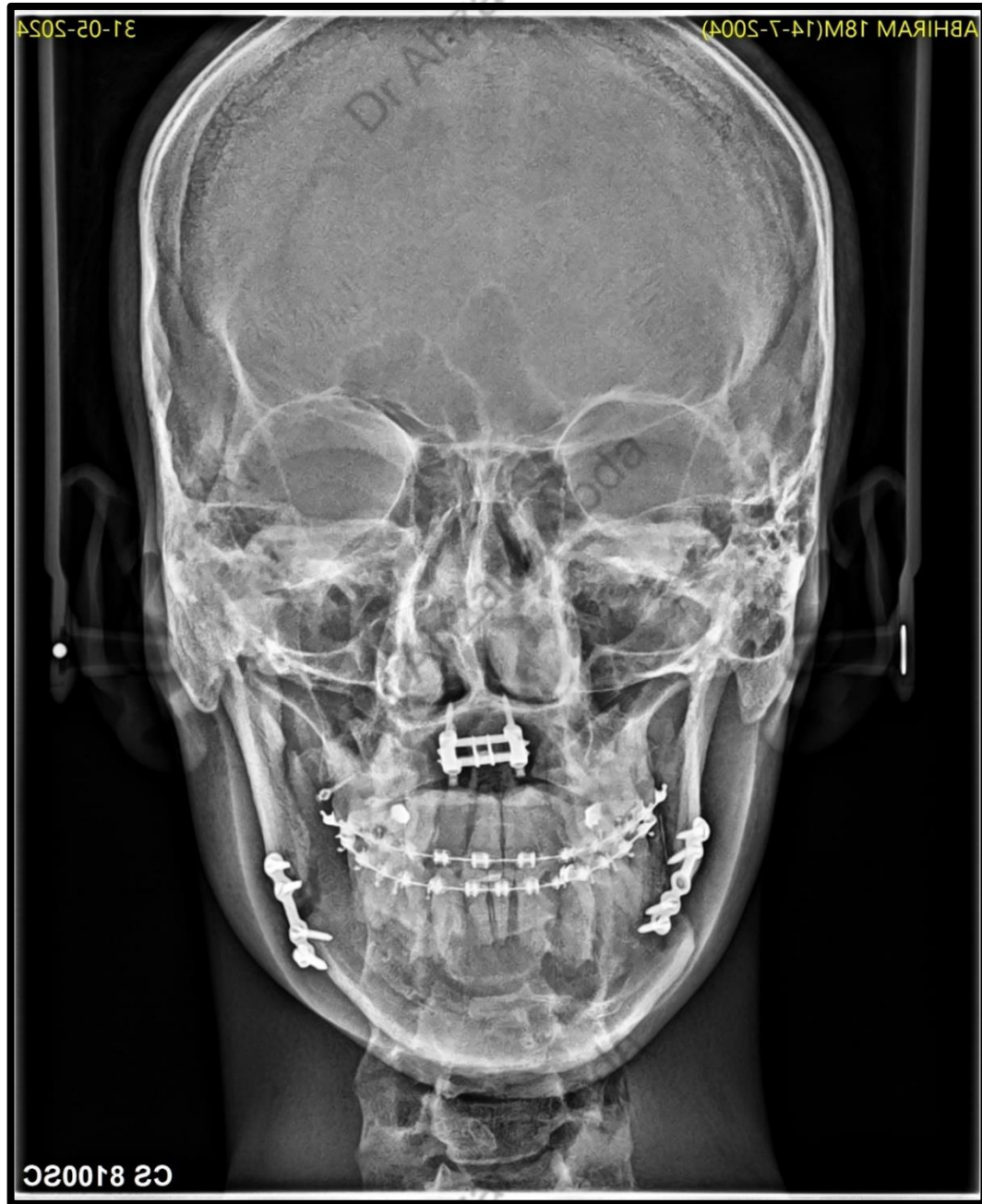
Dr Ahzana Abda

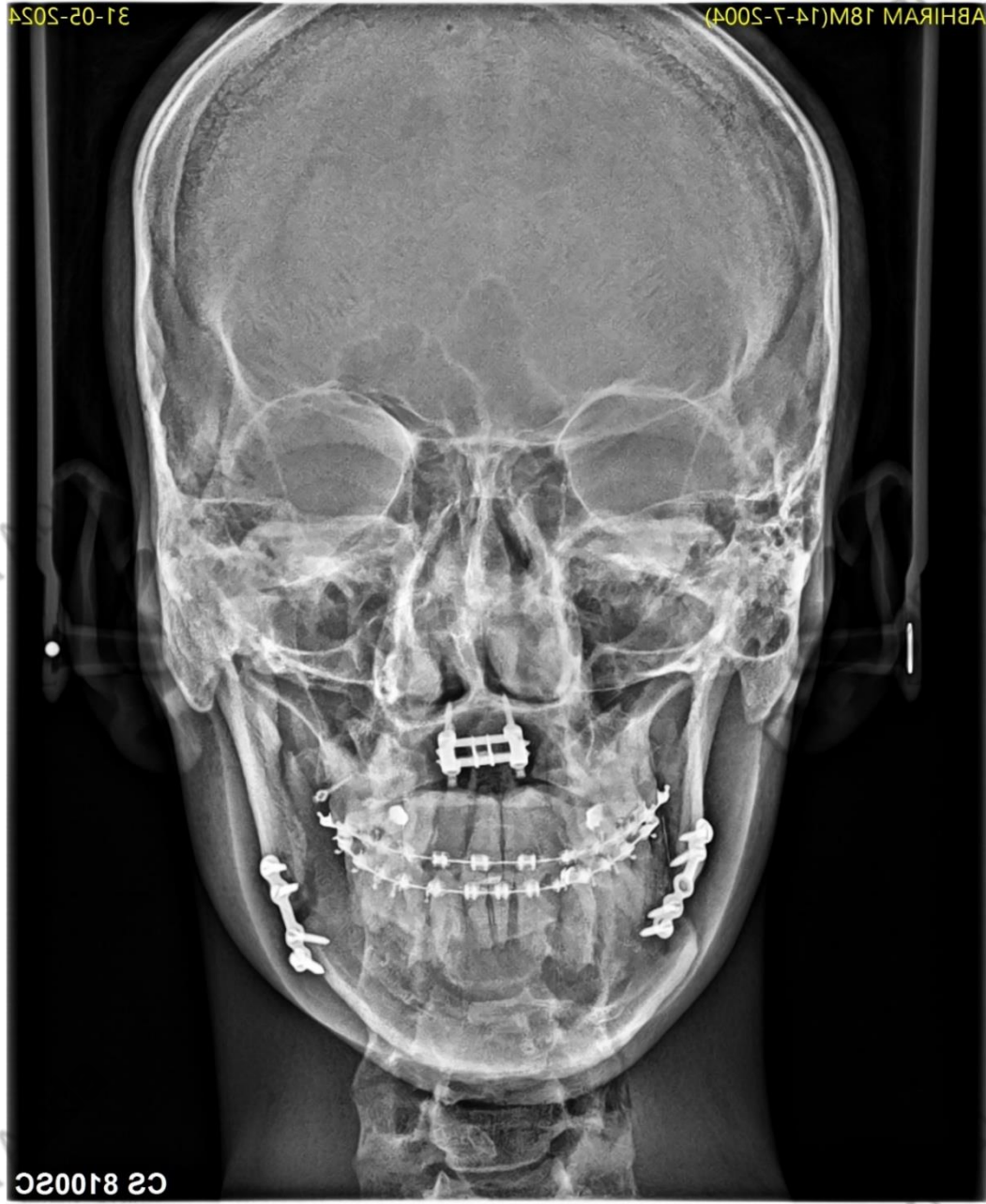
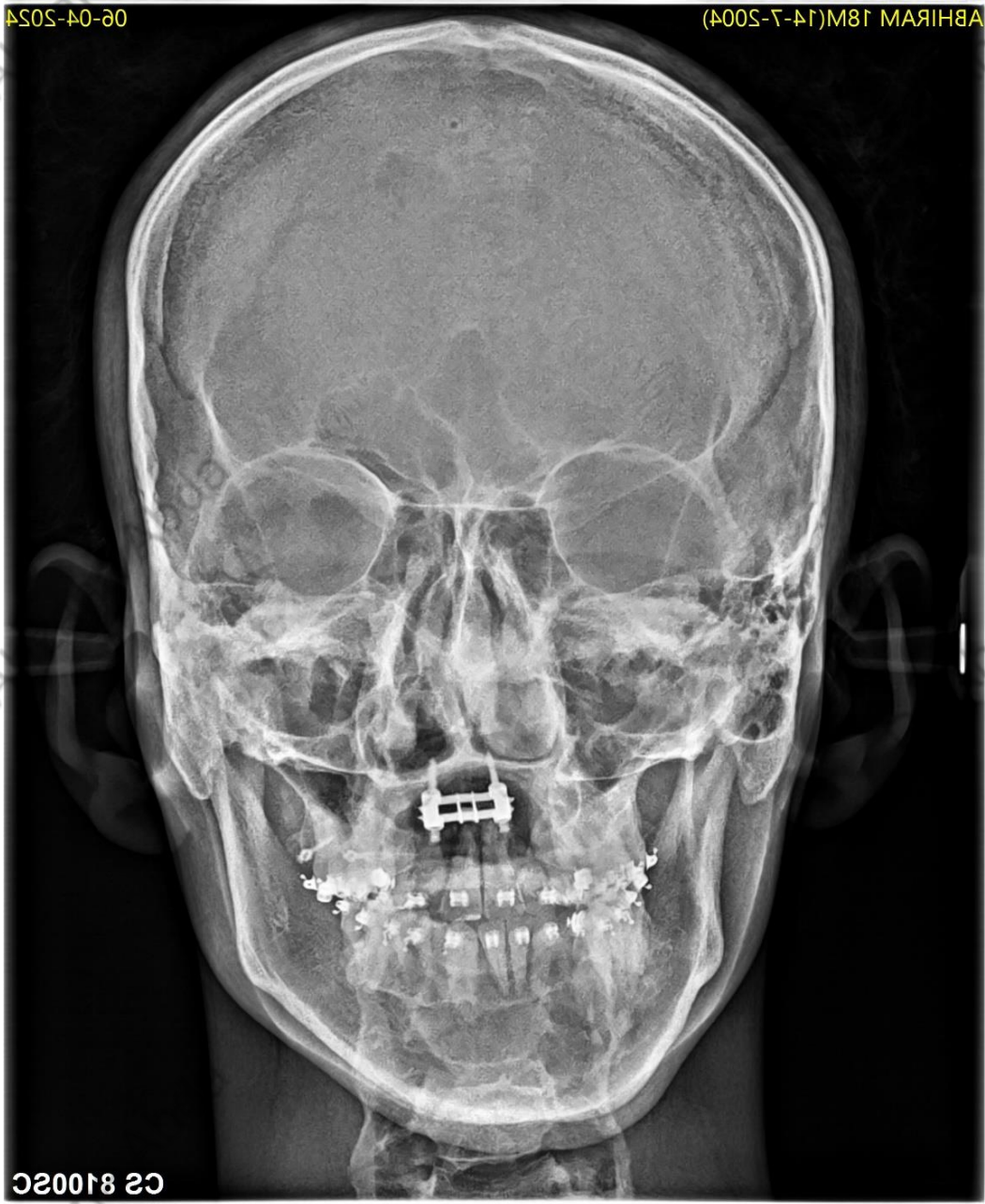
Dr Ahzana Abda

# POST SURGERY-EXTRA ORAL

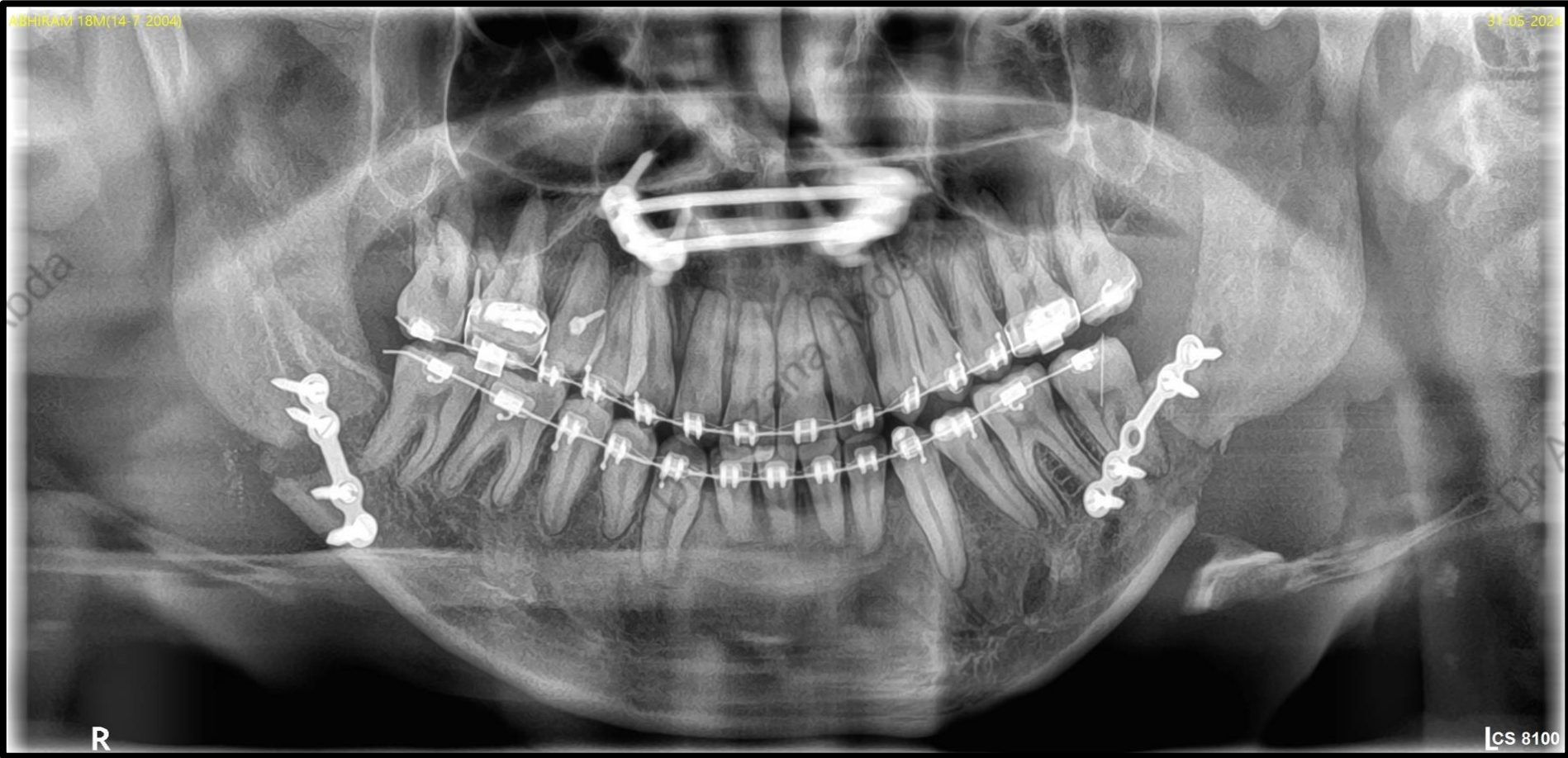


# POST SURGERY PA CEPHALOGRAM





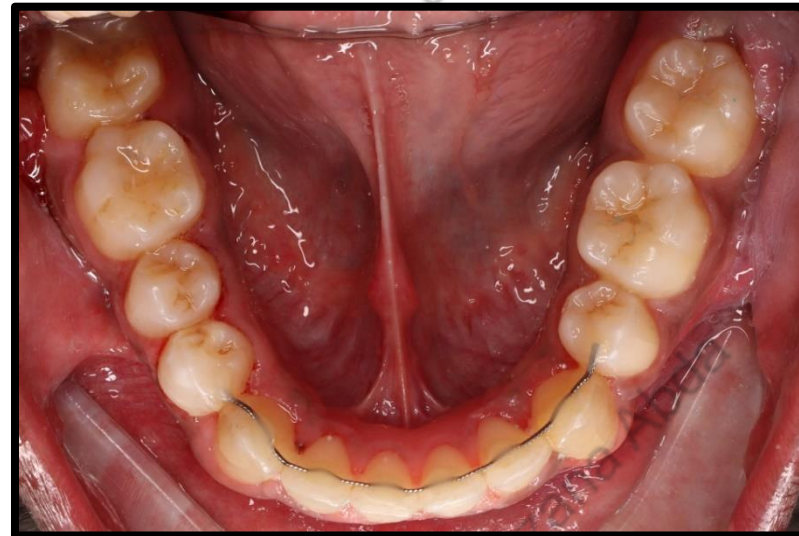
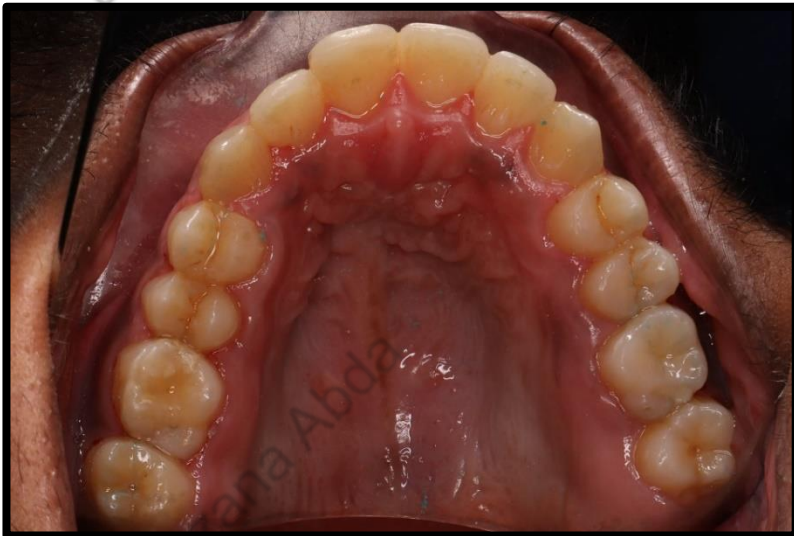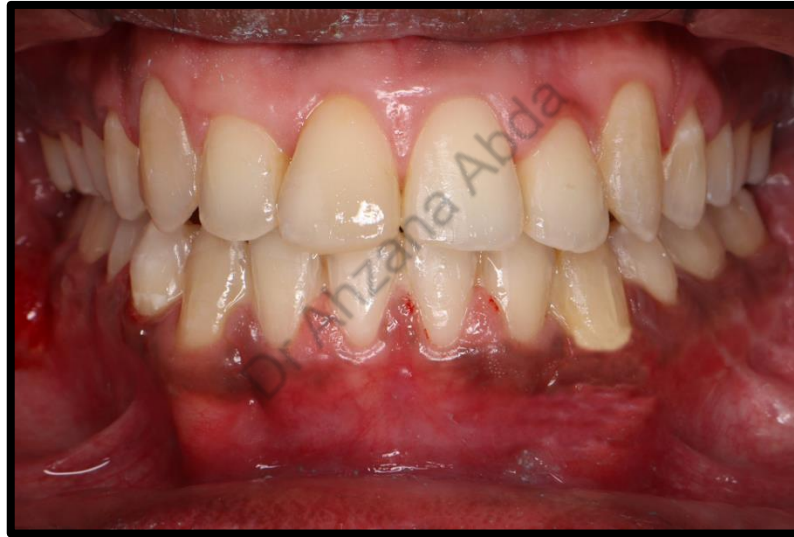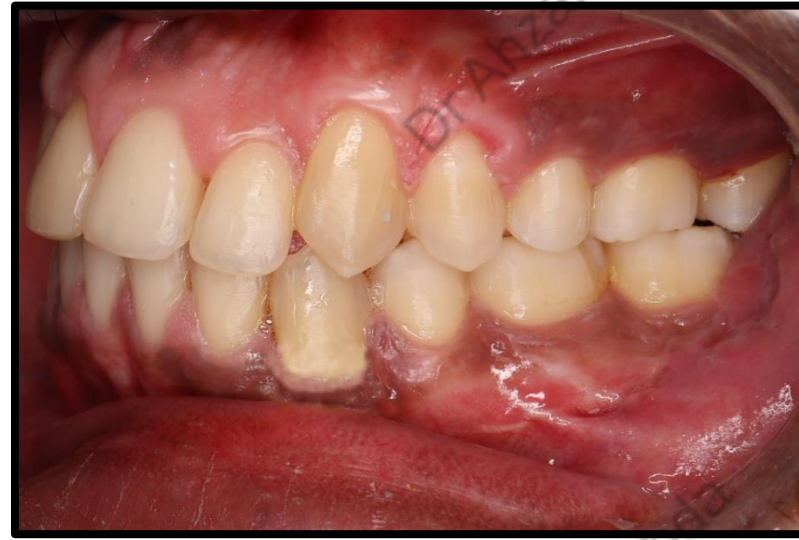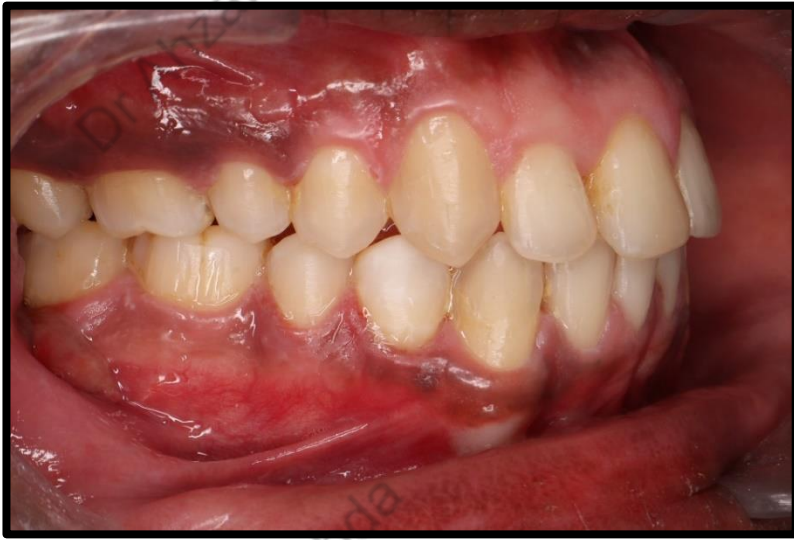**POST SURGERY OPG**



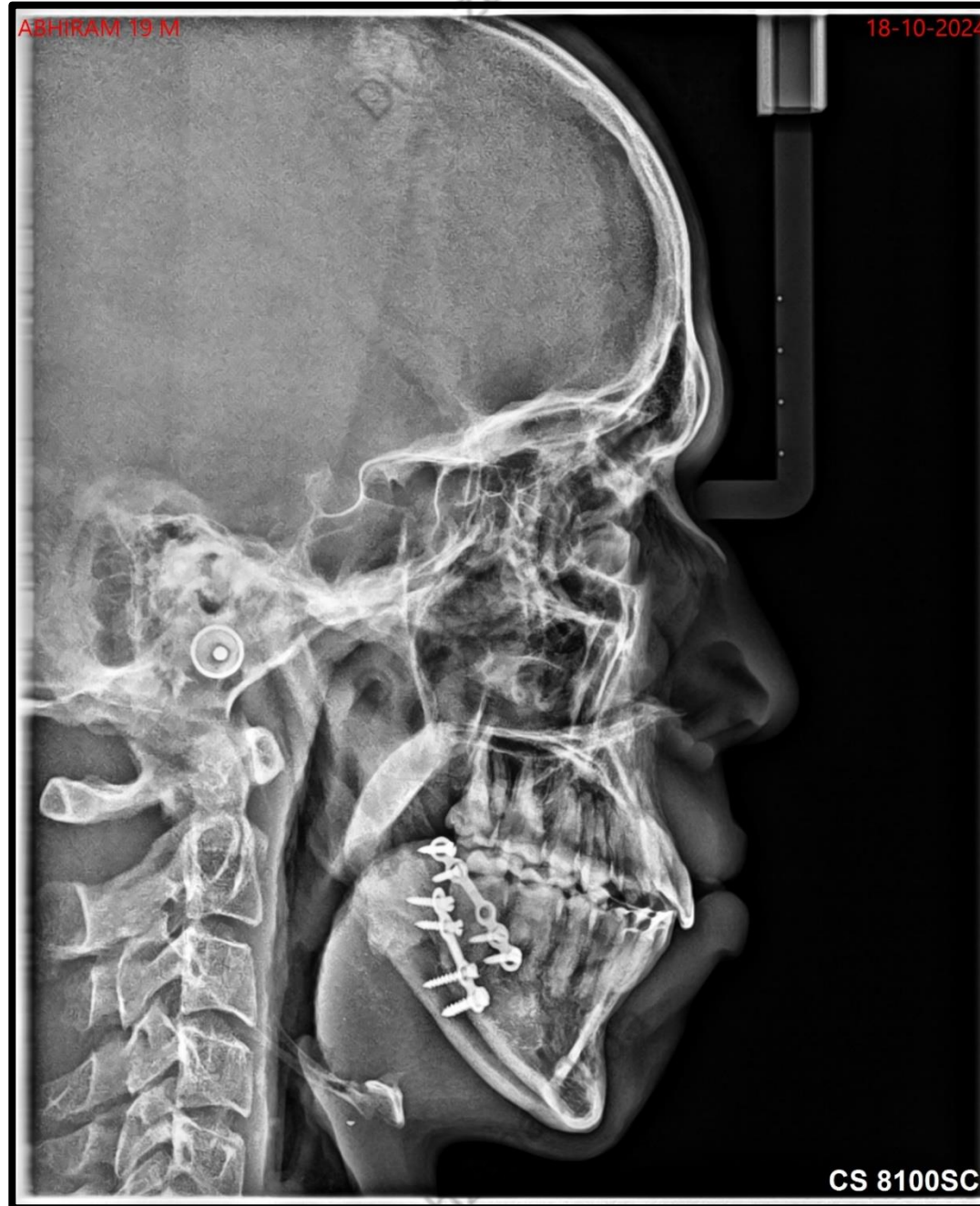**POST -EXTRA ORAL**



# POST -INTRA ORAL



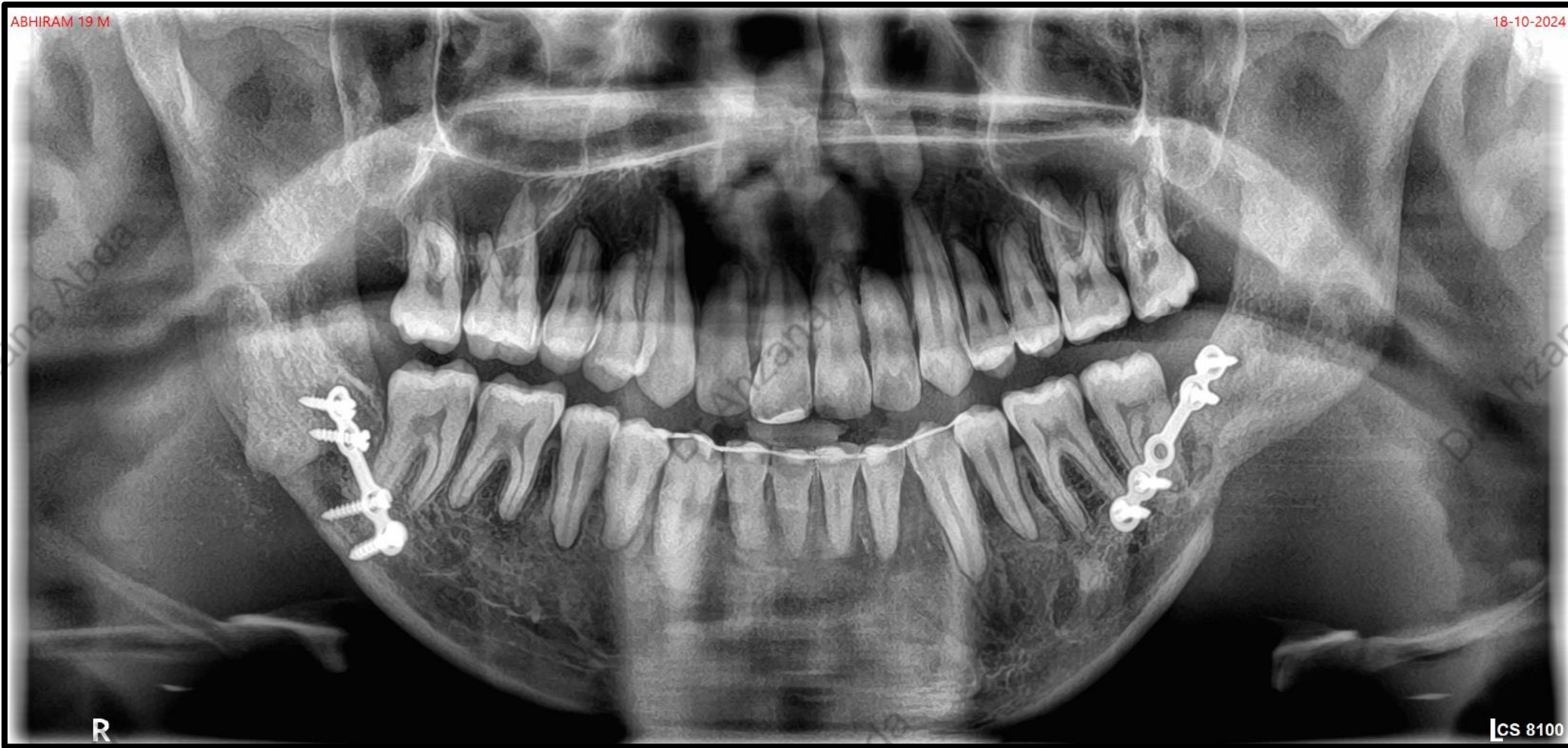# LATERAL CEPH



# OPG

ABHIRAM 19 M

18-10-2024



R

CS 8100



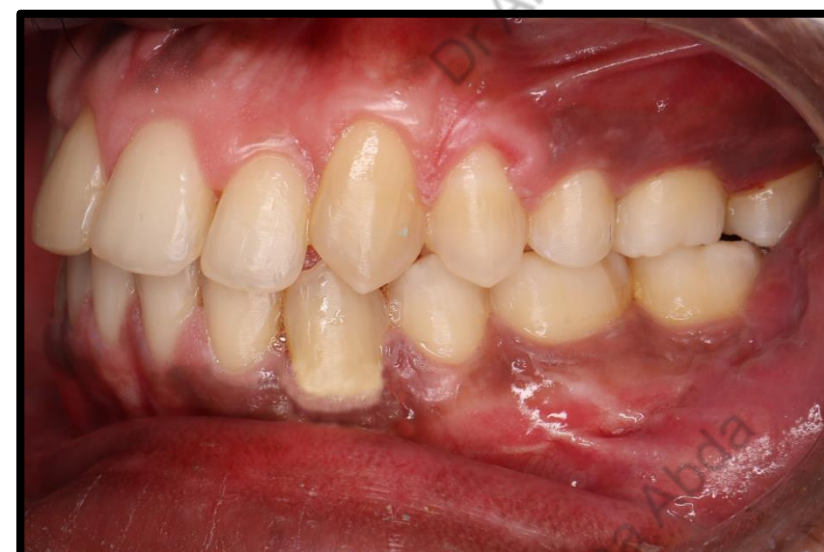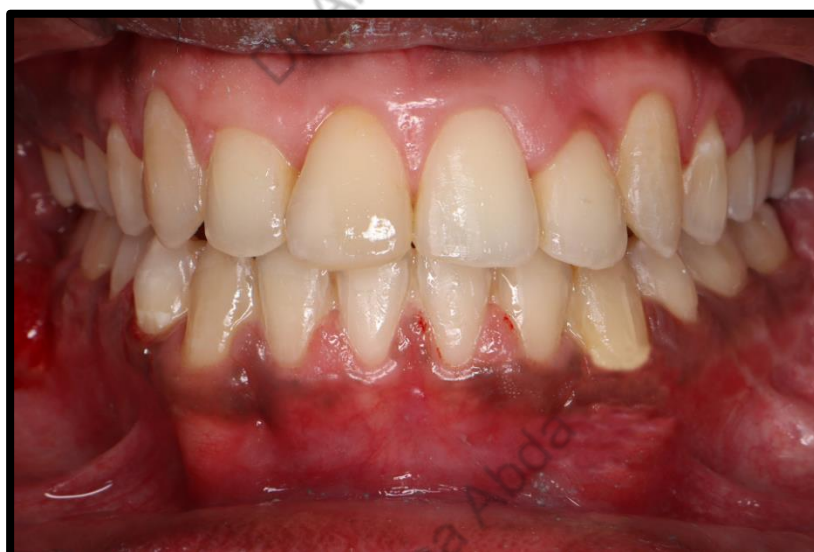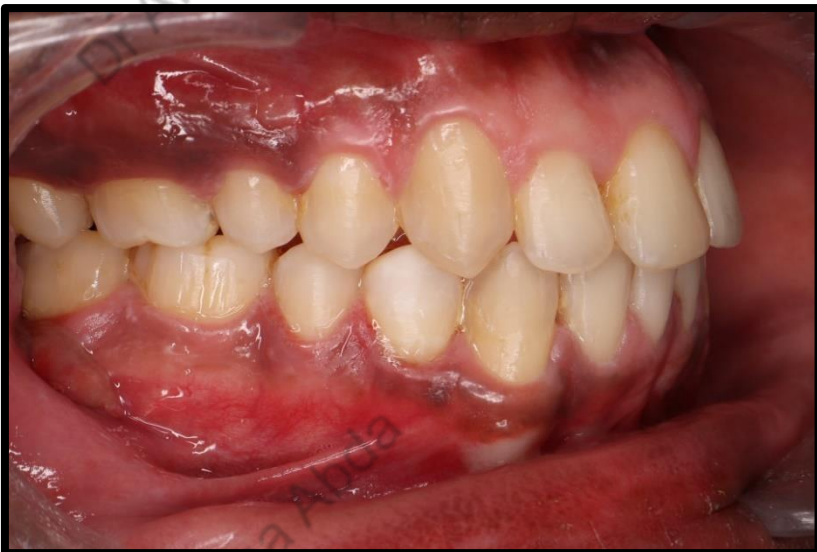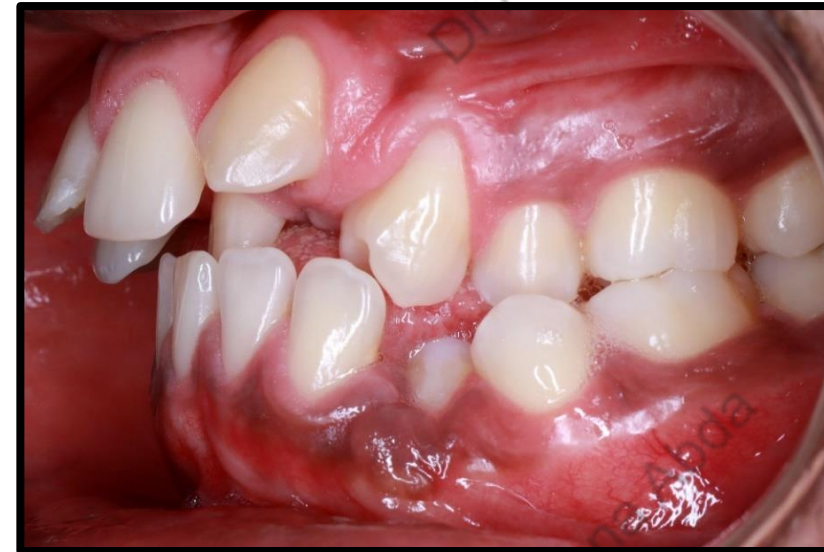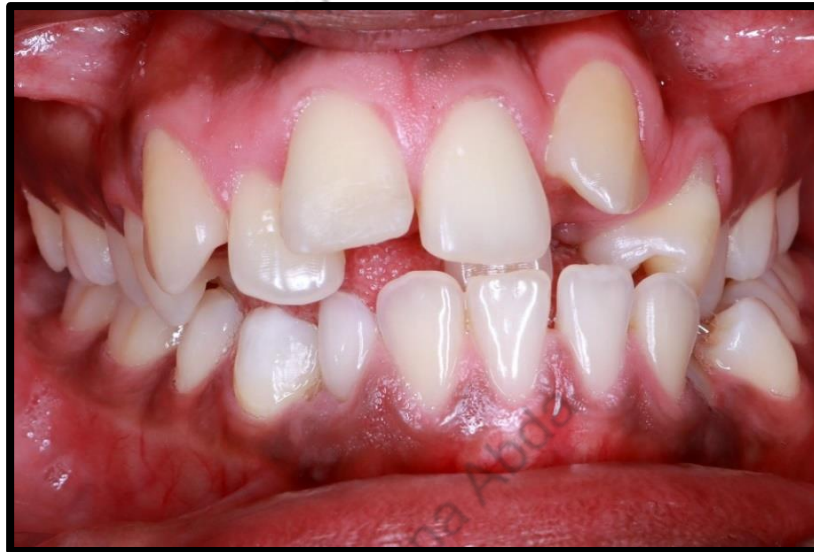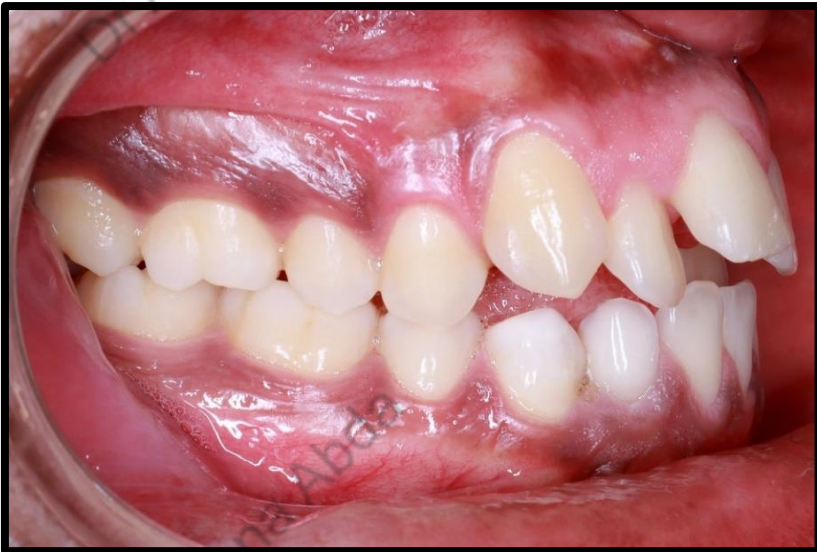**PRE-TREATMENT**



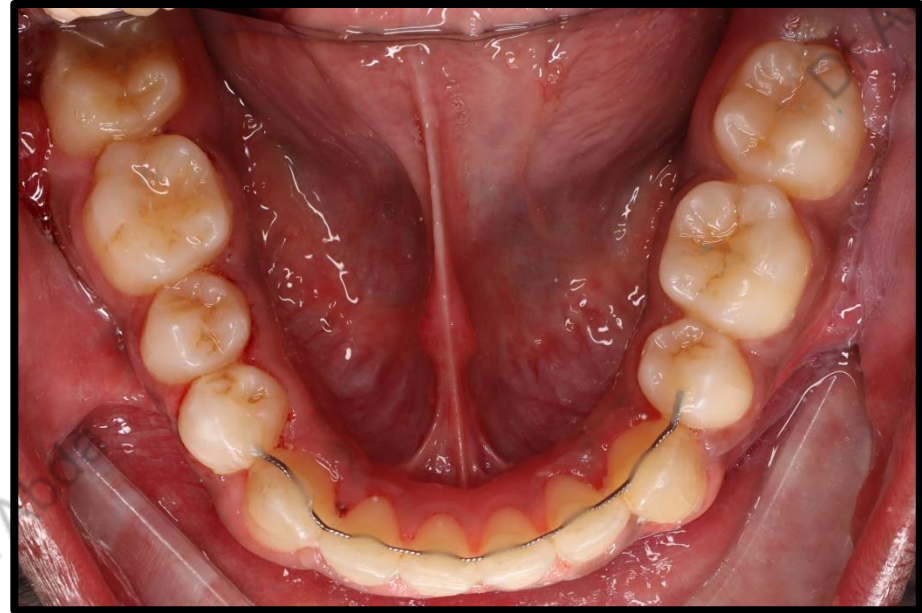
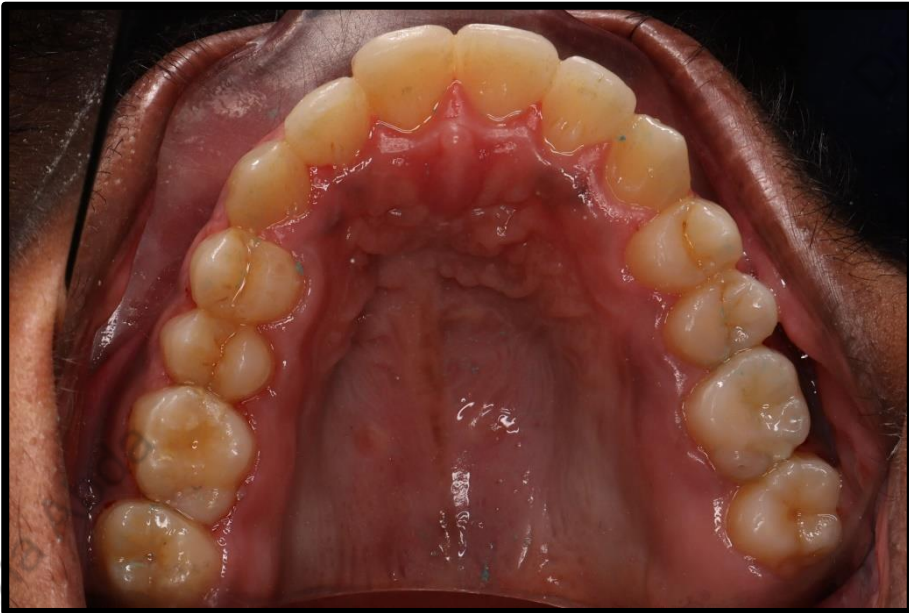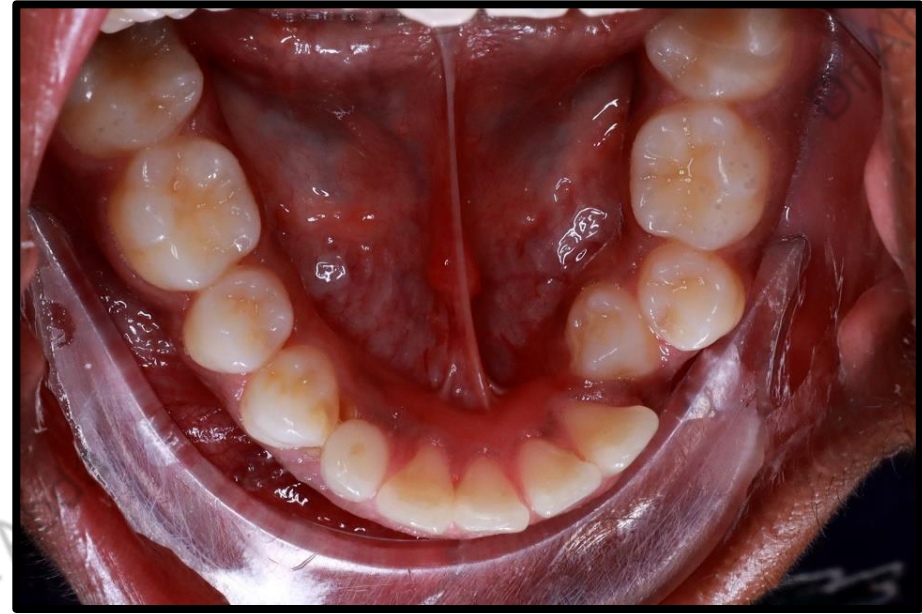
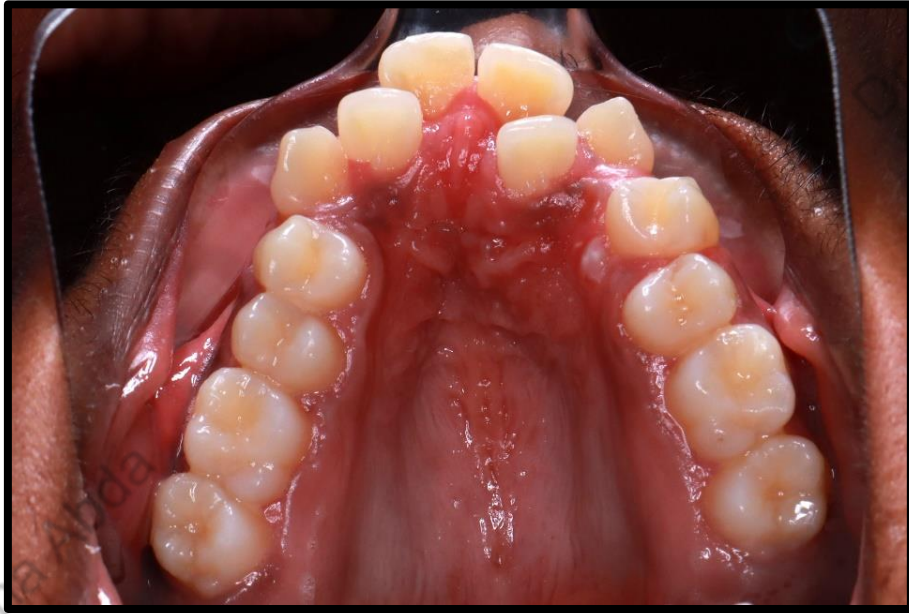
**POST-TREATMENT**



# INTRA ORAL COMPARISON



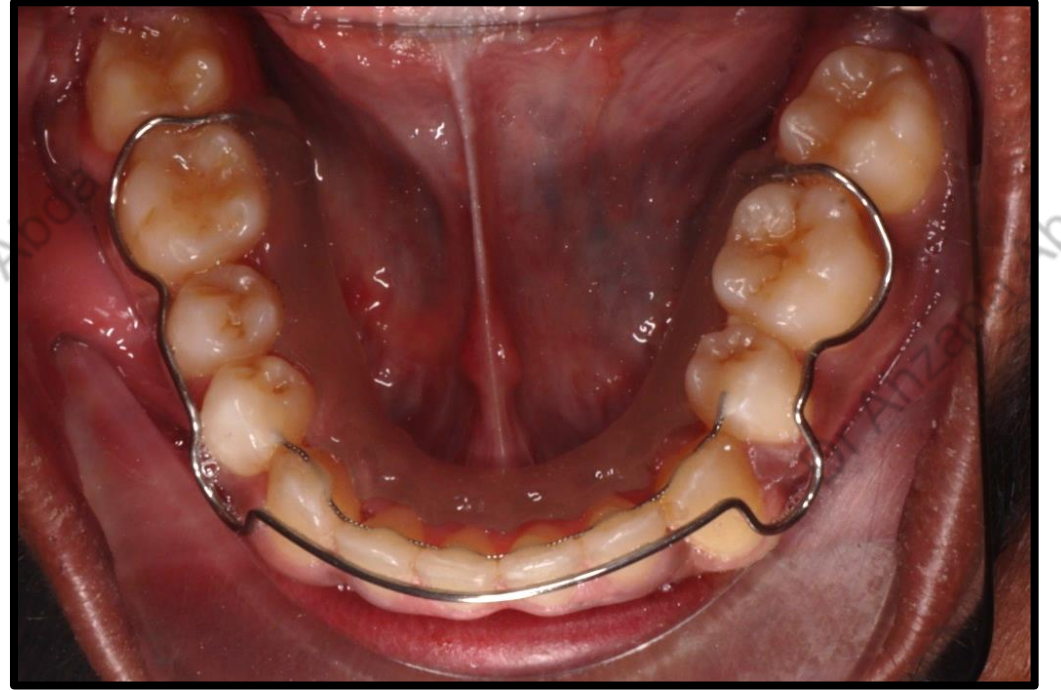
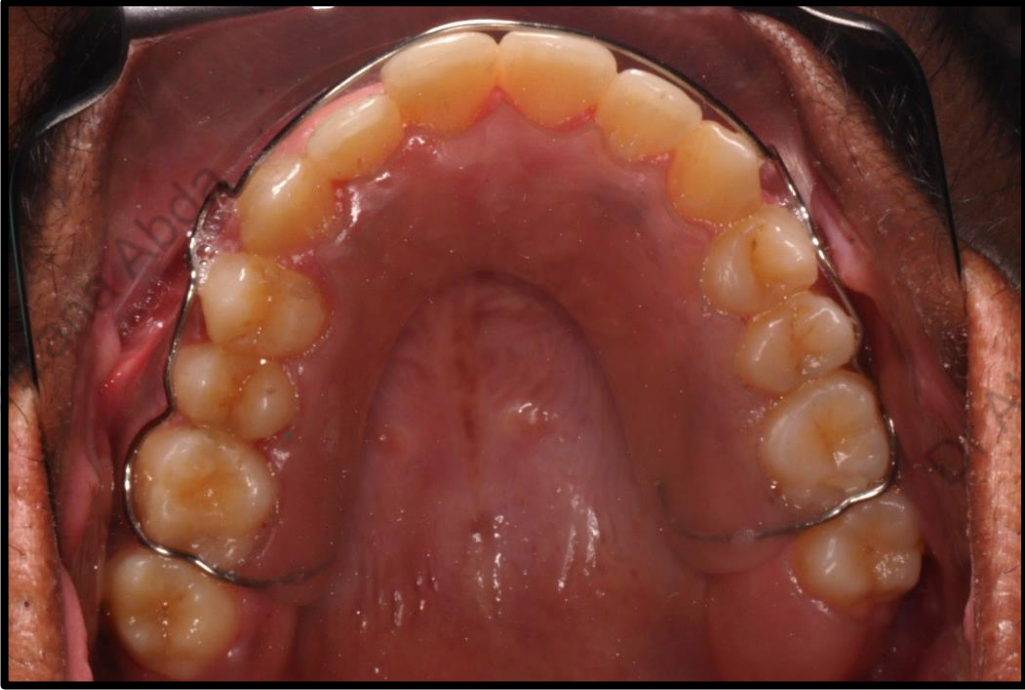# INTRA ORAL COMPARISON



Dr Ahzana A

Dr Ahzana A

Dr Ahzana A



Dr Ahzana A

Dr Ahzana A

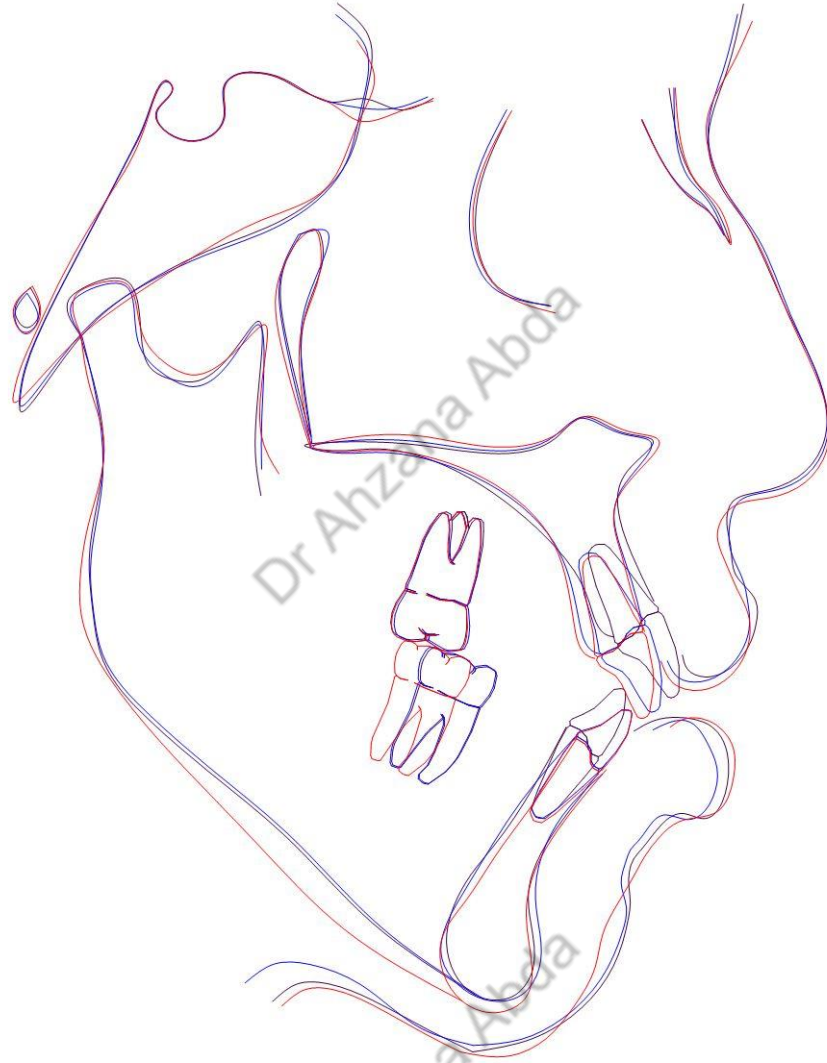
Dr Ahzana A

Dr Ahzana A

Dr Ahzana A

Dr Ahzana A

# SUPERIMPOSITION



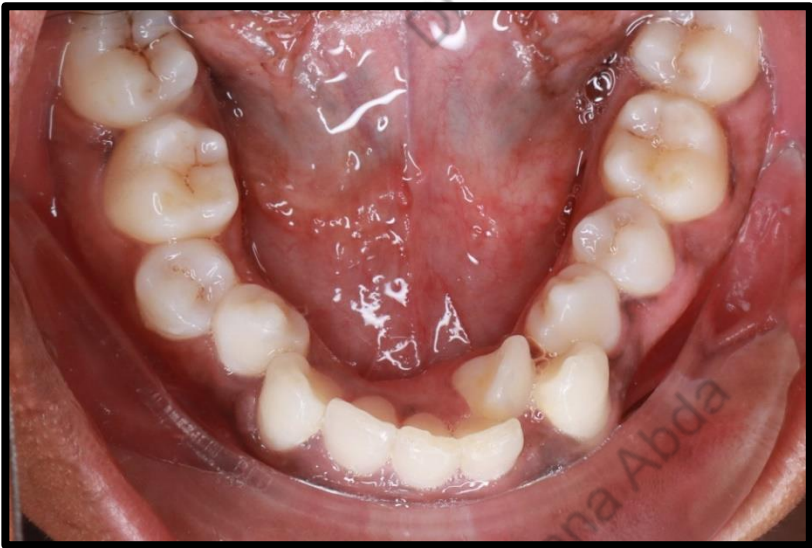
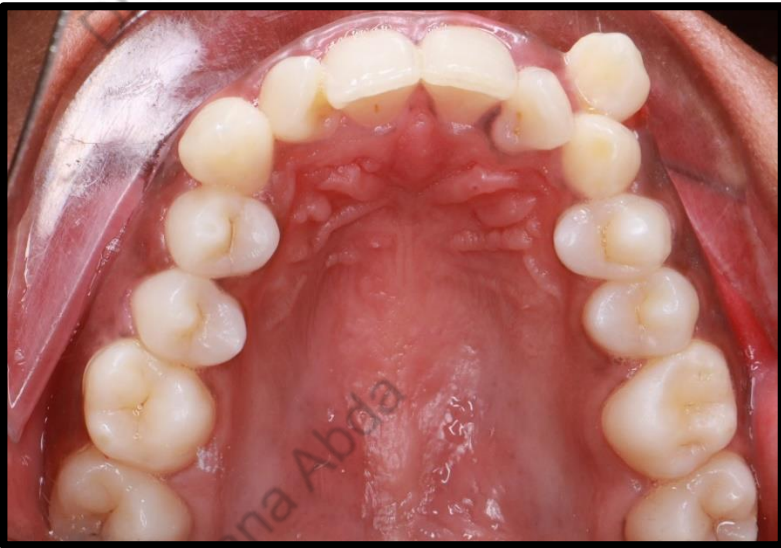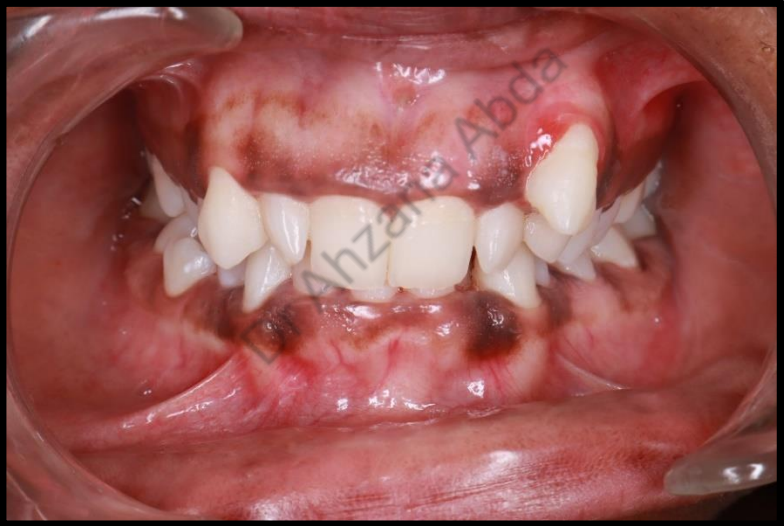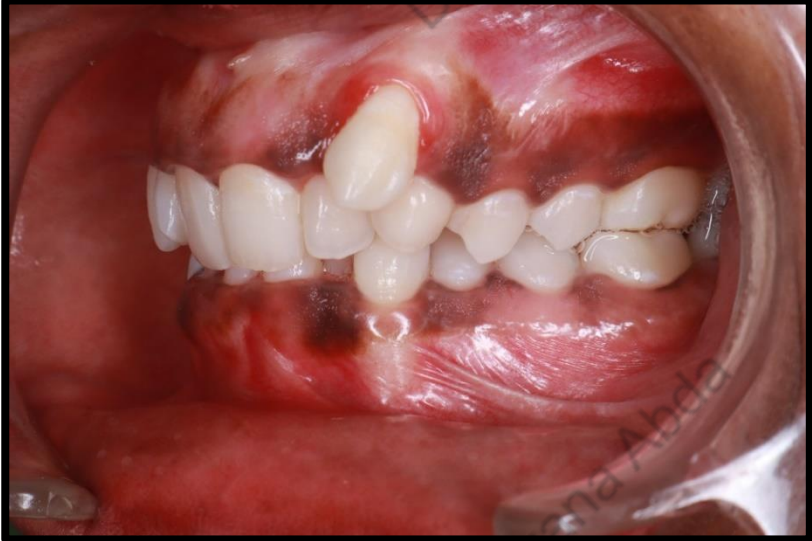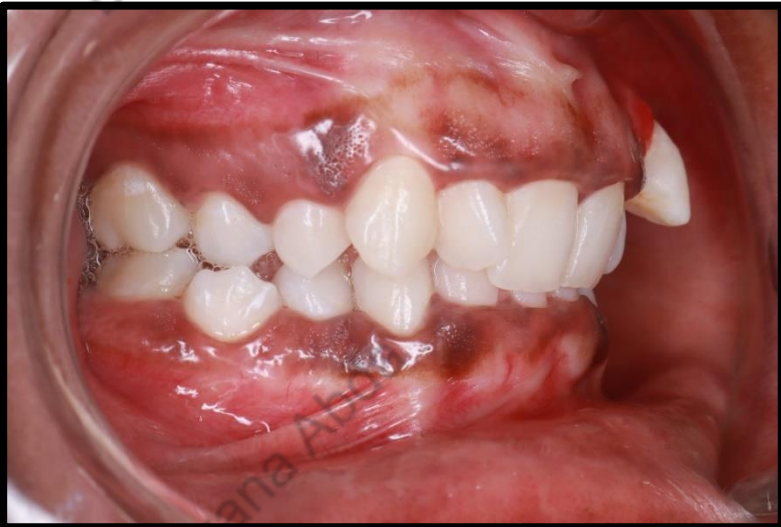# CASE VI

**PUSHPA 22/ F**

# PRE TREATMENT EXTRAORAL

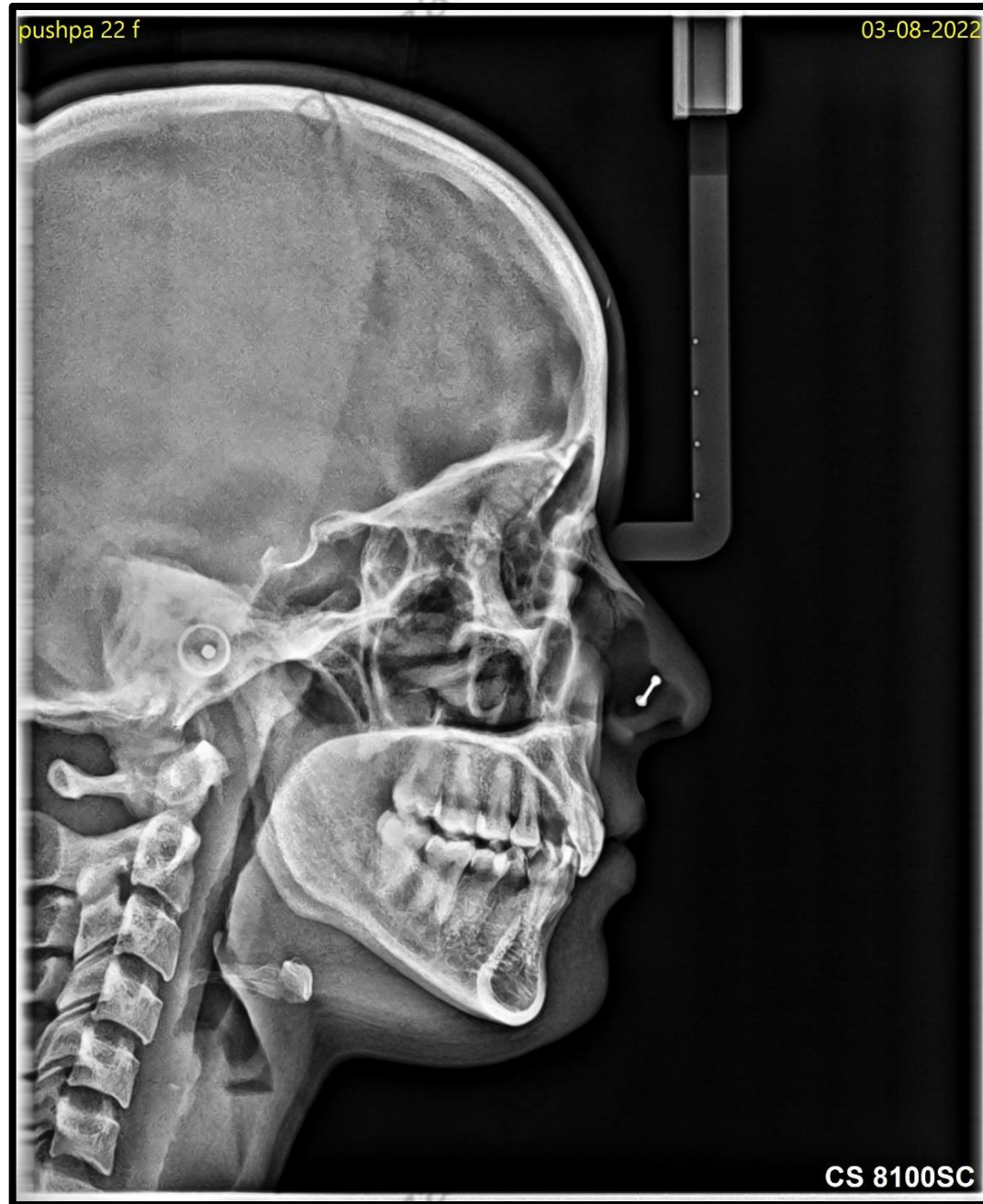

**PRE TREATMENT INTRAORAL**



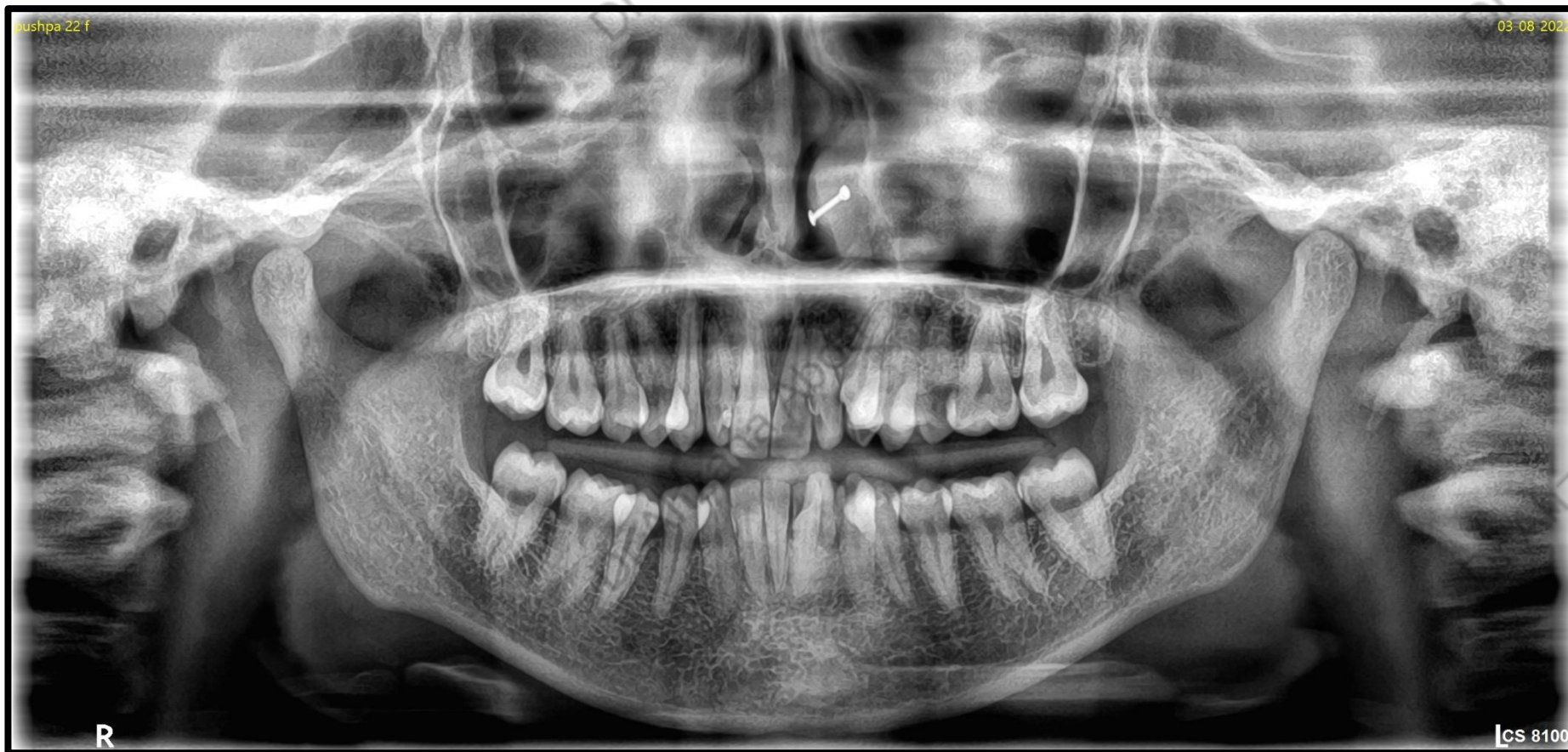Dr Ahzana Abda

# PRE TREATMENT LATERAL CEPHALOGRAM



CS 8100SC

# PRE TREATMENT OPG



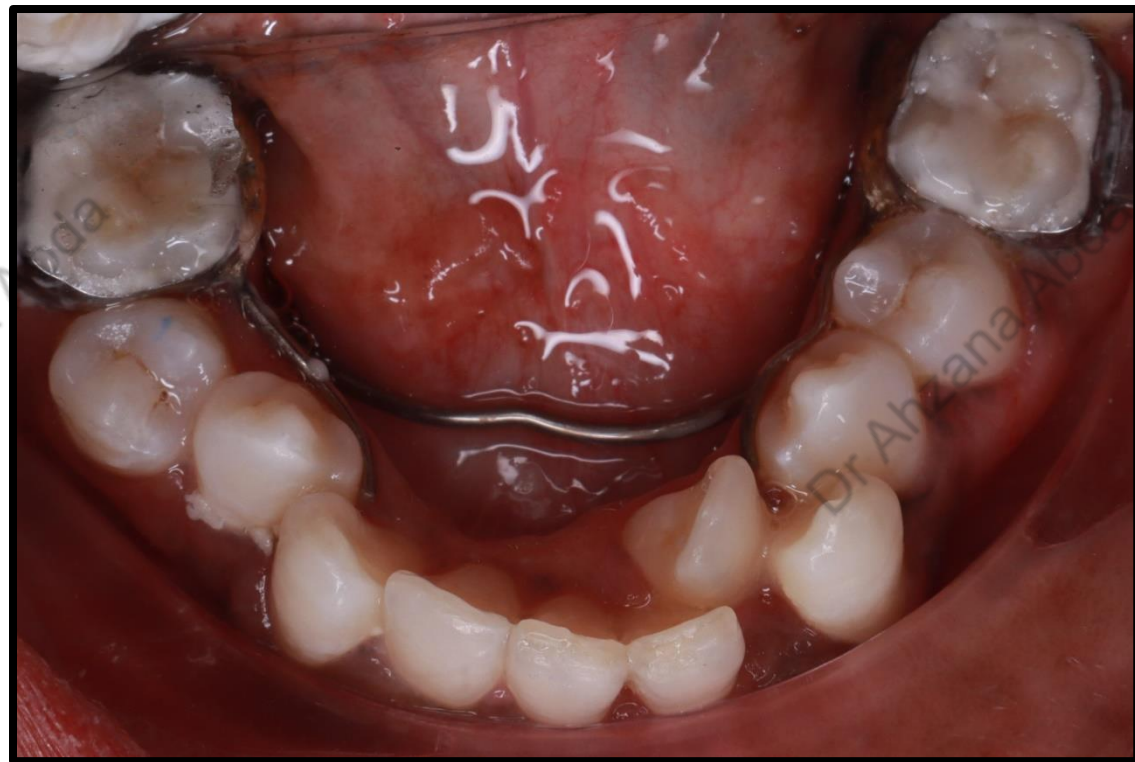
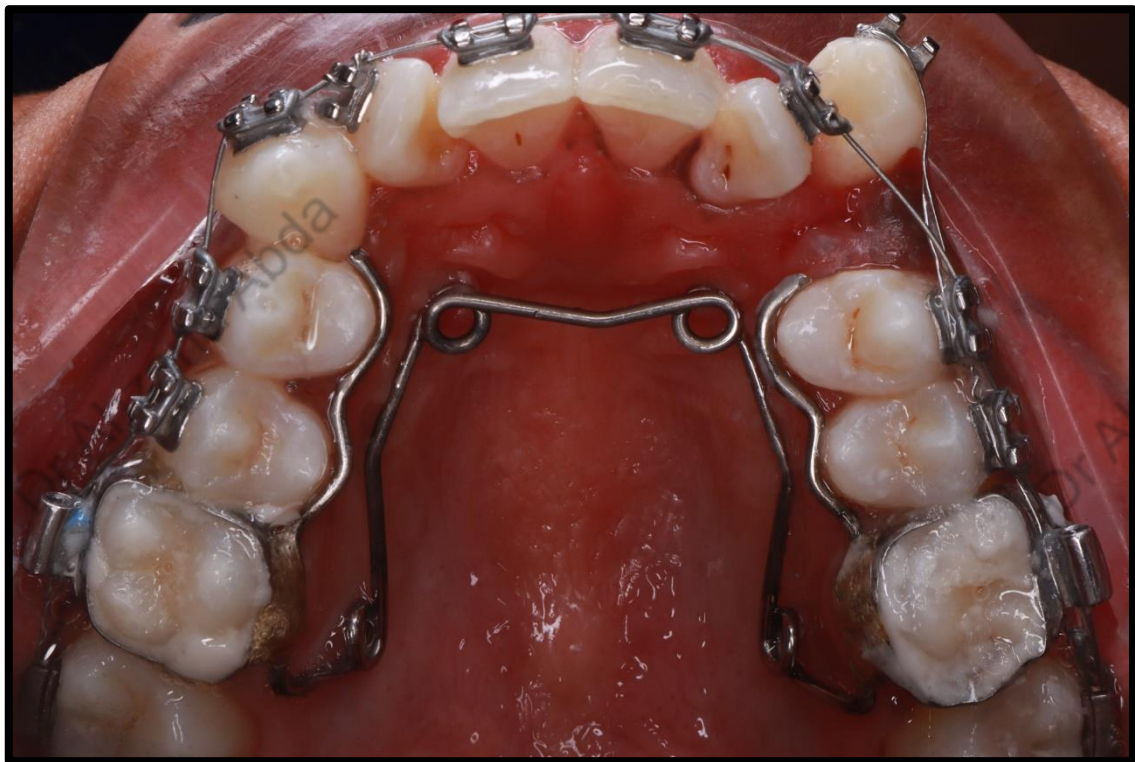
## **DIAGNOSIS**

- Class II Skeletal Pattern
- Angle's Class II Malocclusion with bidental retroclination
- Vertical Growth Pattern

## **TREATMENT PLAN**

- Extraction of 63
- Arch expansion with quad helix and bihelix
- Upper anterior intrusion using TADS
- Distalization of upper arch using IZC screws

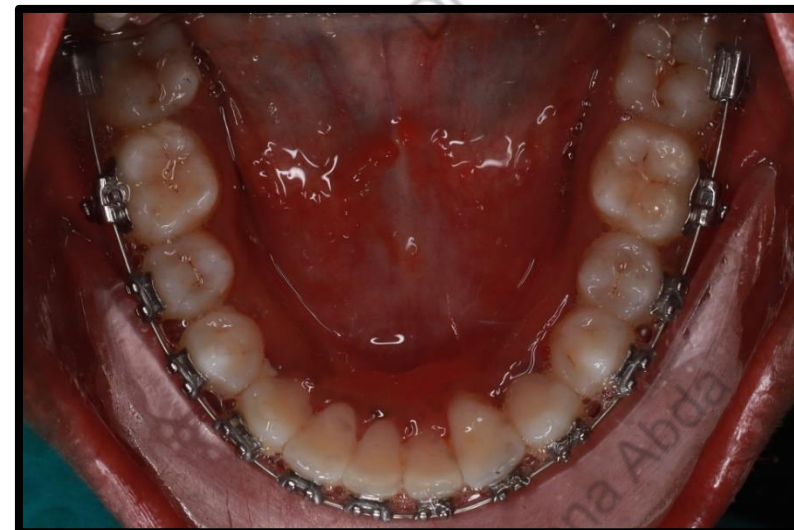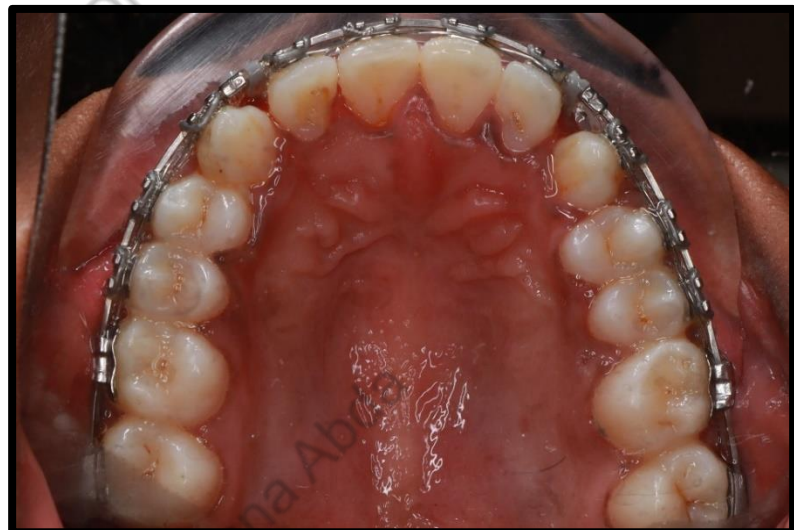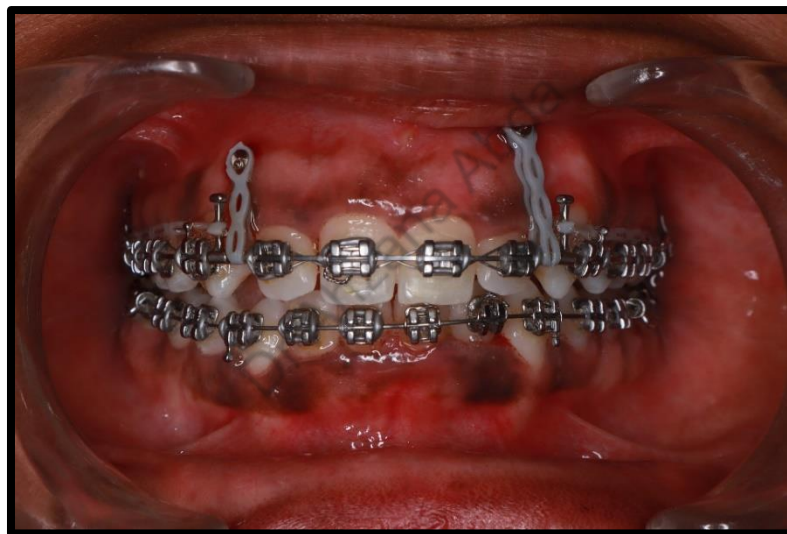
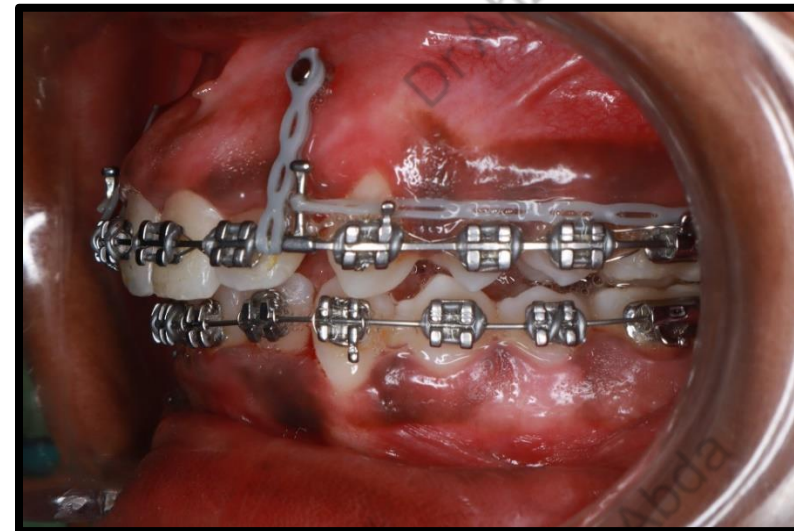
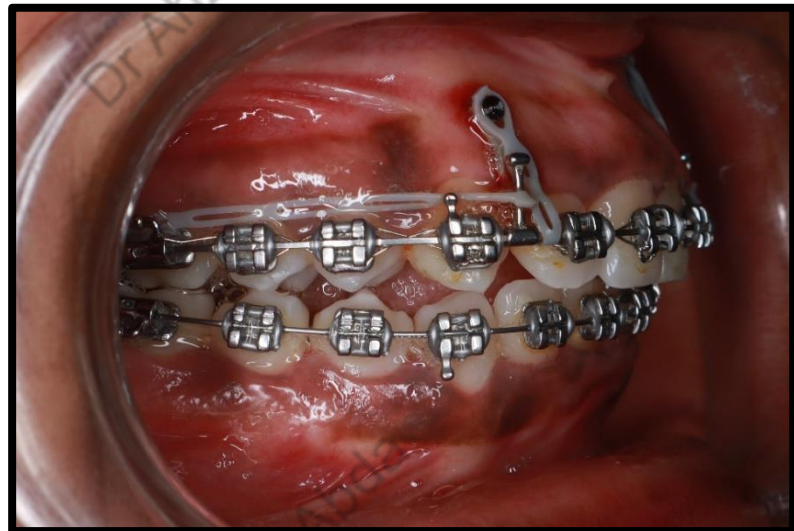
# ARCH EXPANSION



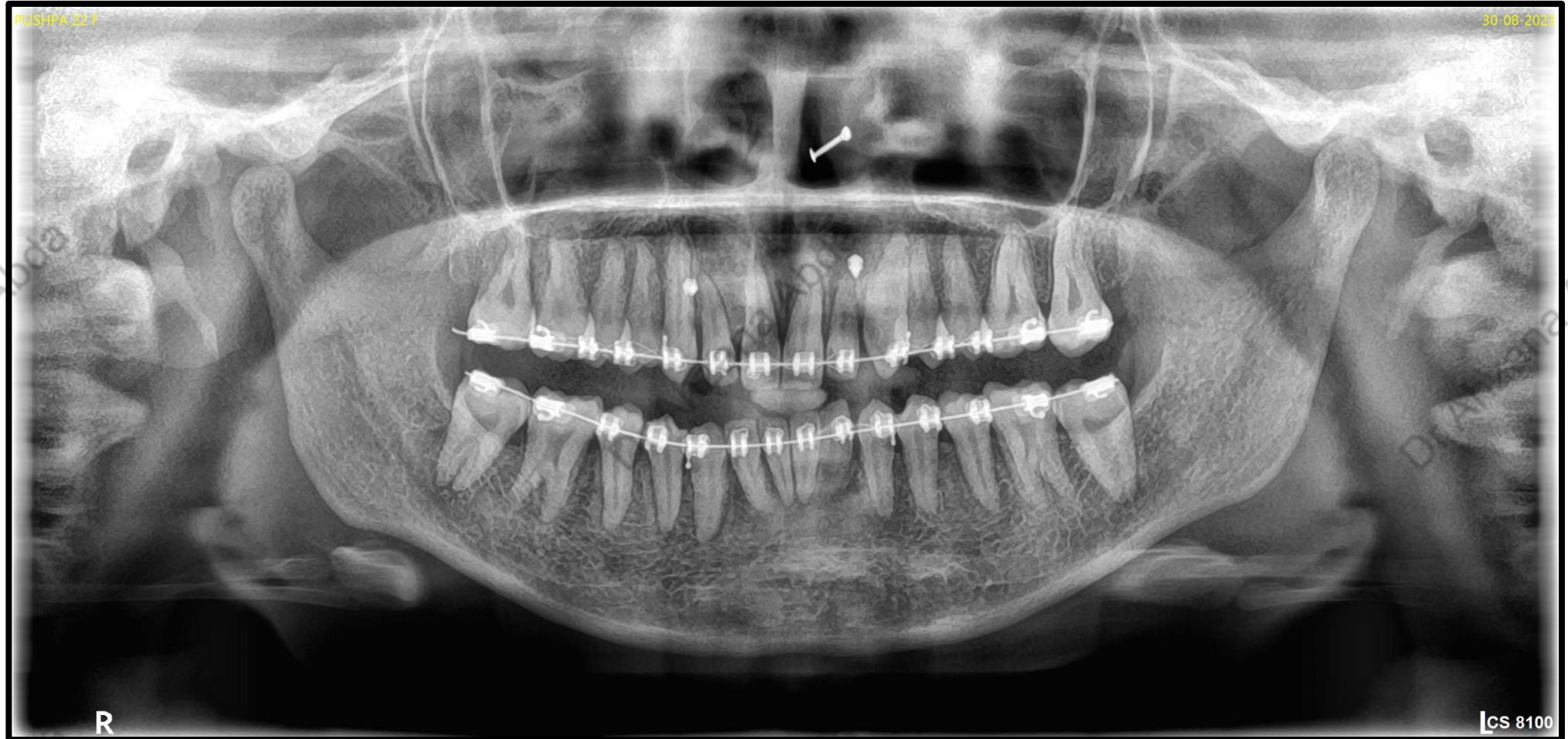# MID TREATMENT EXTRA ORAL



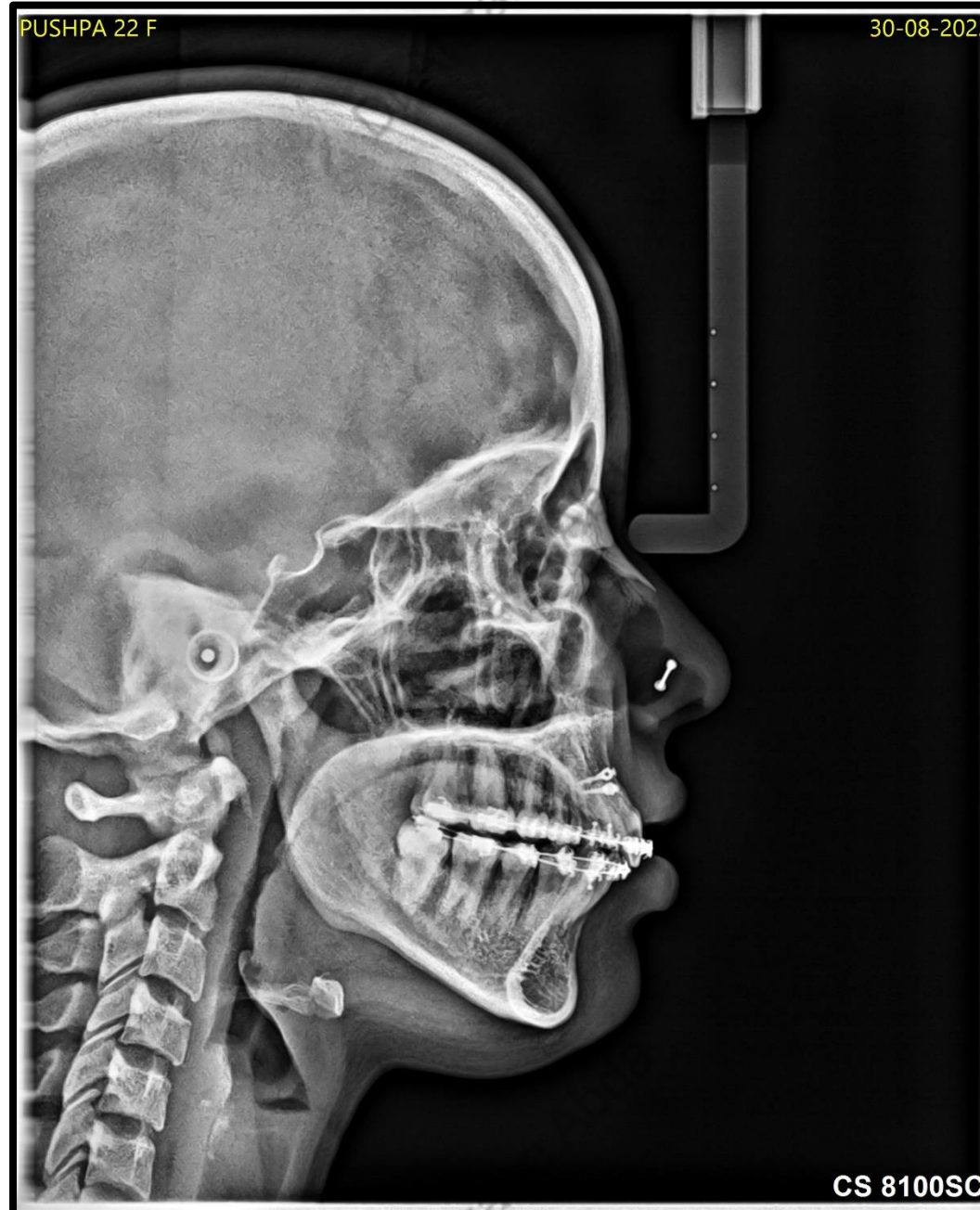# MID TREATMENT INTRA ORAL



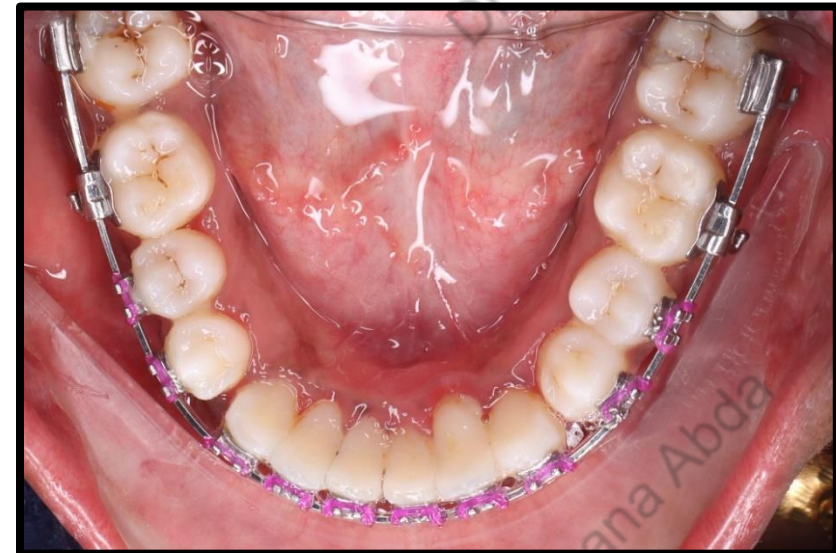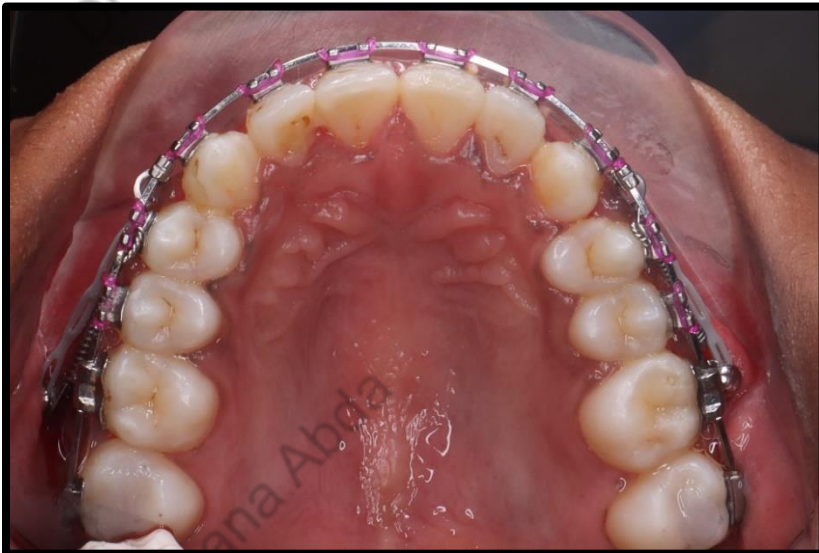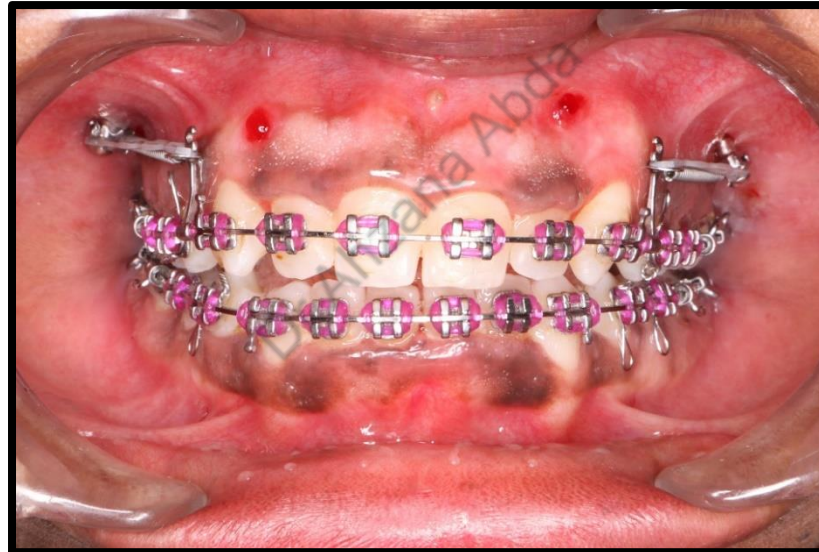
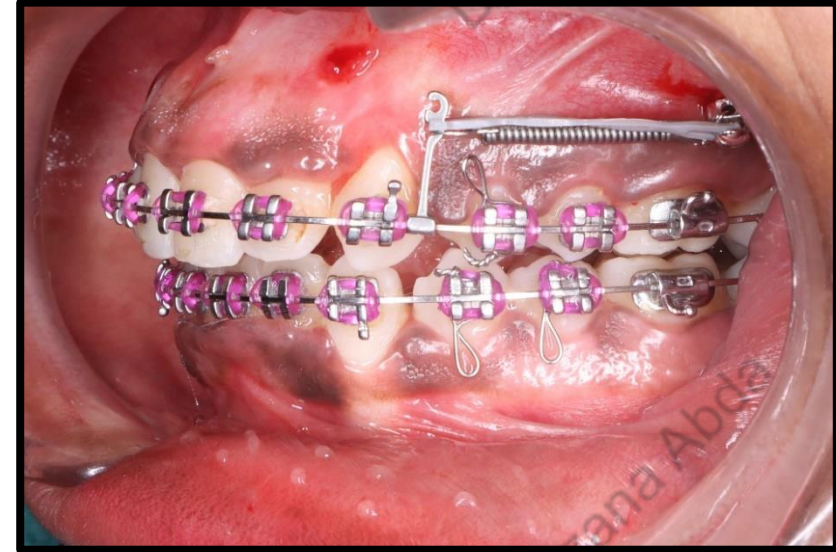
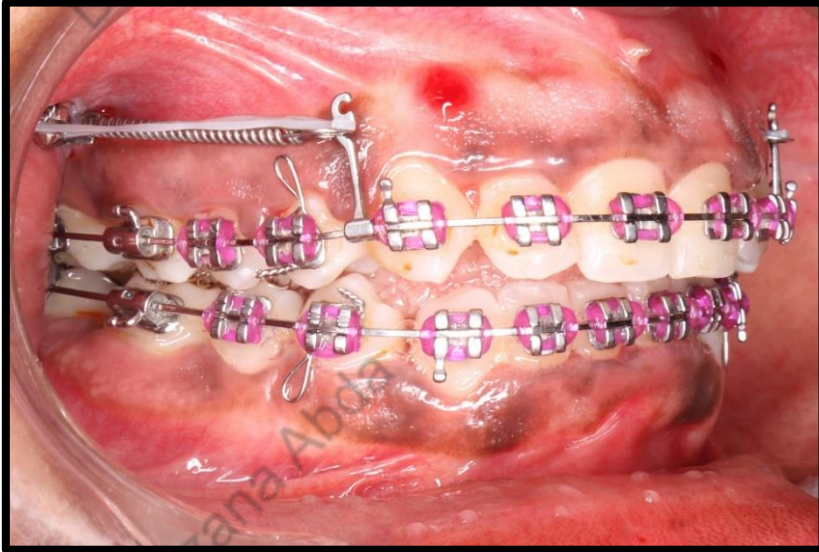
# MID TREATMENT OPG



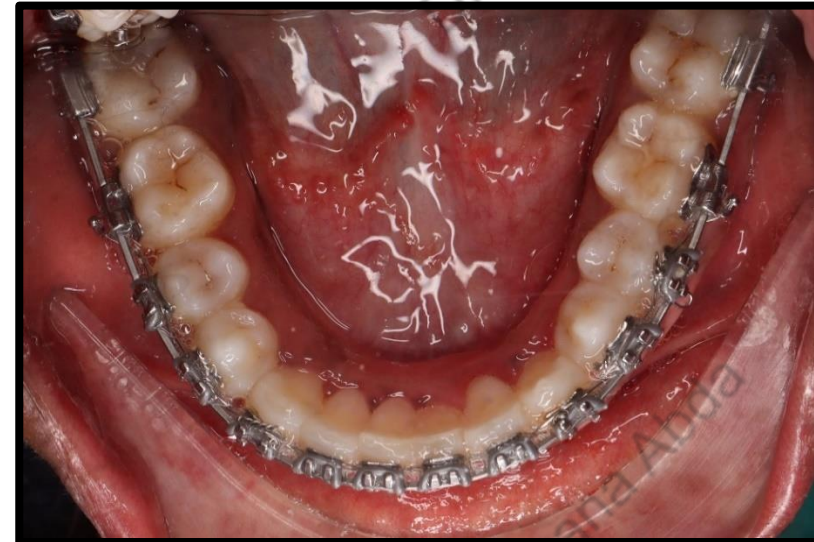
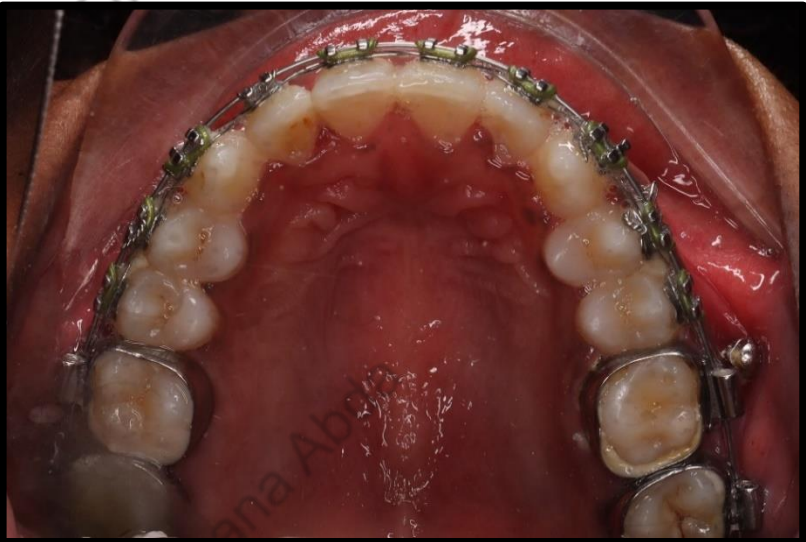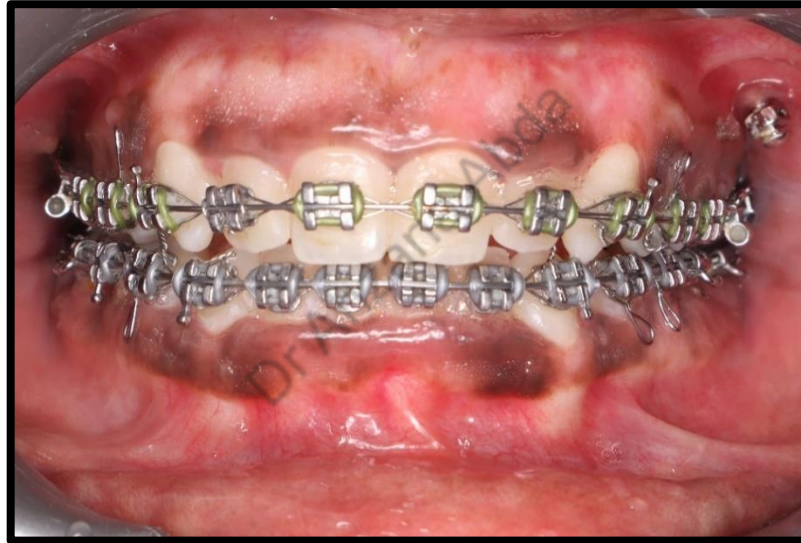
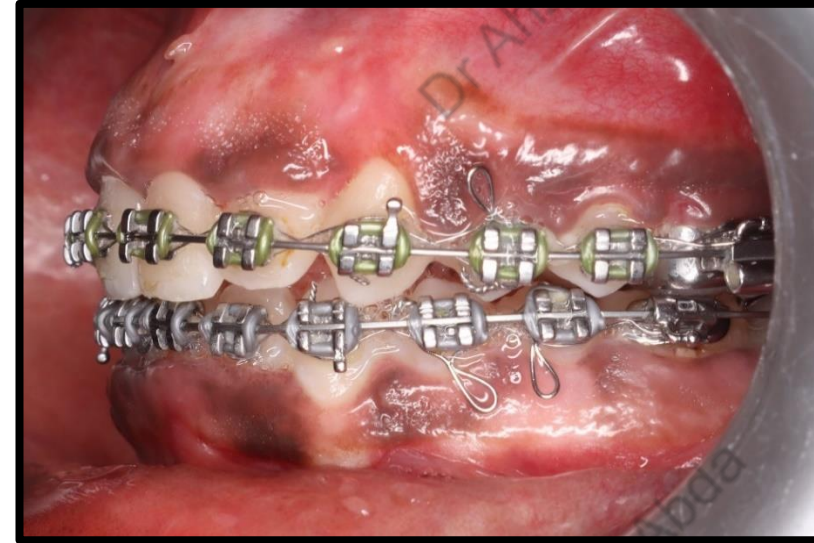
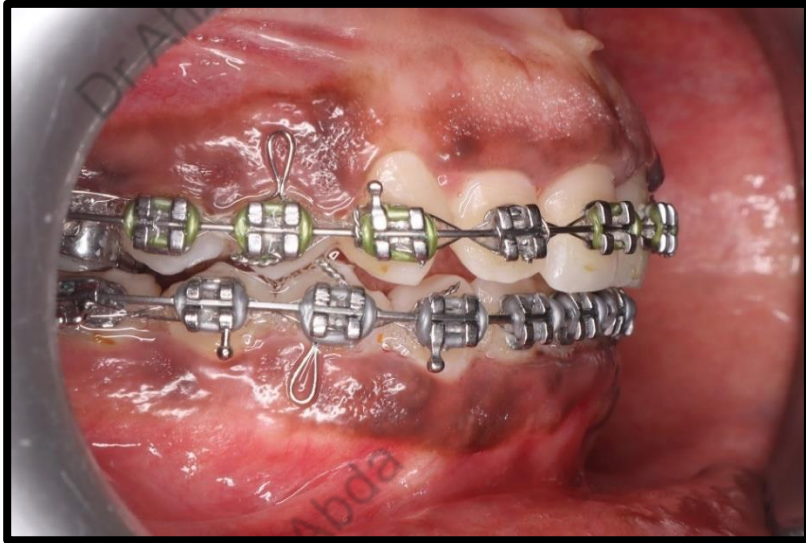# MID TREATMENT LATERAL CEPHALOGRAM



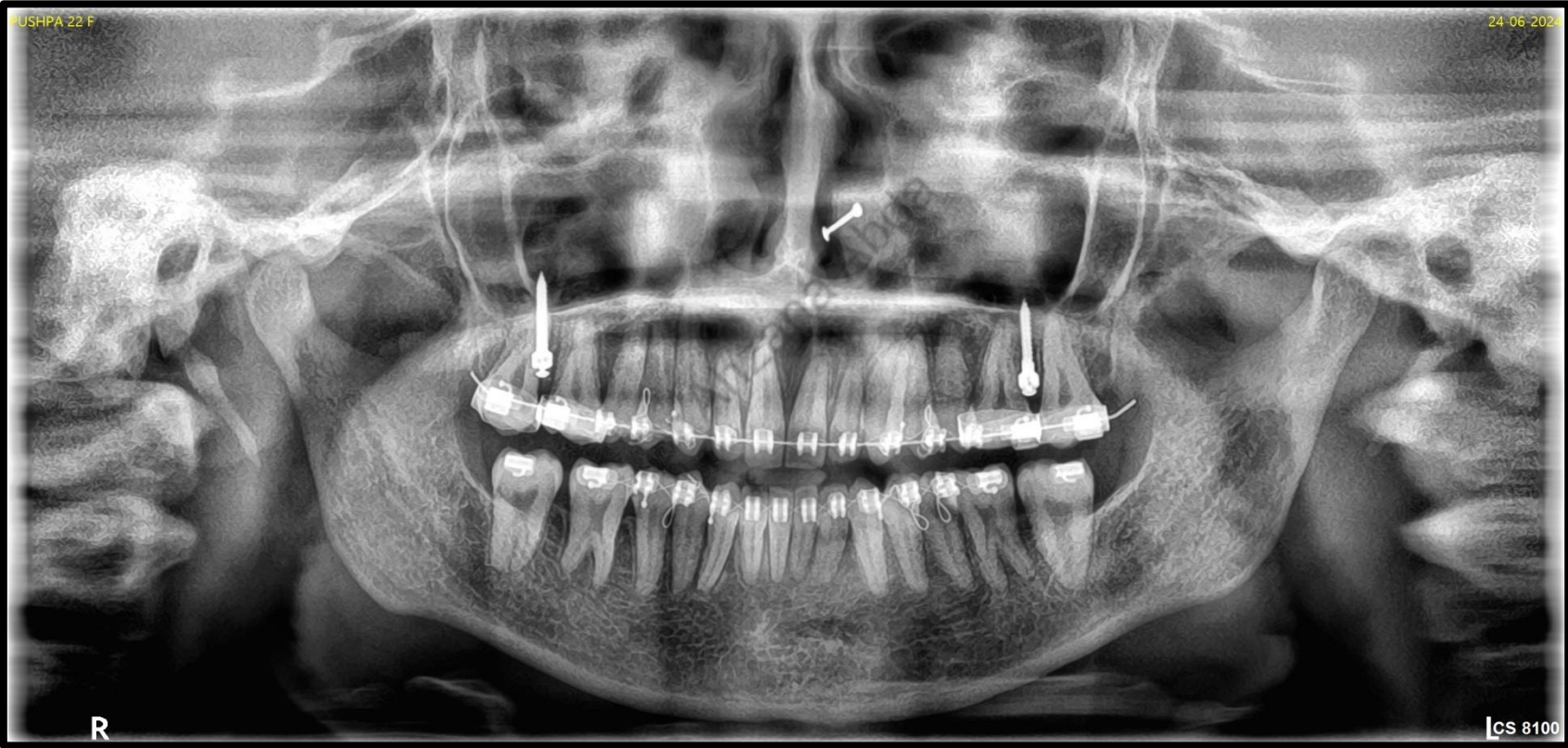# IZC FOR DISTALIZATION



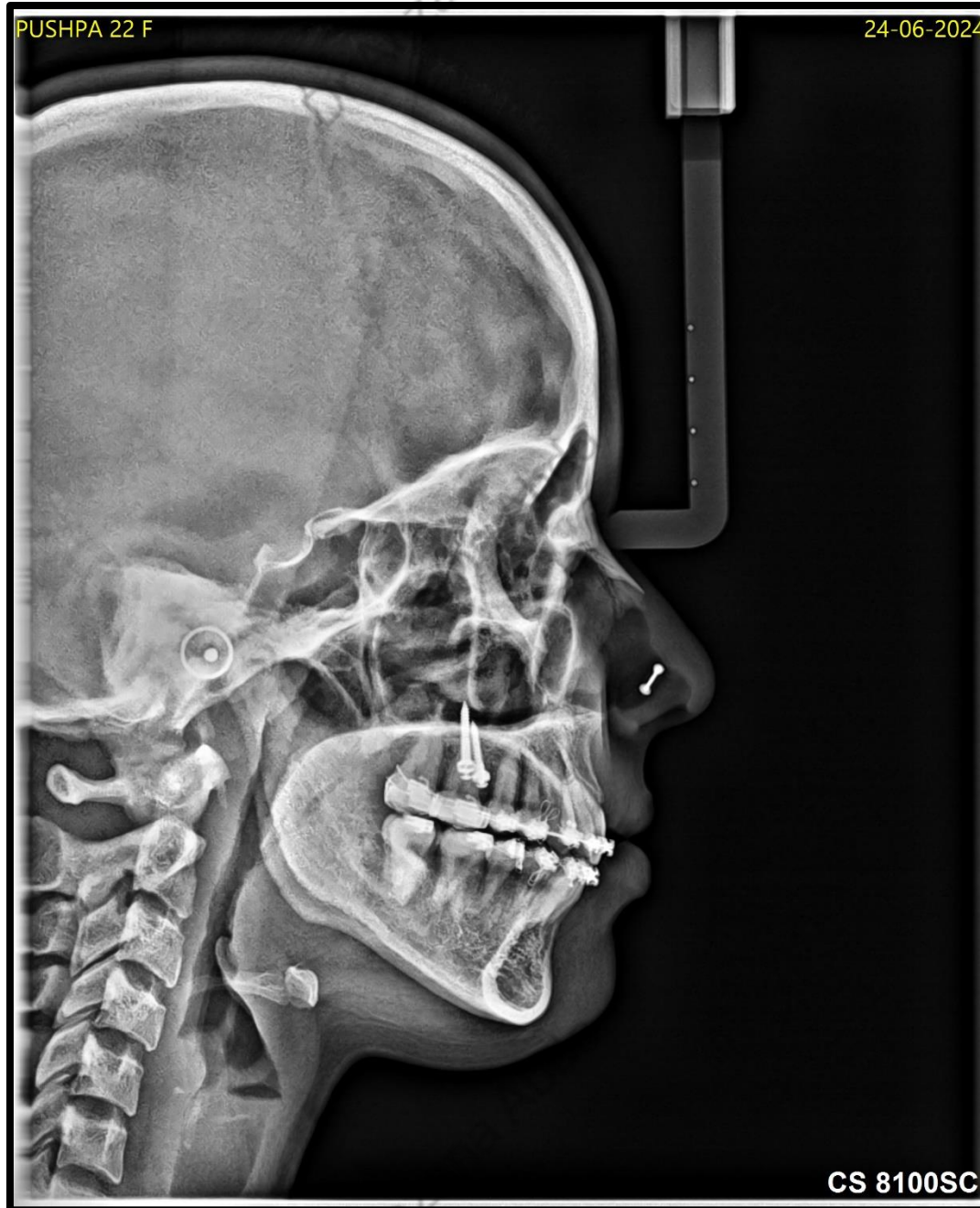
# POST DISTALIZATION INTRA ORAL



# POST DISTALIZATION OPG



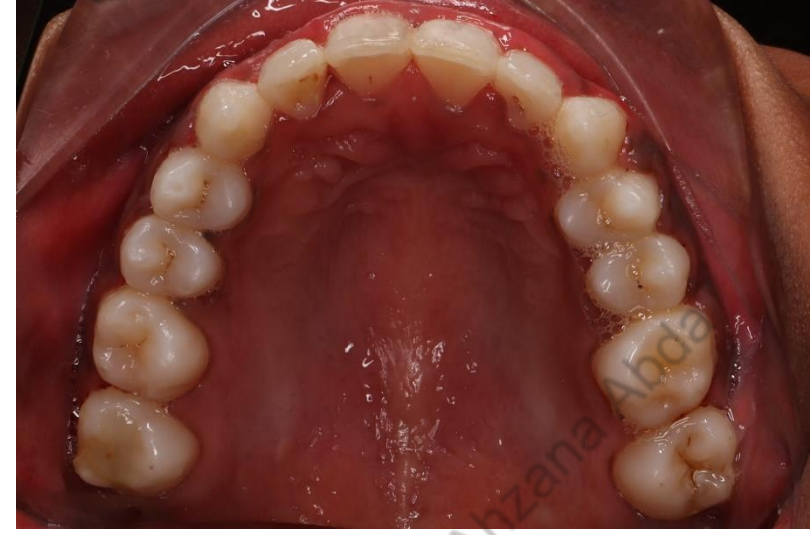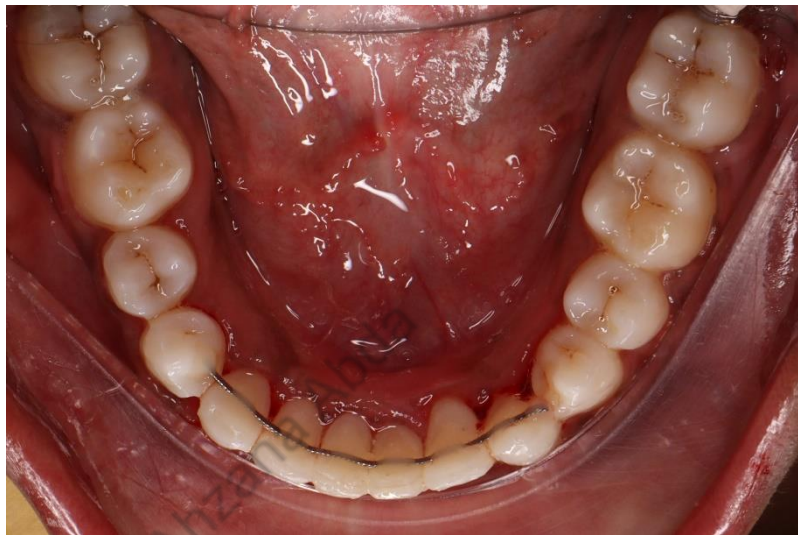
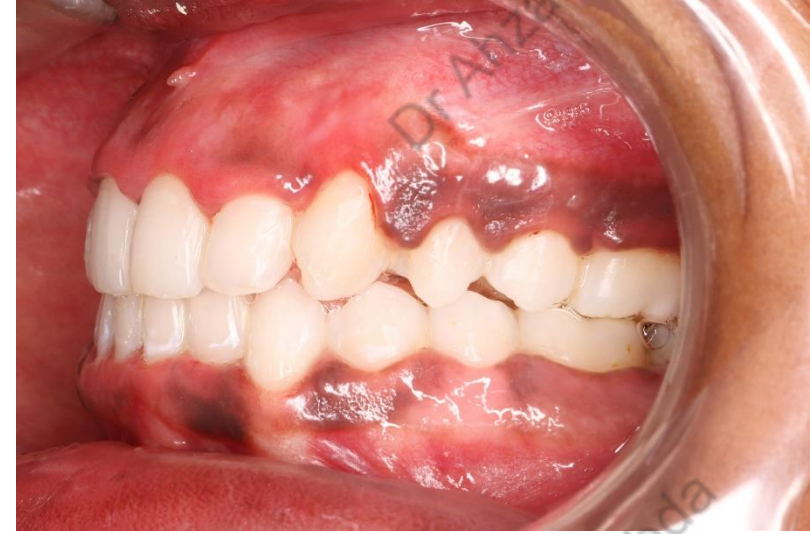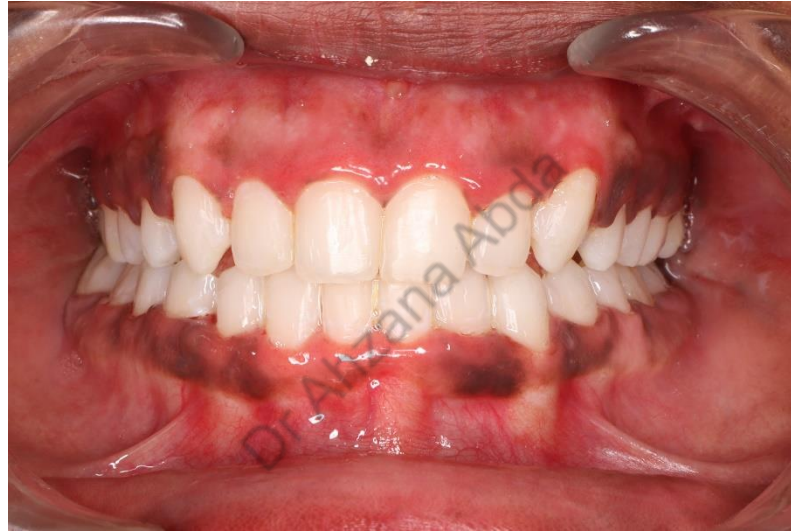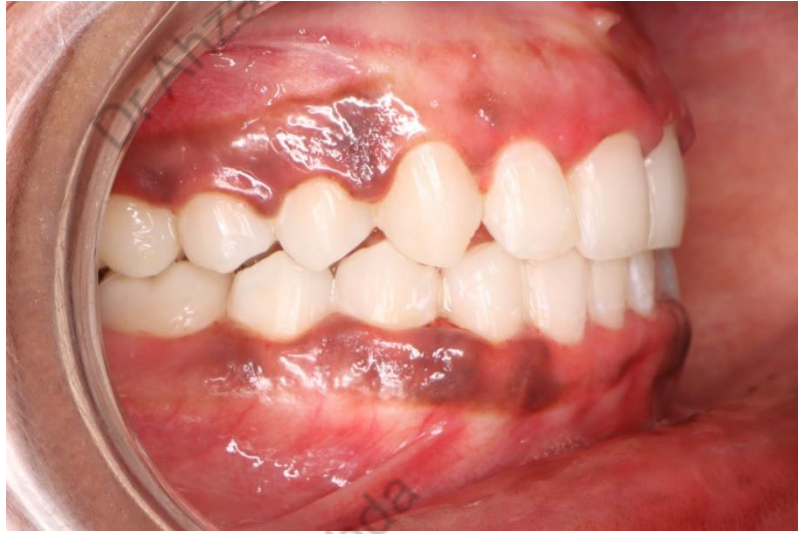# POST DISTALIZATION LATERAL CEPHALOGRAM



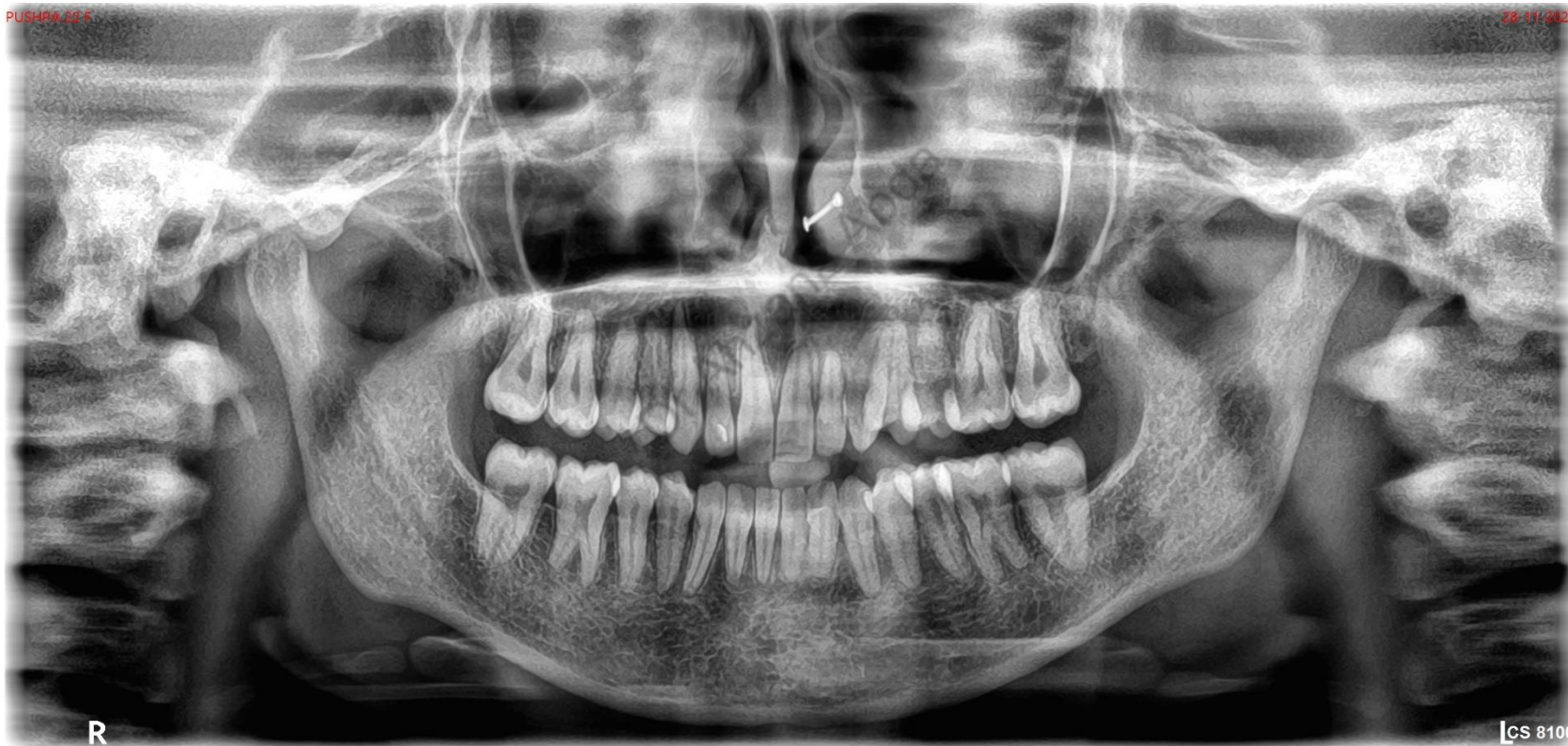**POST TREATMENT EXTRA ORAL**



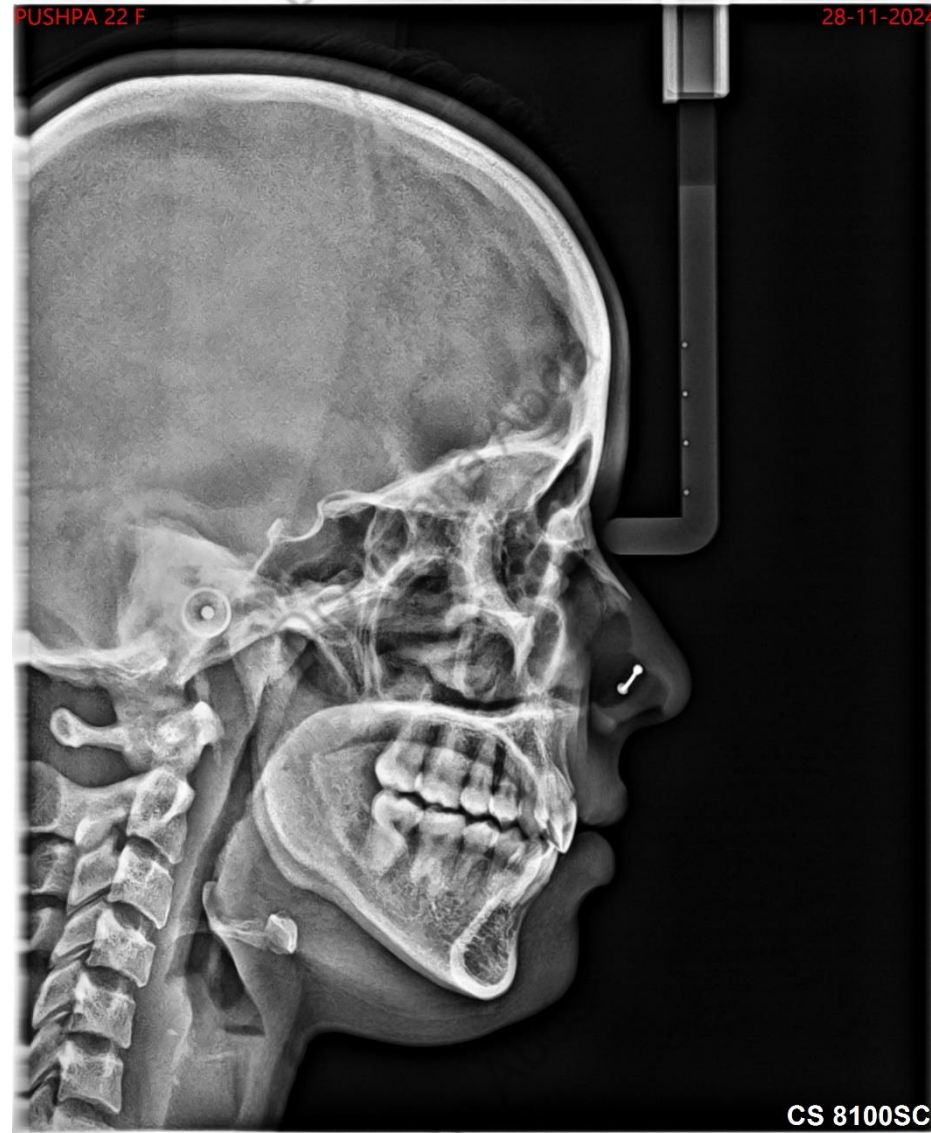# POST TREATMENT INTRA ORAL



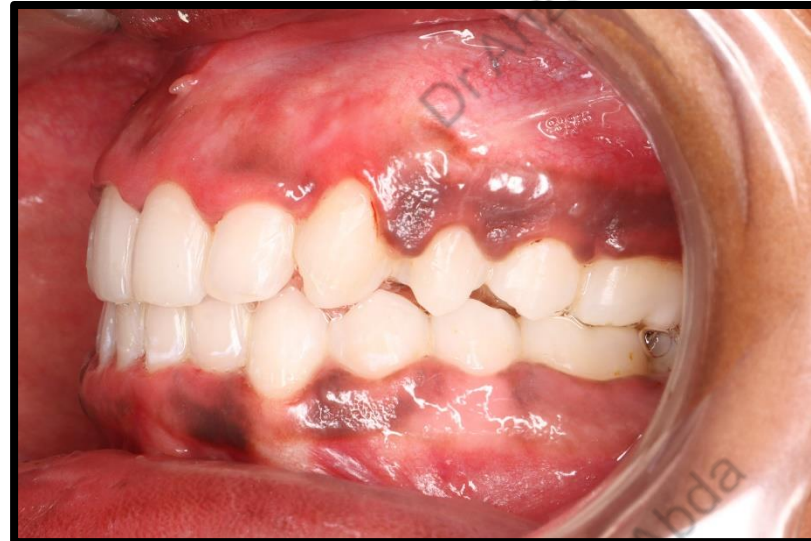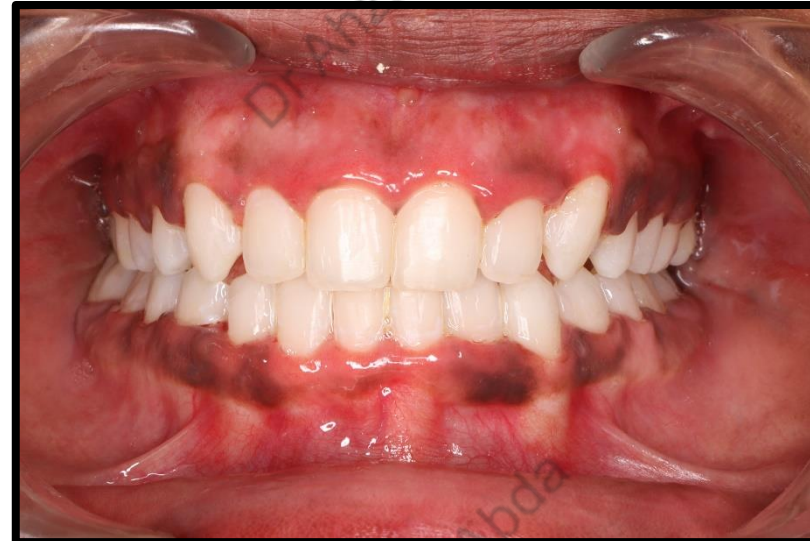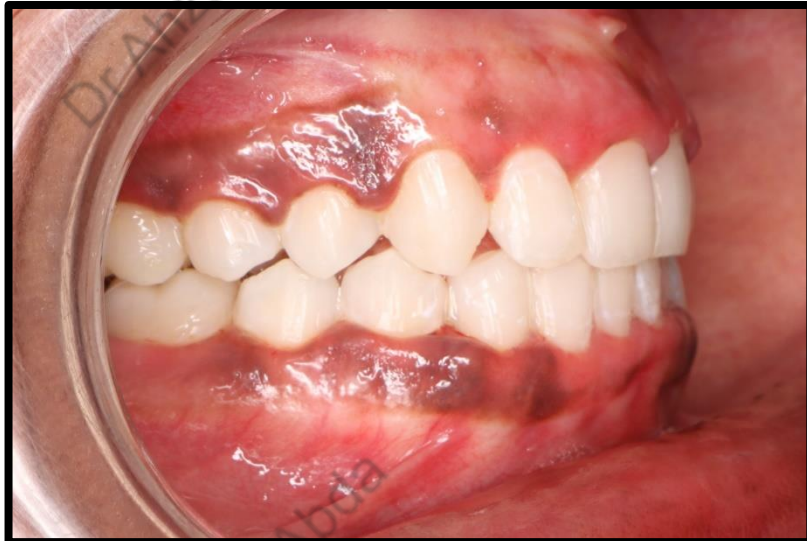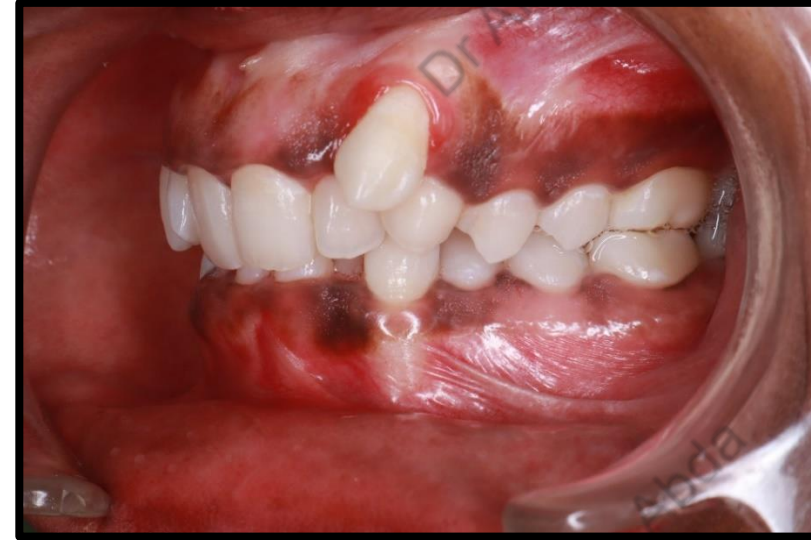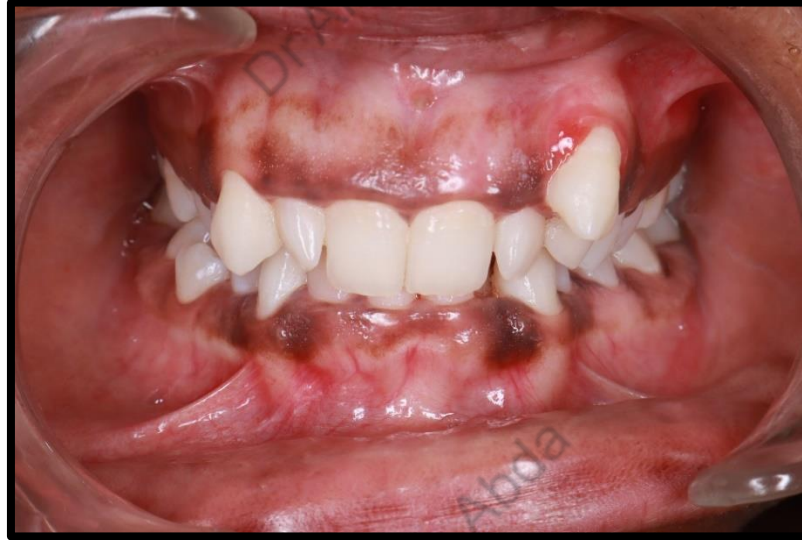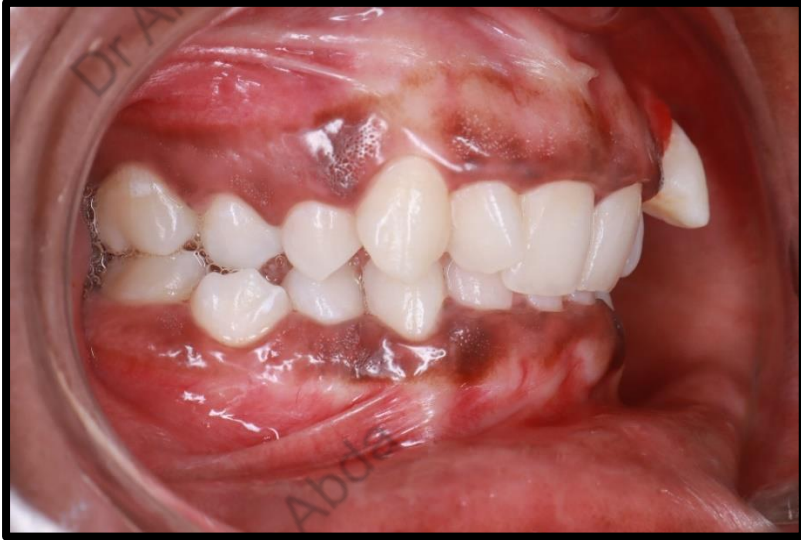# POST TREATMENT OPG



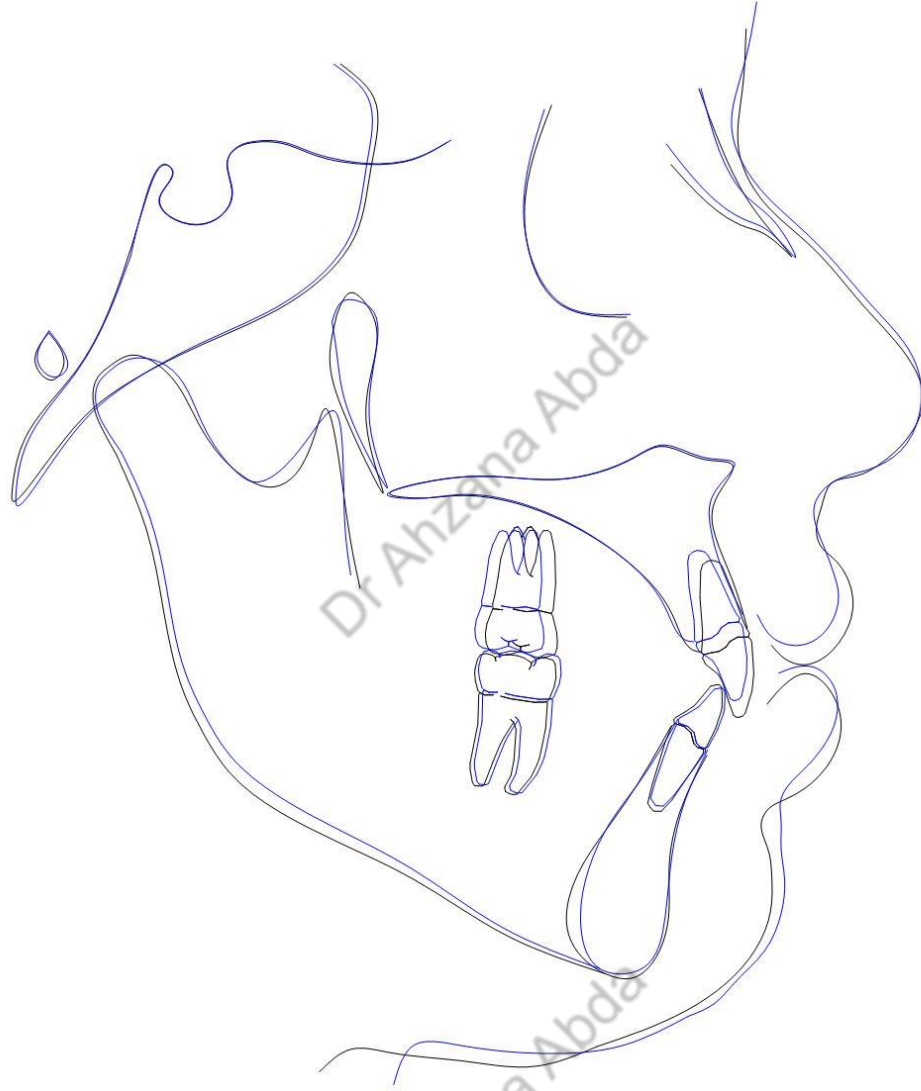
# POST TREATMENT LATERAL CEPHALOGRAM



# INTRA ORAL COMPARISON



# SUPERIMPOSITION



# CASE VII

**SHIBIN 19/M**

**PRE TREATMENT EXTRAORAL**

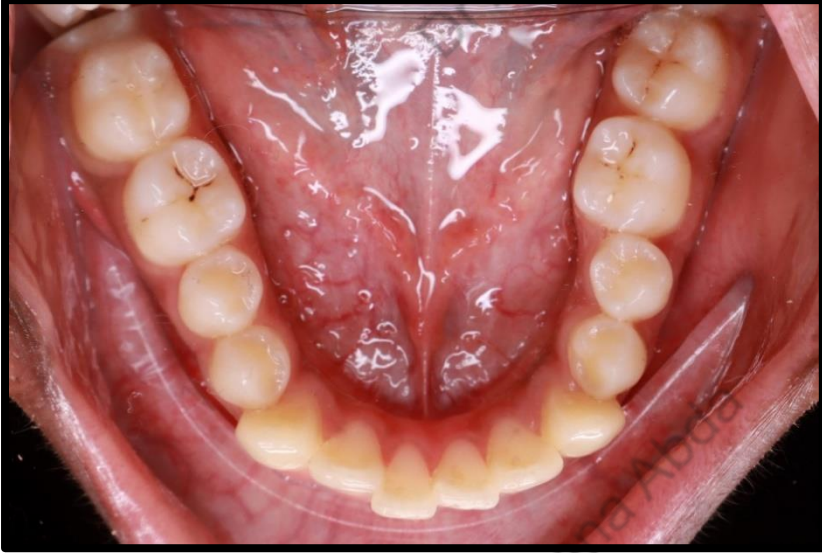
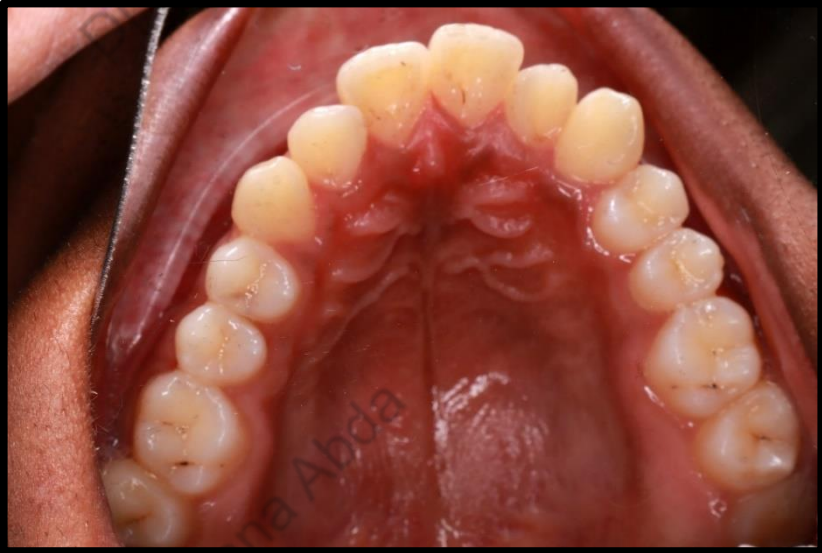
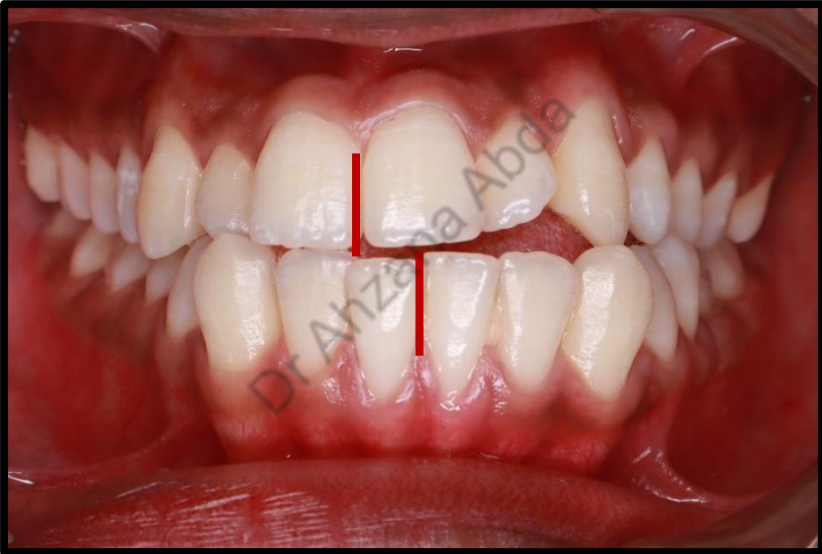
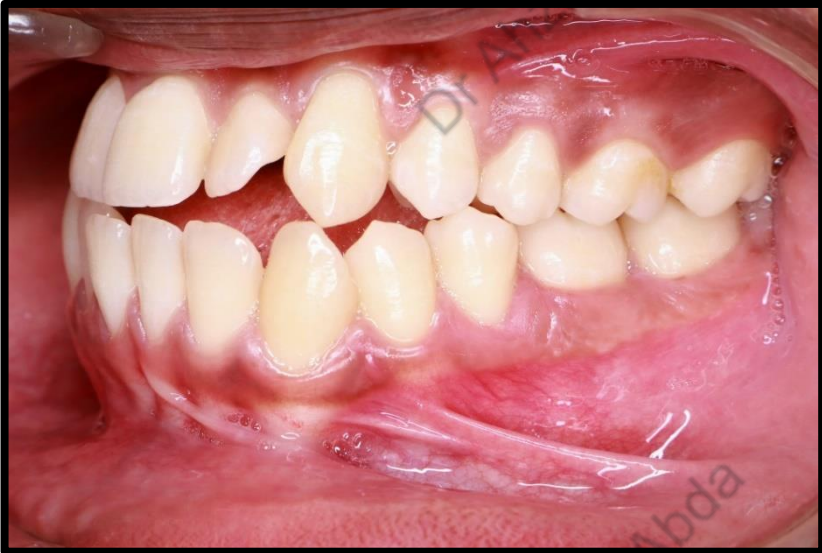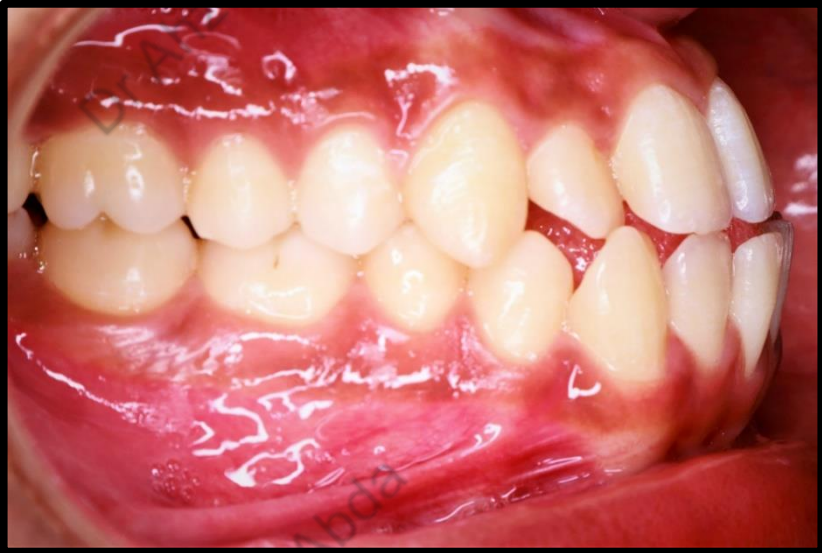# PRE TREATMENT EXTRAORAL PROFILE

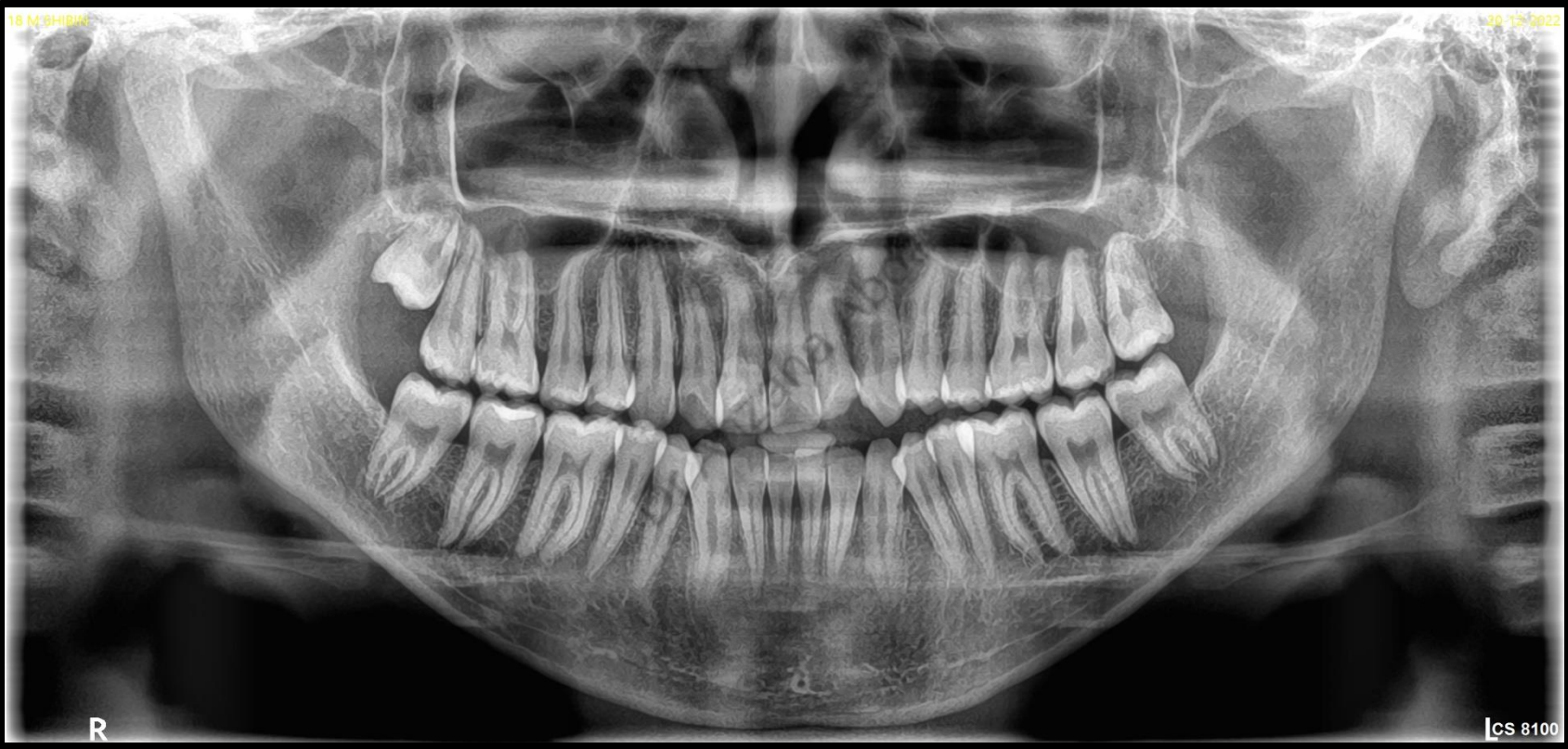



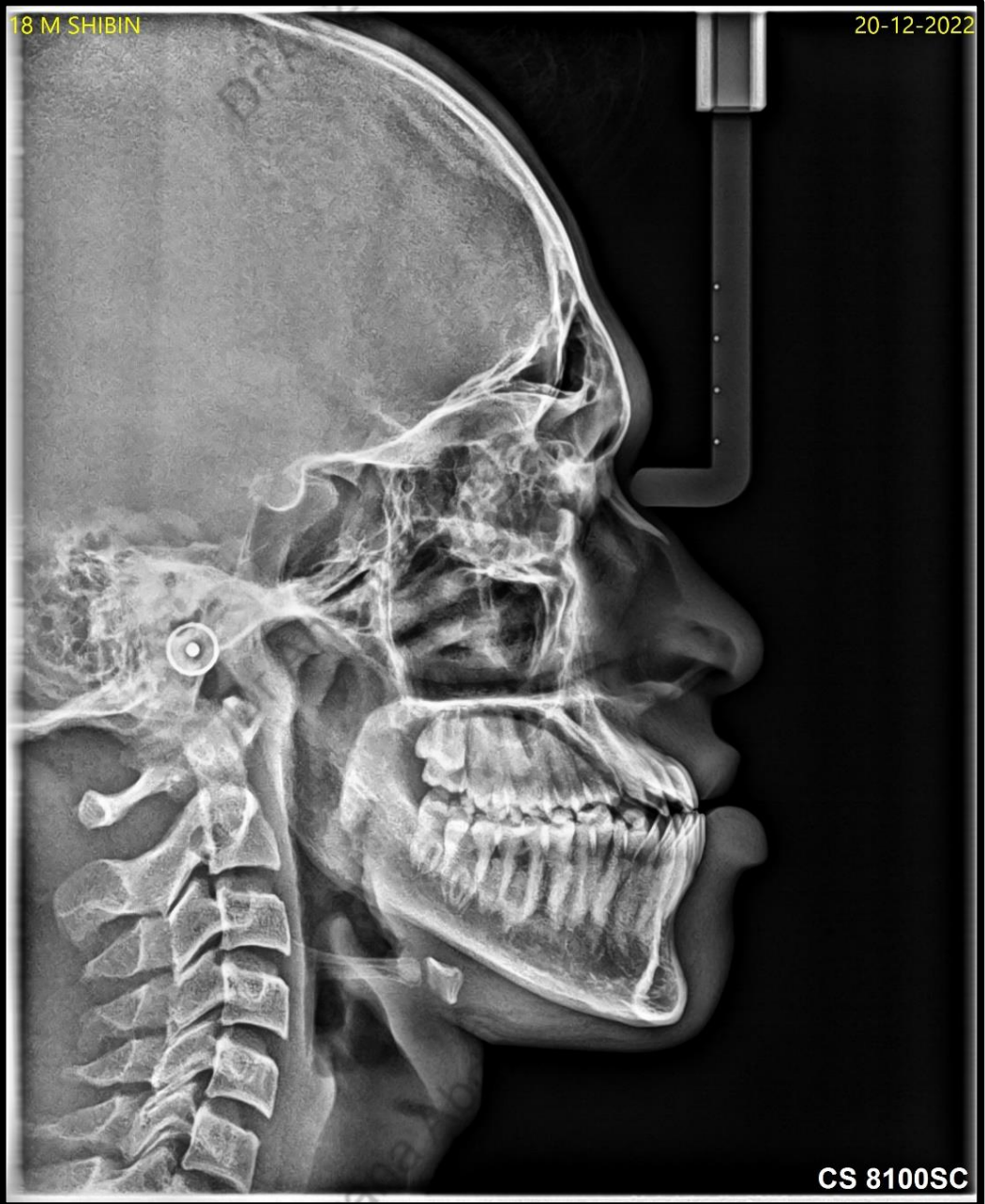**PRE TREATMENT INTRAORAL**



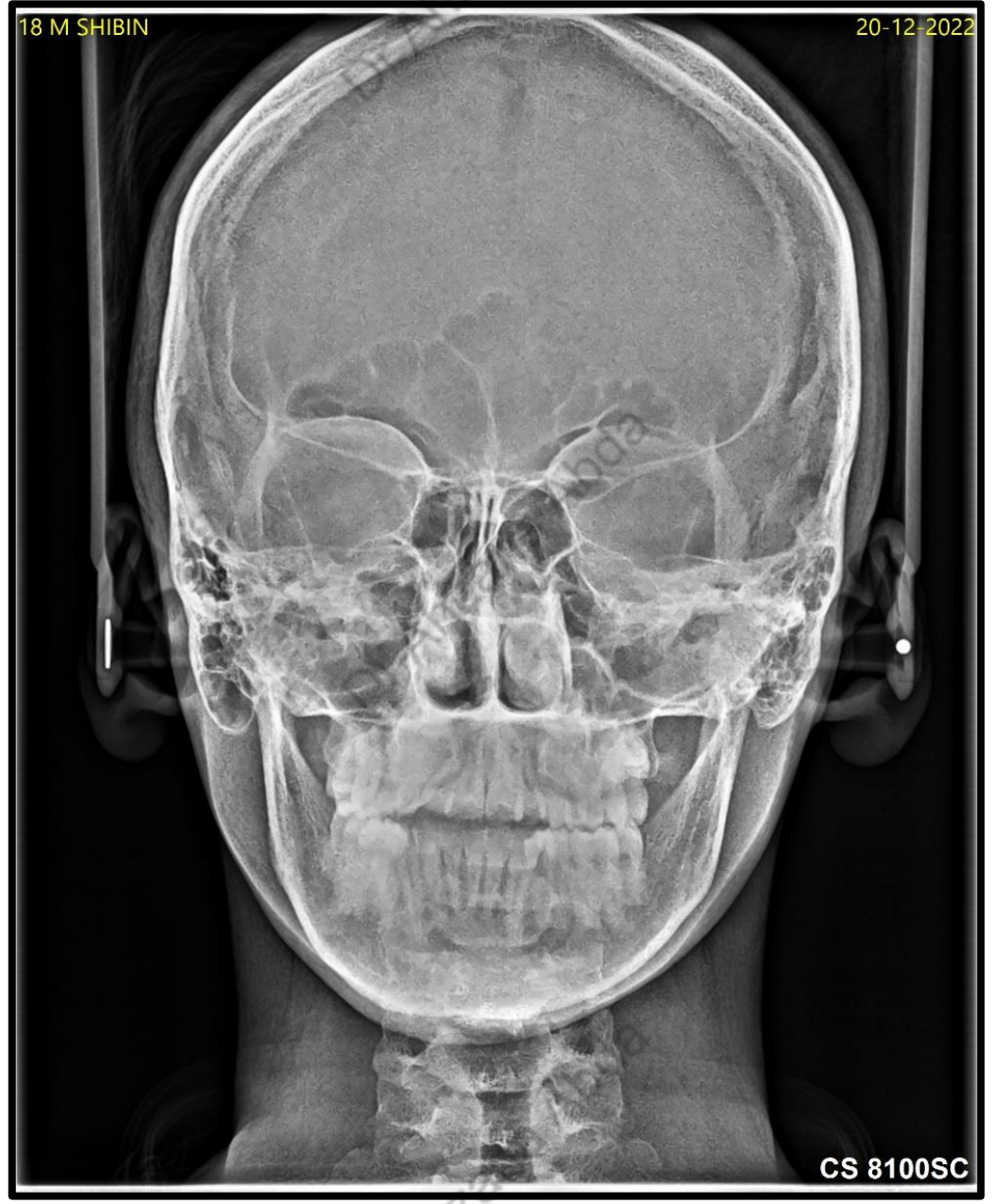
**PRE TREATMENT OPG**

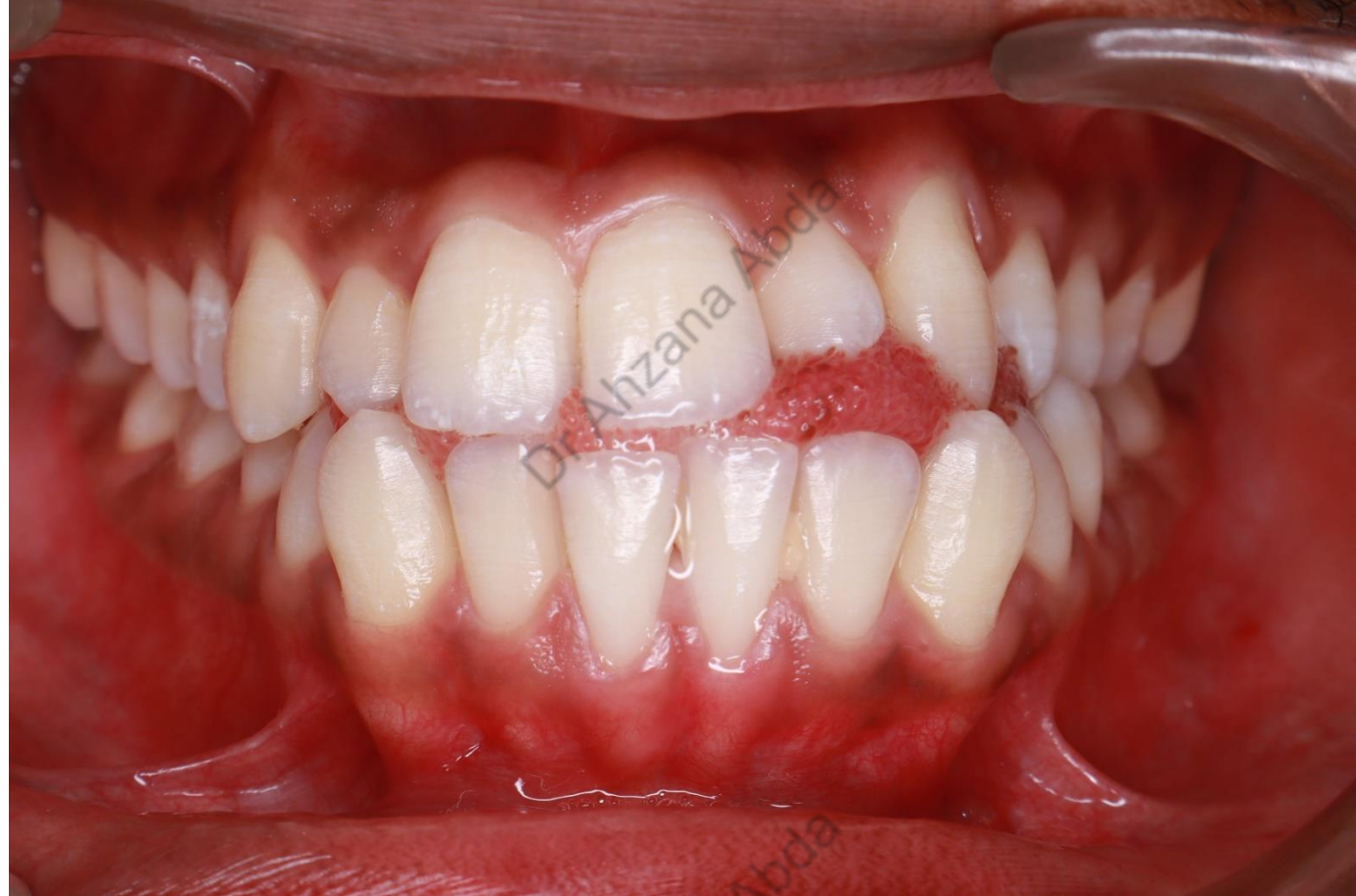

# PRE TREATMENT LATERAL CEPH

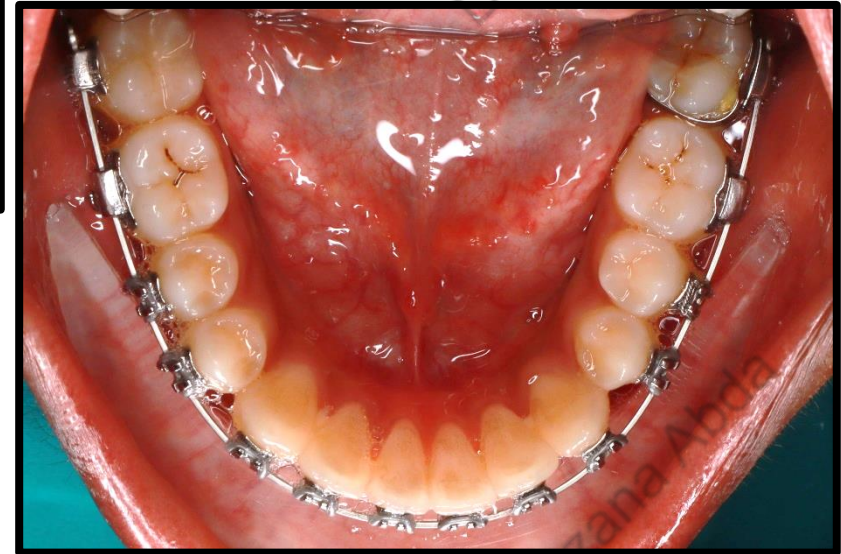
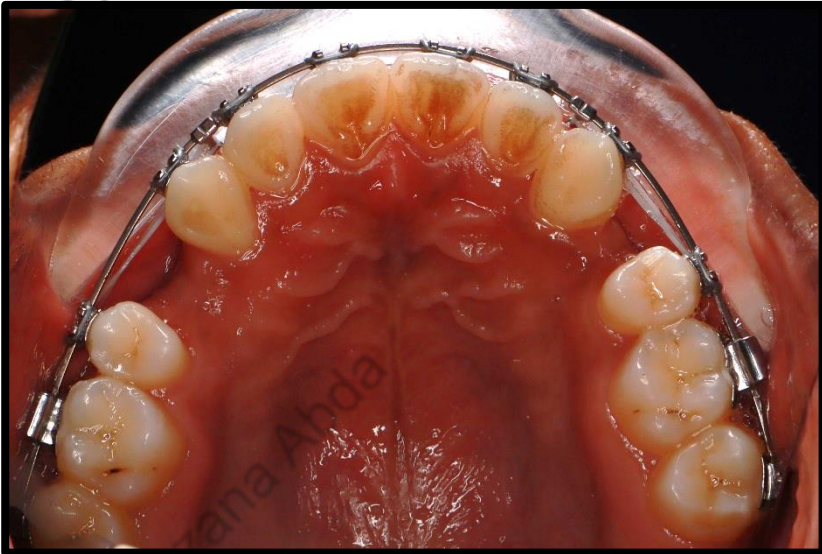
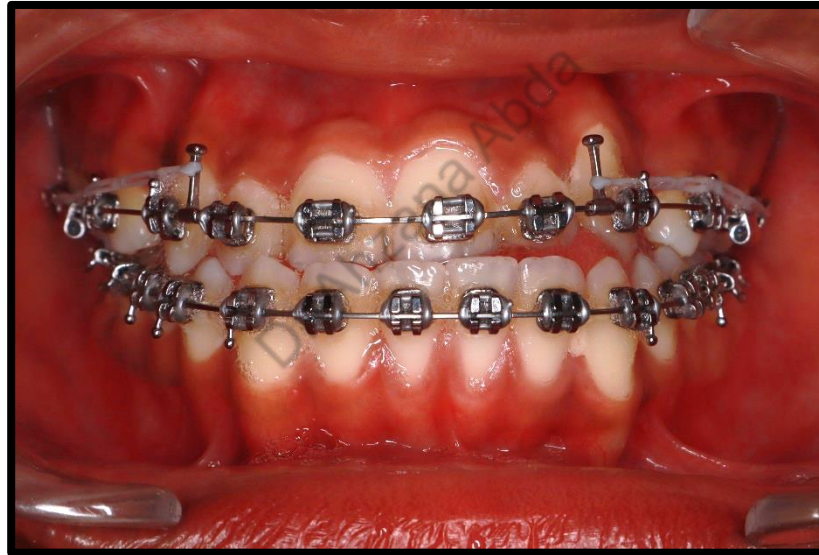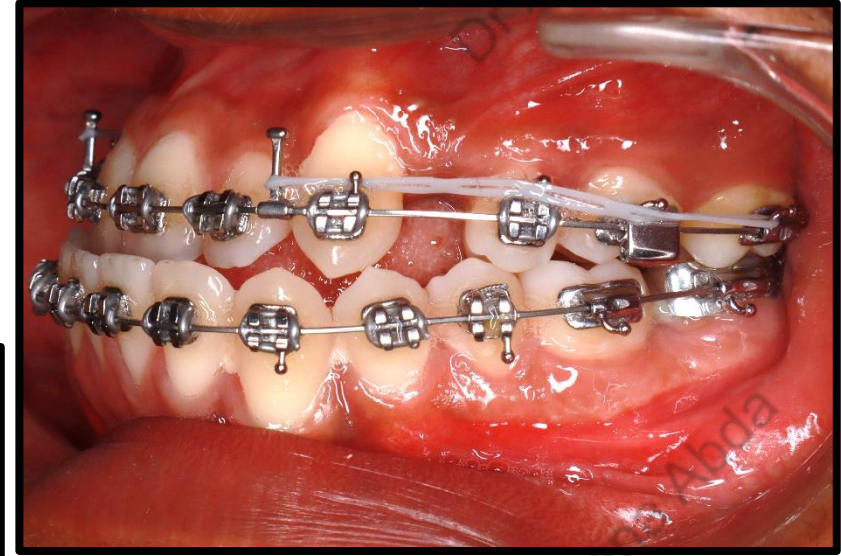
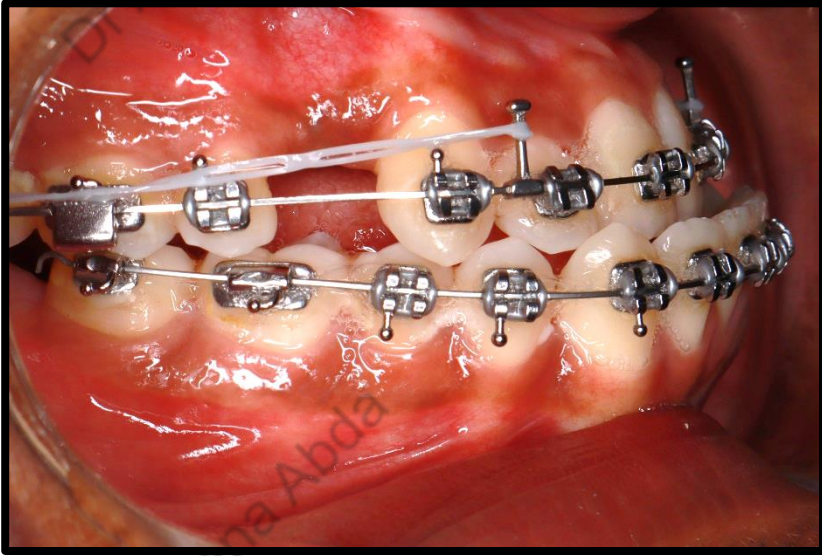


# PRE TREATMENT PA VIEW

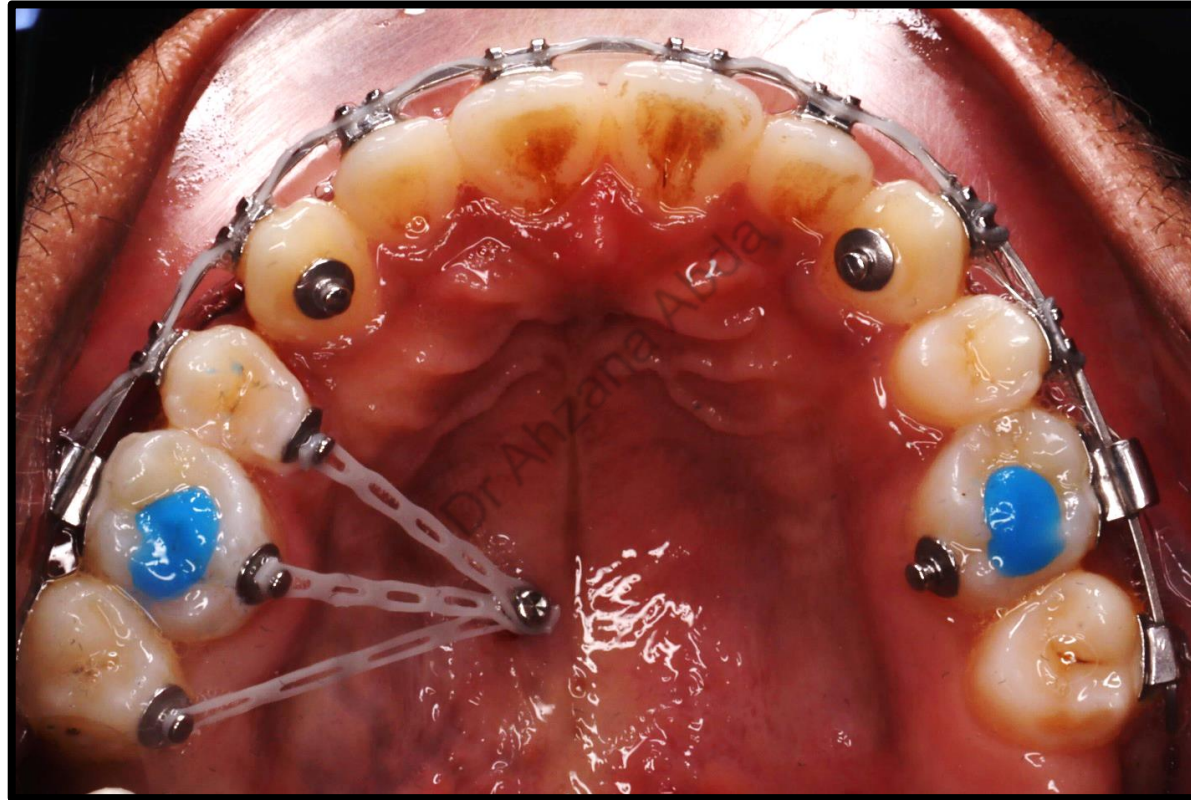




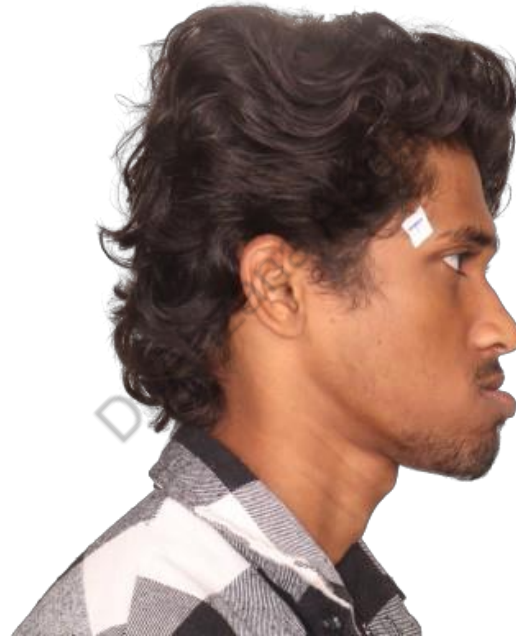# DECOMPENSATION



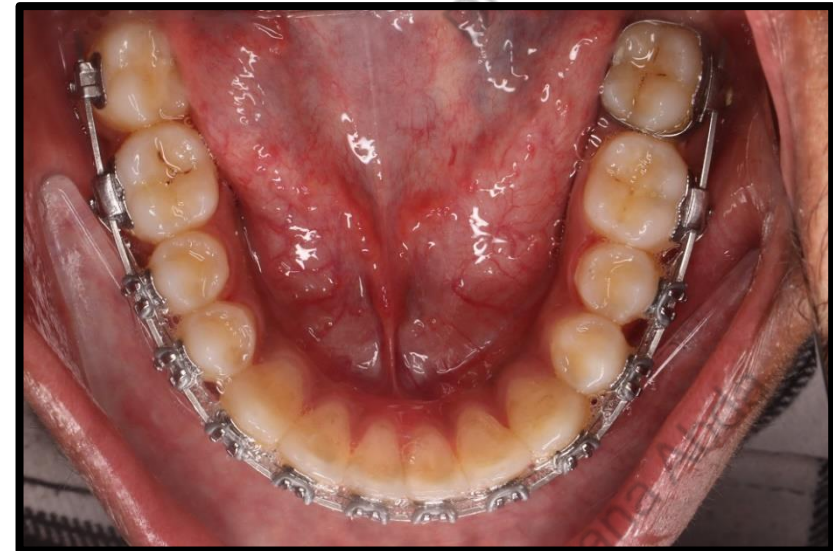
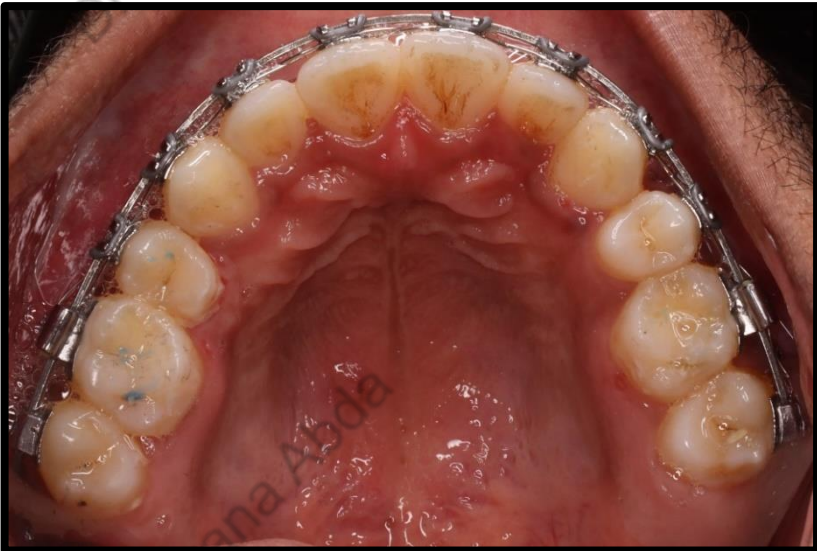
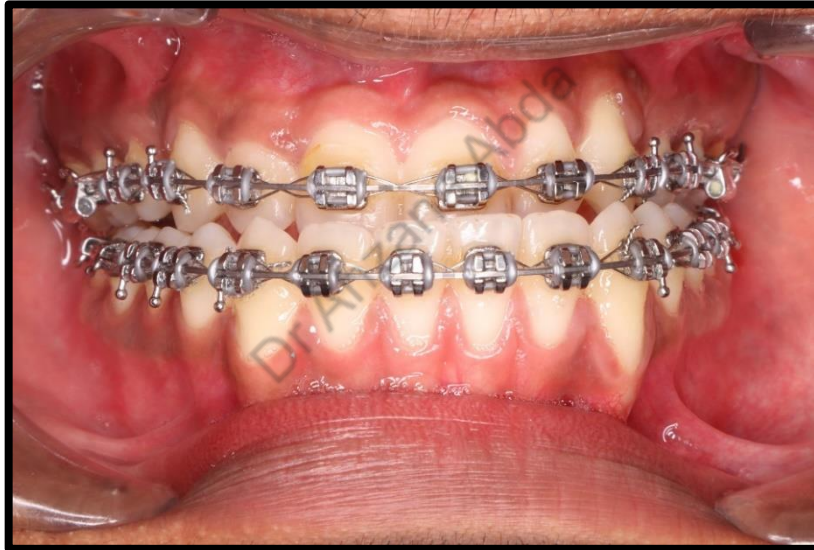
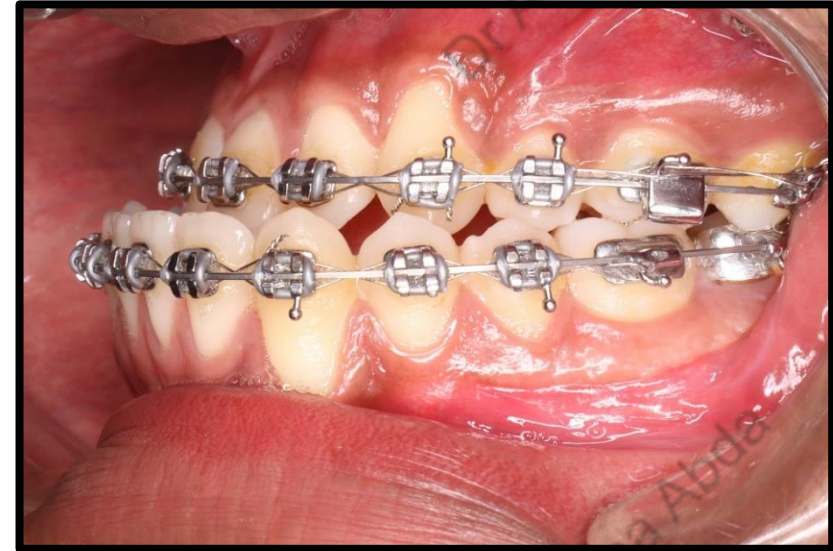
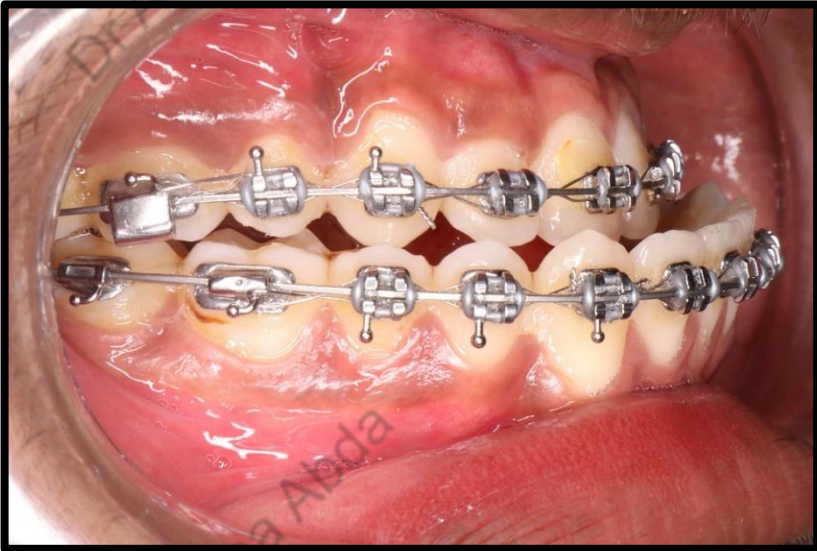# PALATAL TADS FOR CORRECTION OF OVERHANGING CUSPS



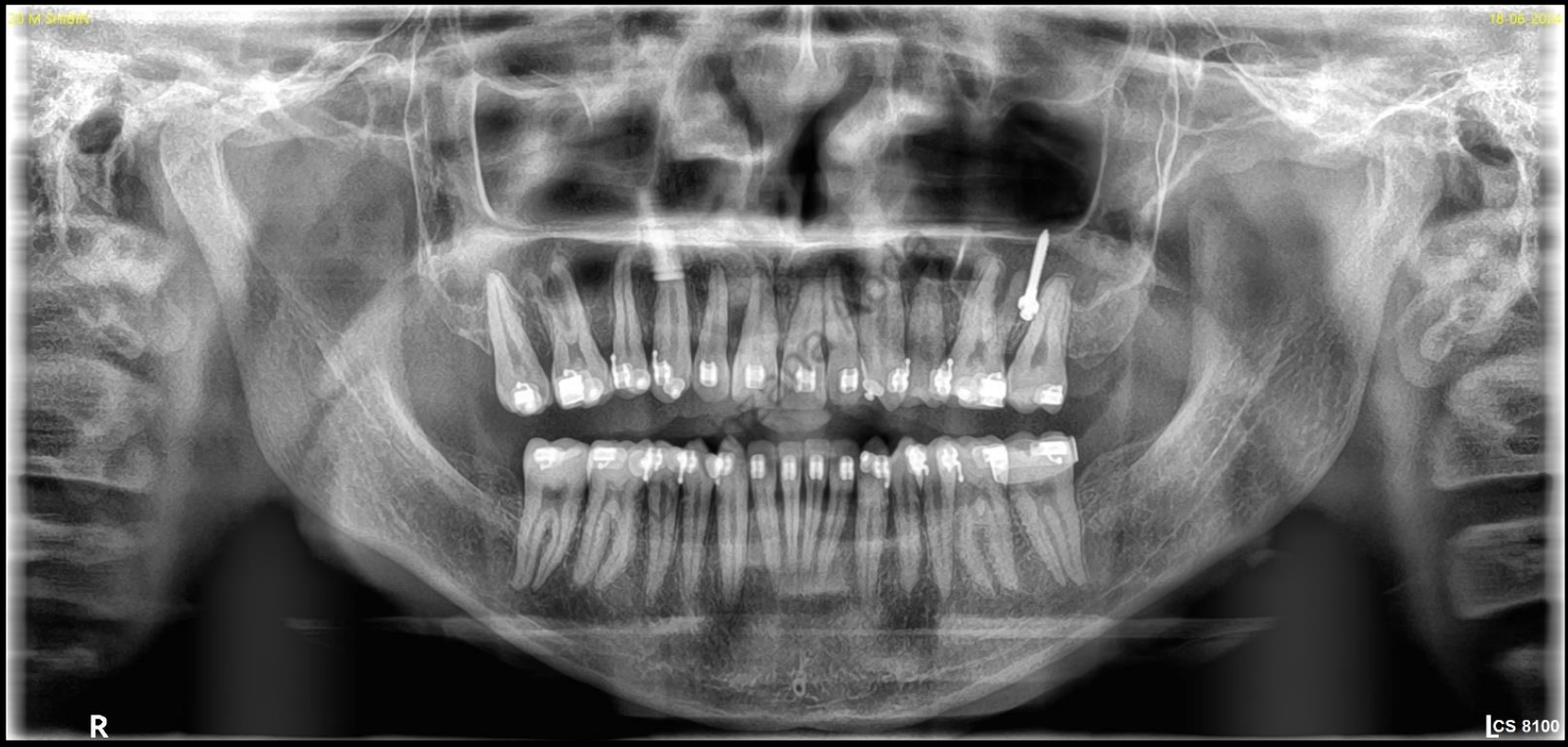# POST DECOMPENSATION EXTRA ORAL PHOTOGRAPHS



# POST DECOMPENSATION INTRA ORAL PHOTOGRAPHS



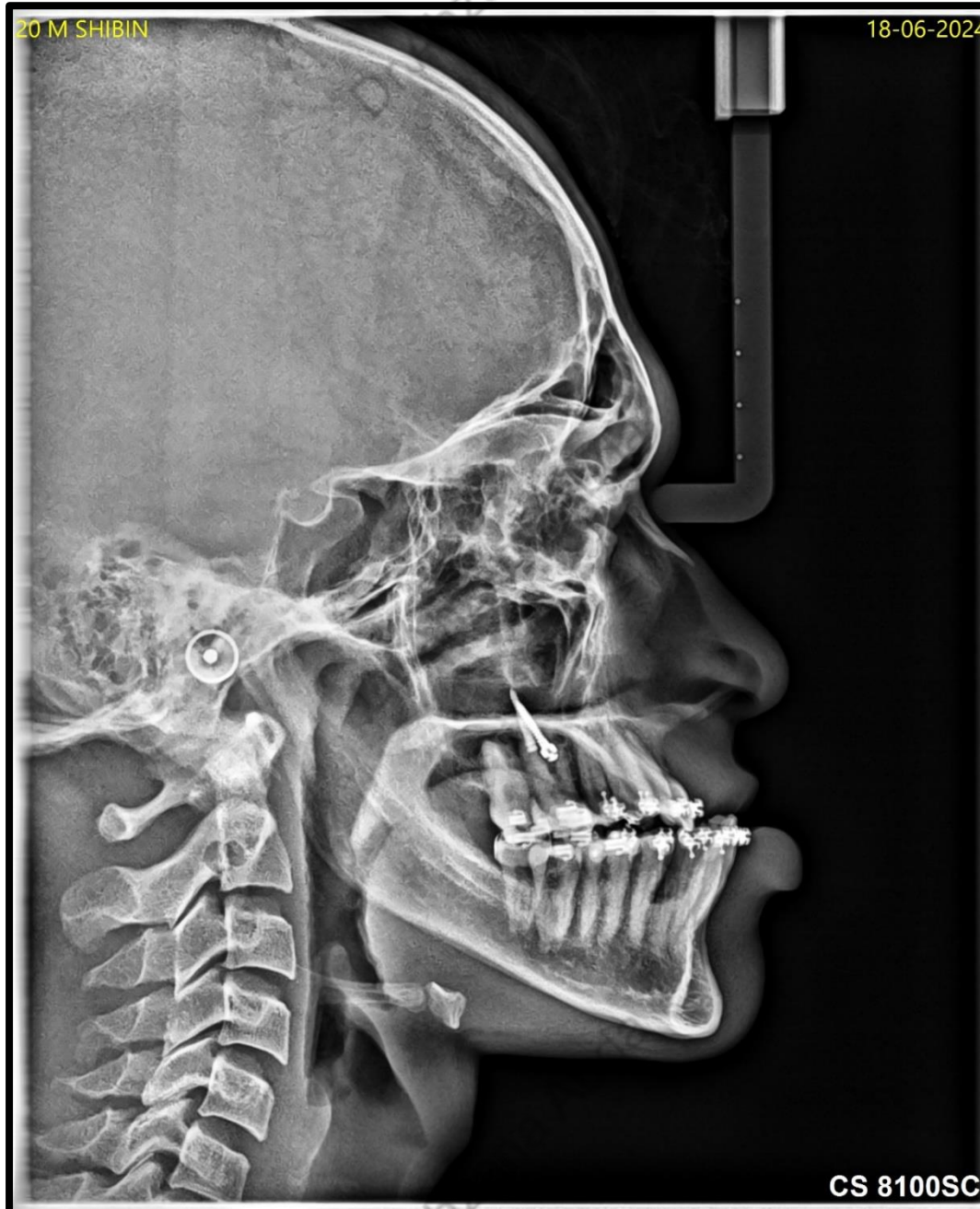**POST DECOMPENSATION OPG**



# POST DECOMPENSATION LATERAL CEPH

20 M SHIBIN

18-06-2024



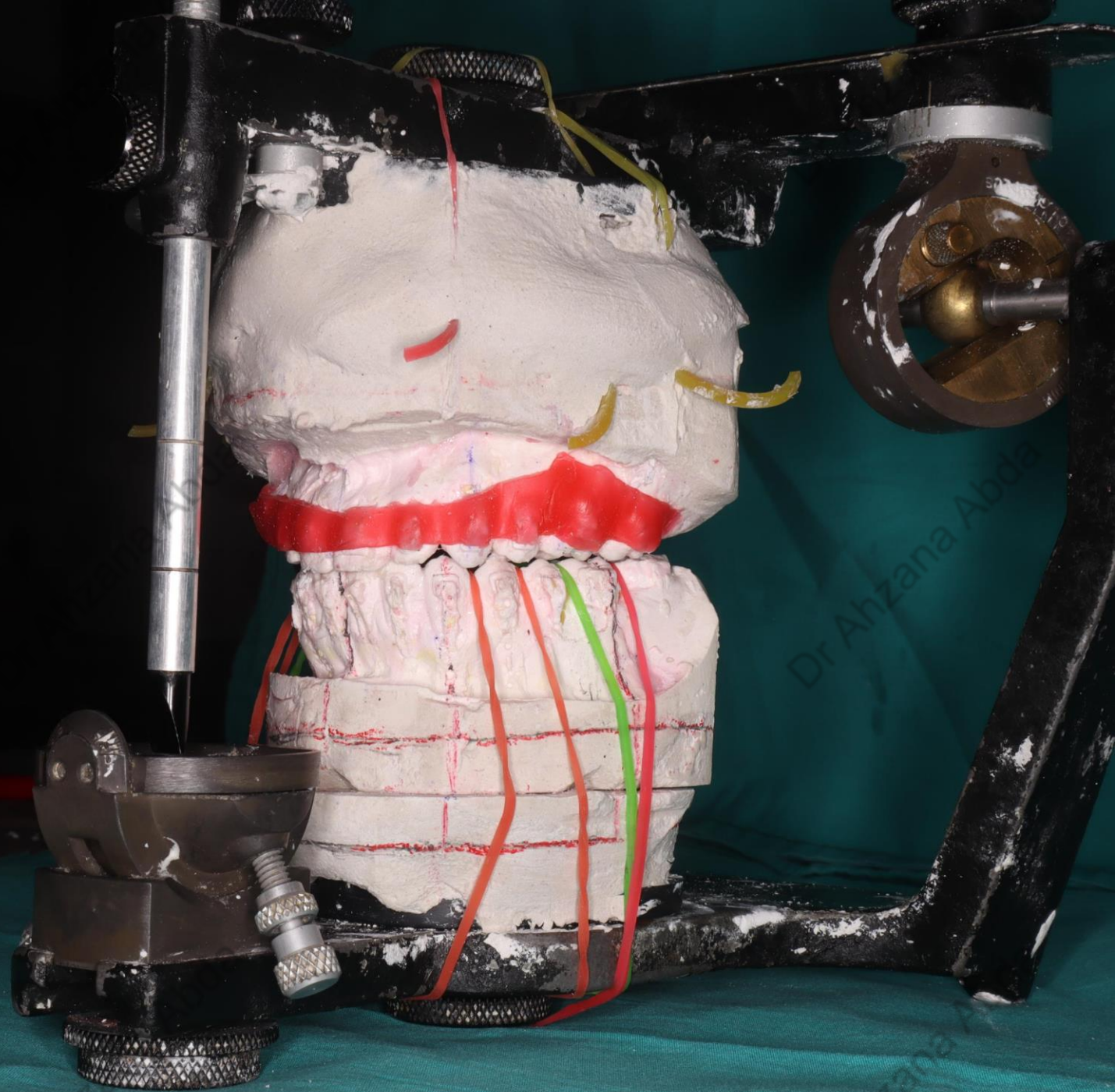
CS 8100SC

# DOLPHIN SIMULATION

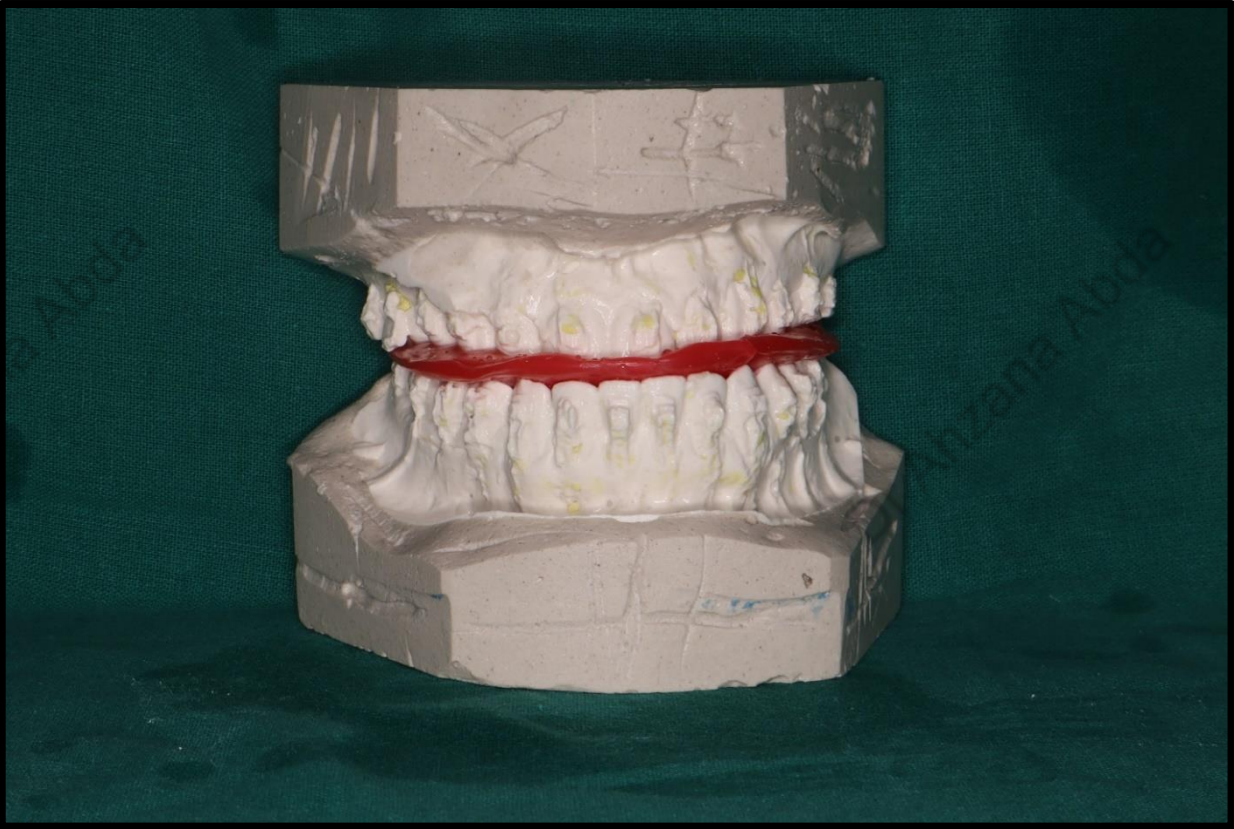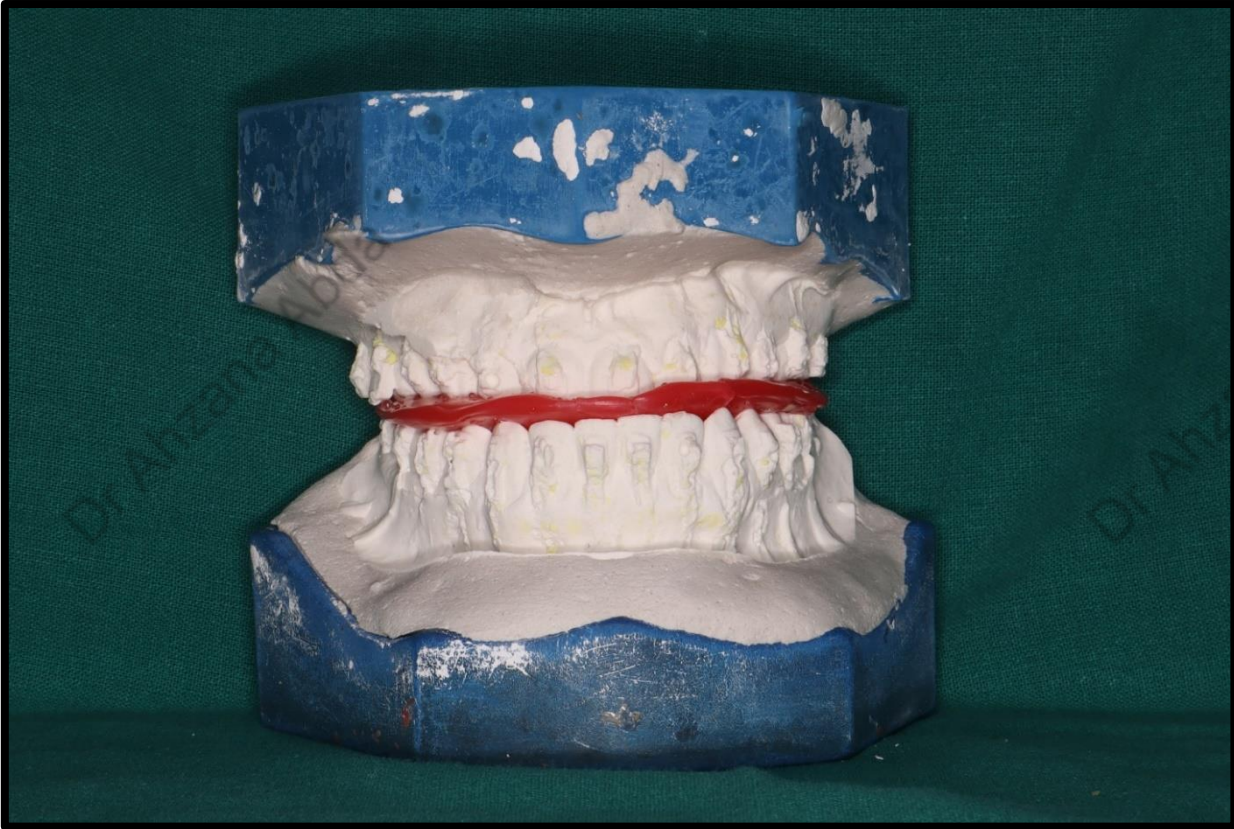- Lefort I Maxillary advancement of 4mm and asymmetric mandibular setback of 7mm on right side and 3mm on left side



# SPLINT FABRICATION





**WAX BITE AND BASING THE CAST**

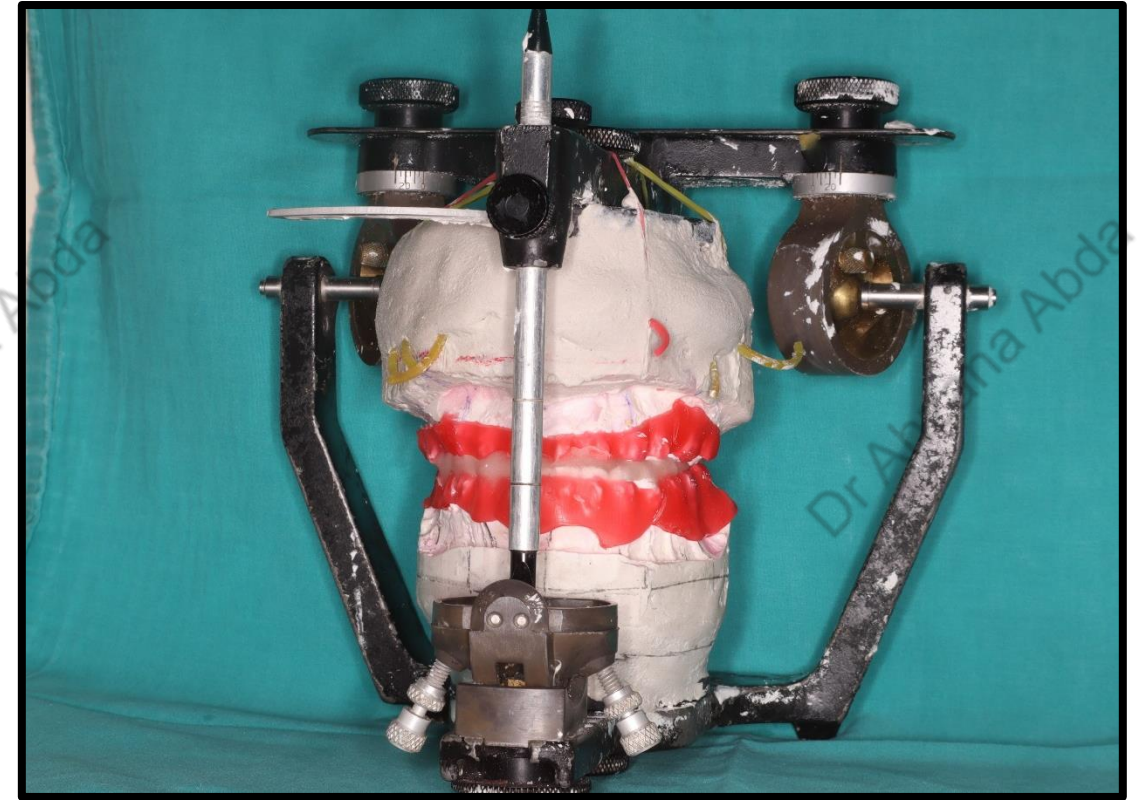



## FACEBOW TRANSFER



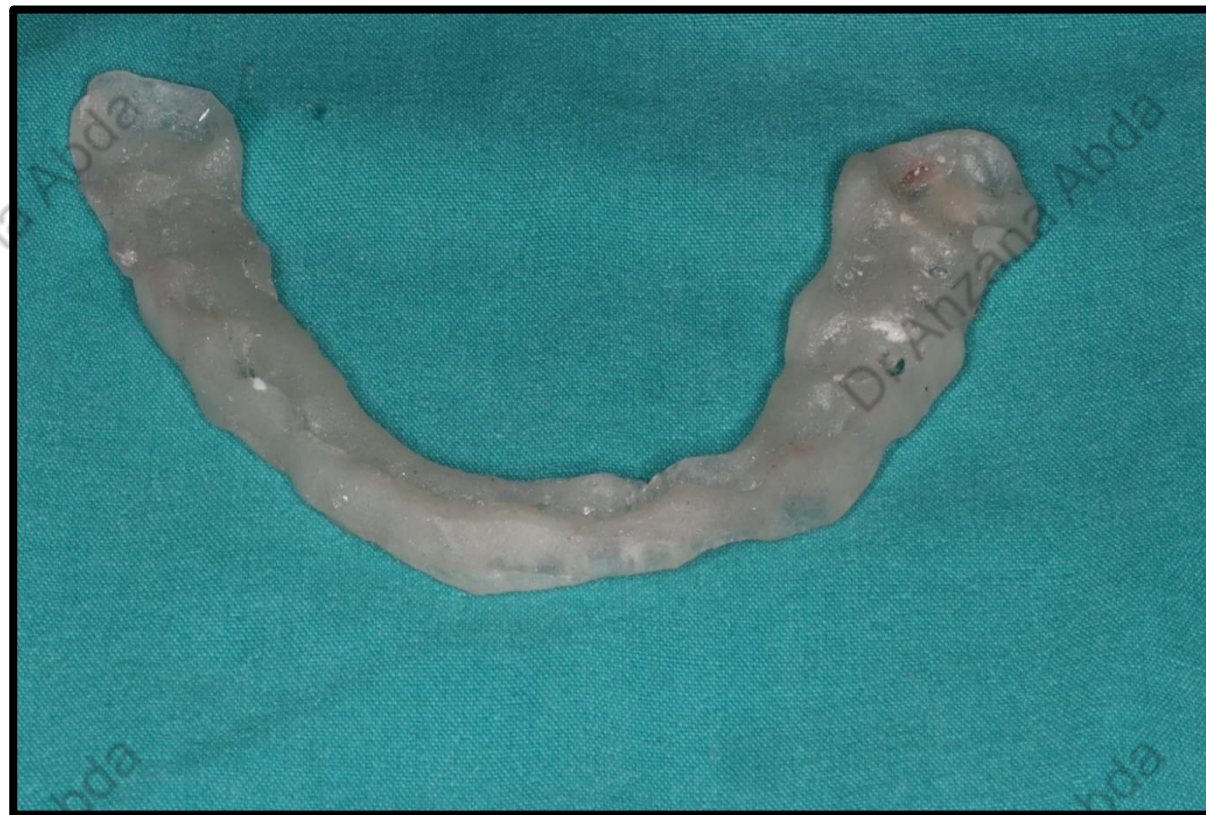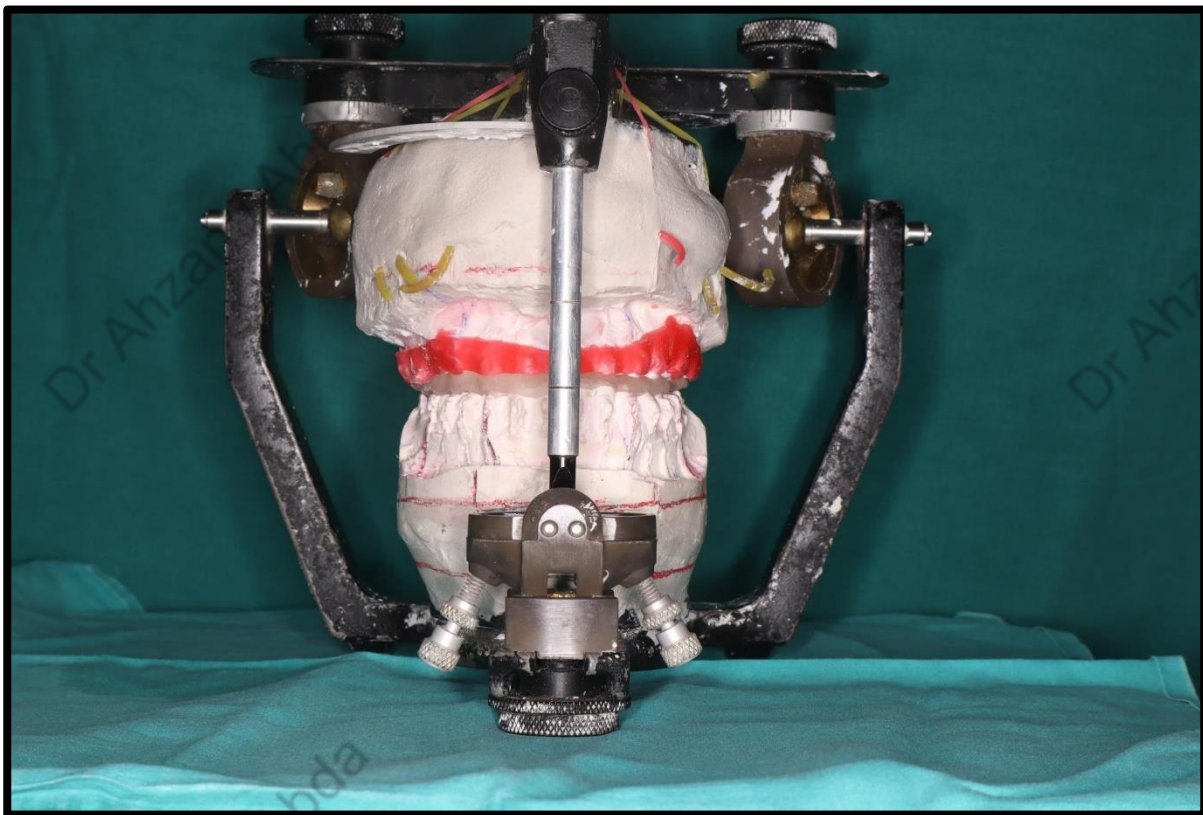


## **INTERMEDIATE SPLINT FABRICATION**

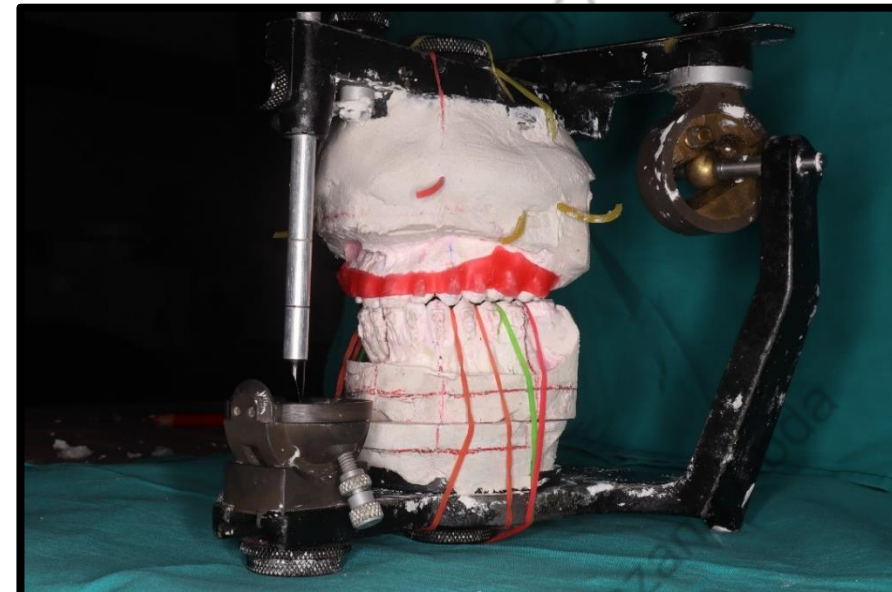



**INTERMEDIATE SPLINT FABRICATION**

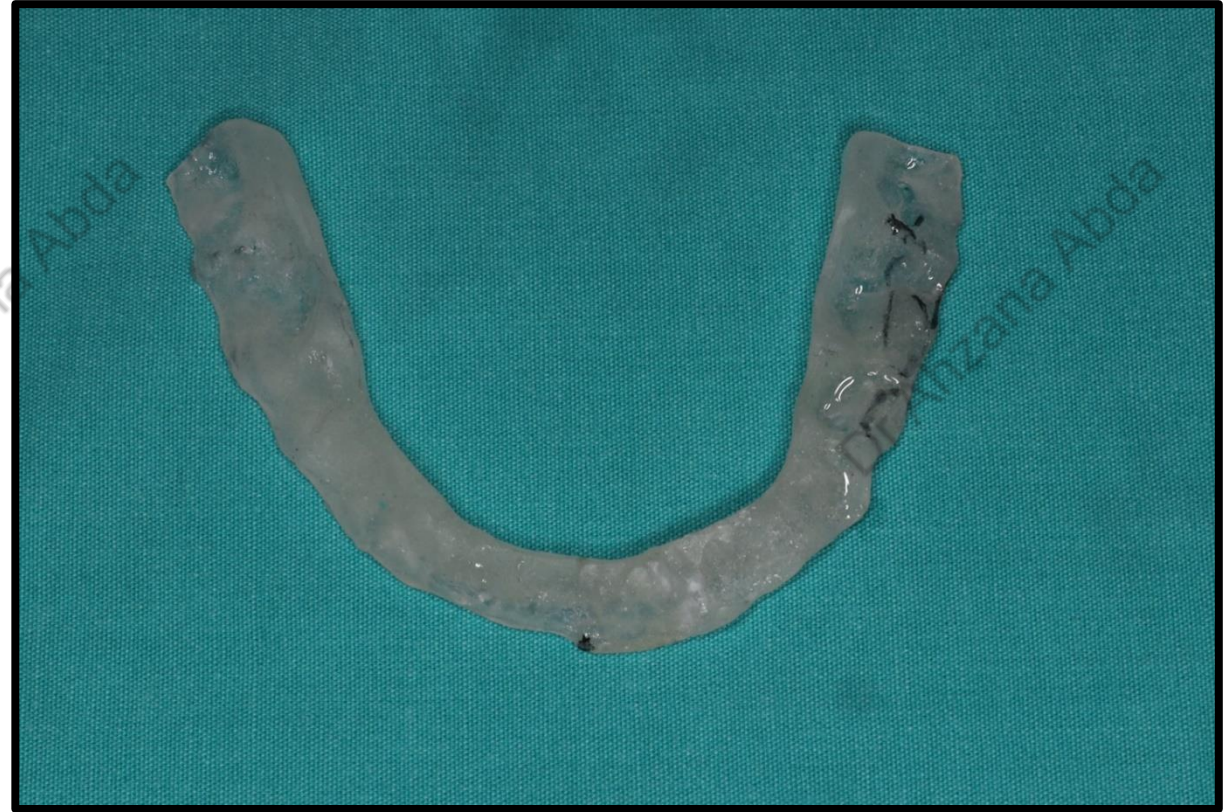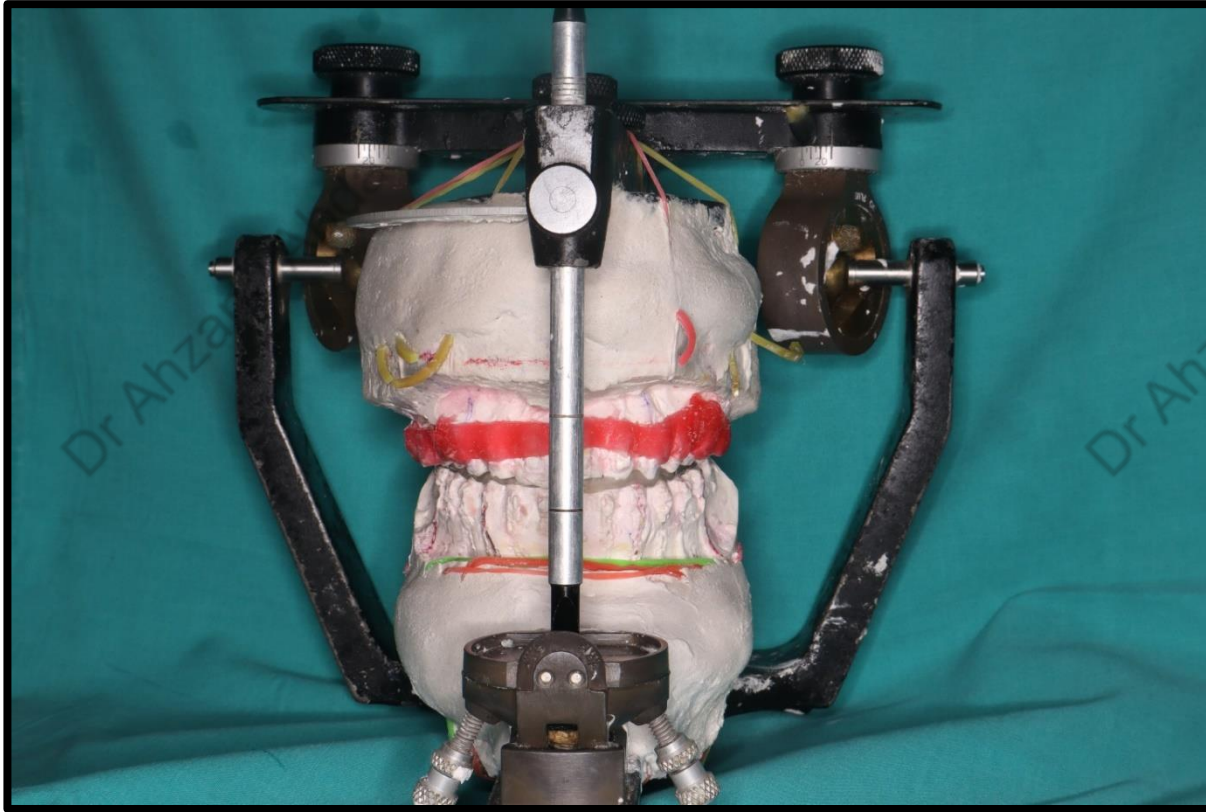
## INTERMEDIATE SPLINT



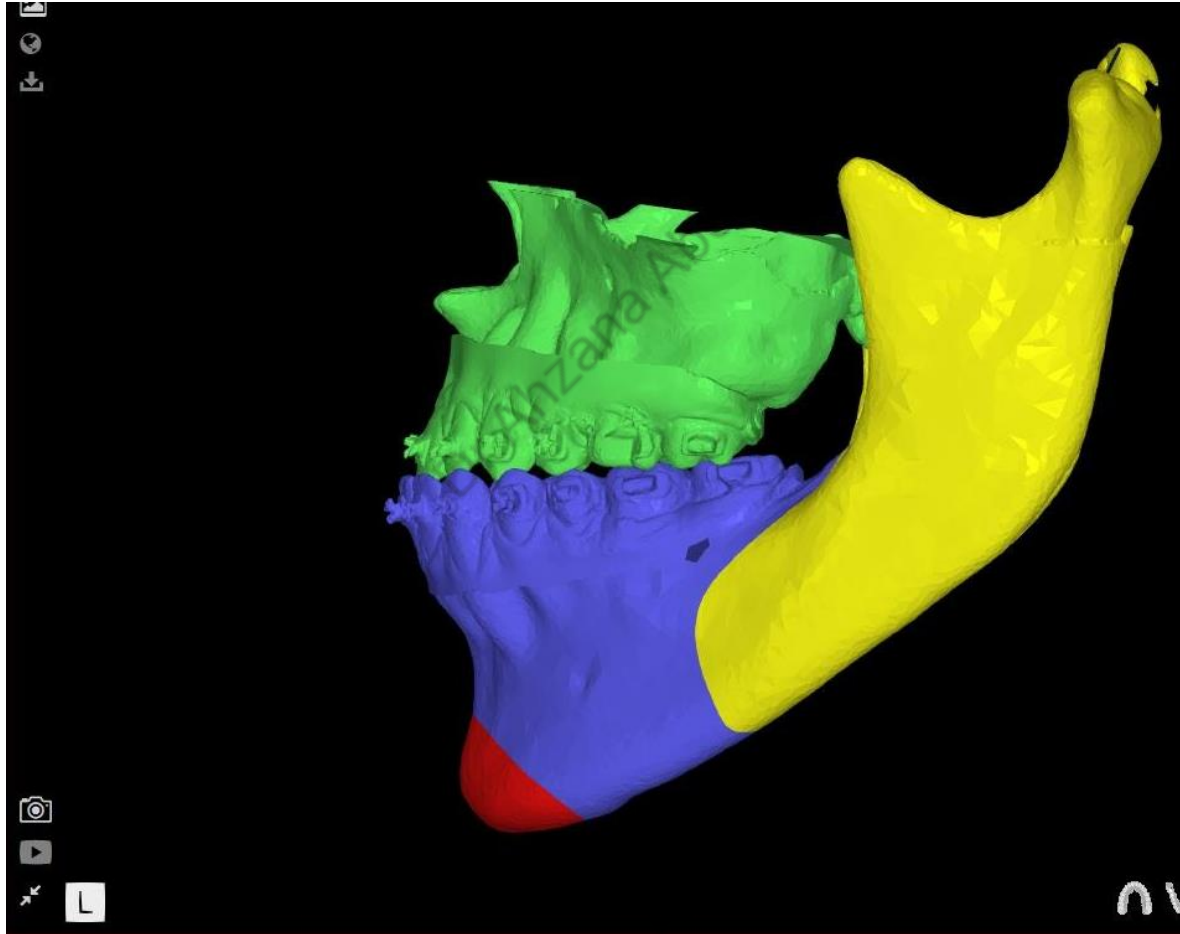
# FINAL SPLINT FABRICATION



# FINAL SPLINT



## 3D SPLINT PLANNING AND FABRICATION



## SURGICAL MOVEMENTS- MAXILLA

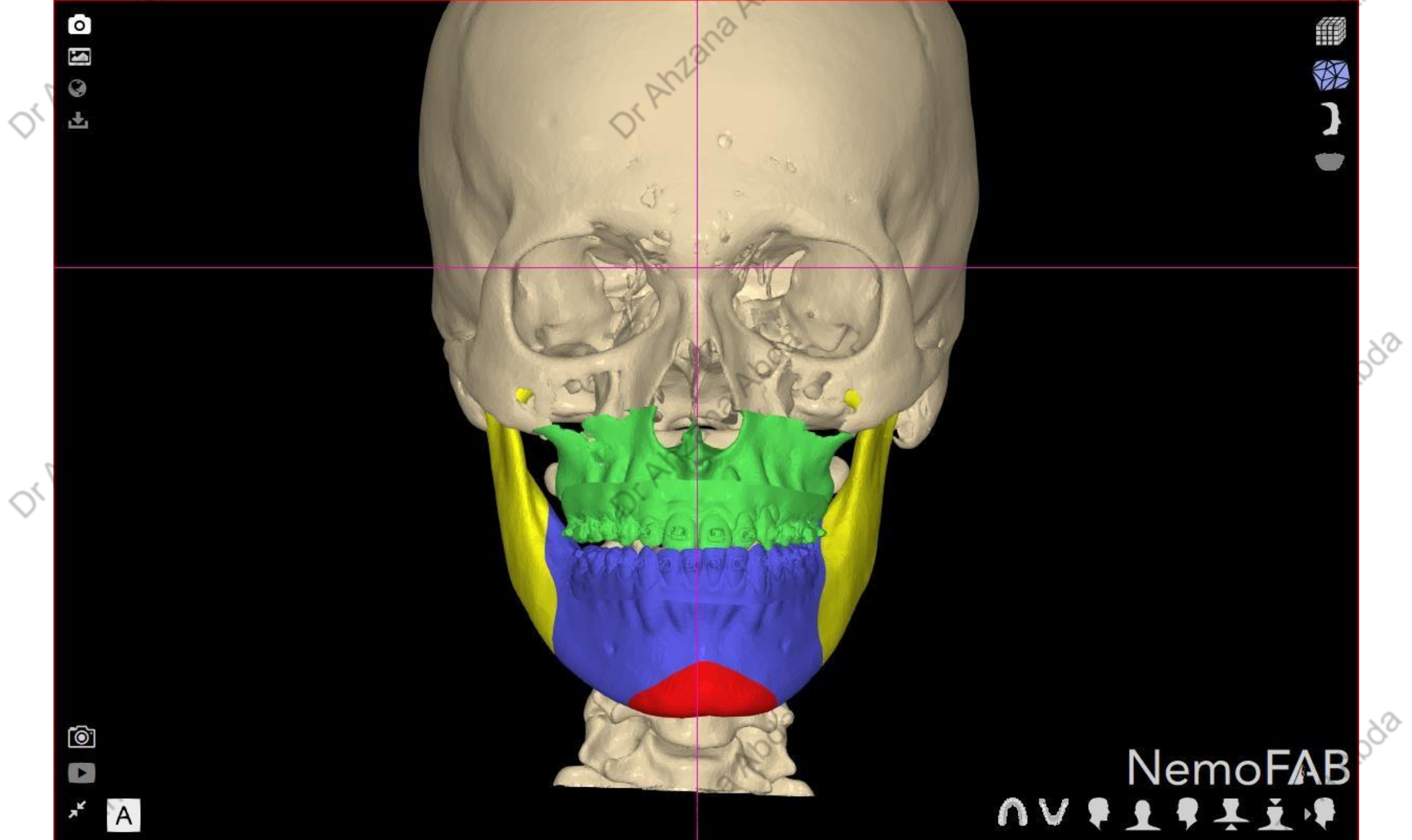
SURGICAL MOVEMENTS	IN MM	DESCRIPTION
MAXILLARY ADVANCEMENT	4MM	CORRECT DEFICIENT MAXILLA
ANS SHIFTING LEFT	2MM	CORRECT YAW
PNS SHIFTING RIGHT	0.2MM	CORRECT YAW
ASSYMETRIC ADVANCEMENT RIGHT SIDE	5MM	MIDLINE CORRECTION
ASSYMETRIC ADVANCEMENT LEFT SIDE	3MM	MIDLINE CORRECTION
RIGHT MAXILLA INTRUSION	0.5MM	CANT CORRECTION
LEFT MAXILLA EXTRUSION	0.5MM	CANT CORRECTION

## SURGICAL MOVEMENTS- MANDIBLE

SURGICAL MOVEMENTS	IN MM	DESCRIPTION
MANDIBULAR SETBACK AT INCISORS	5MM	
ASSYMETRIC SETBACK LEFT SIDE	4.5MM	CORRECT MIDLINE
ASSYMETRIC SETBACK RIGHT SIDE	5.5MM	CORRECT MIDLINE
RIGHT MAND EXTRUSION	1 MM	CANT CORRECTION
LEFT MANDIBLE INTRUSION	0.2MM	CANT CORRECTION
MANDIBLE SHIFTING TO RIGHT	2MM	MATCH MIDLINE
GENIOPLASTY	??	FOR CHIN ADVANCEMENT

**FINAL OVERJET = 1.8 mm**

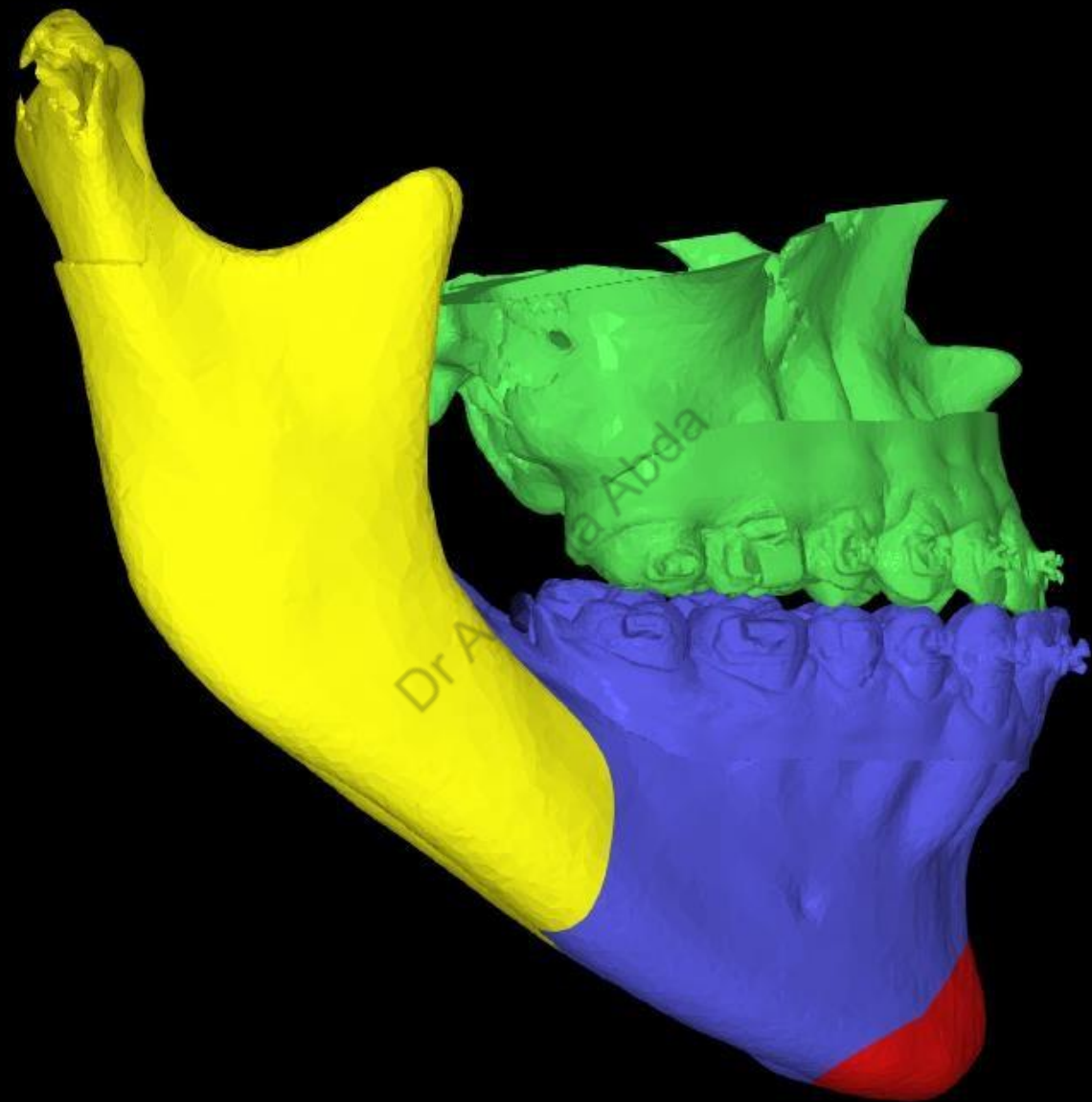
# **POST MAXILLARY SURGERY**



A

NemoFAB

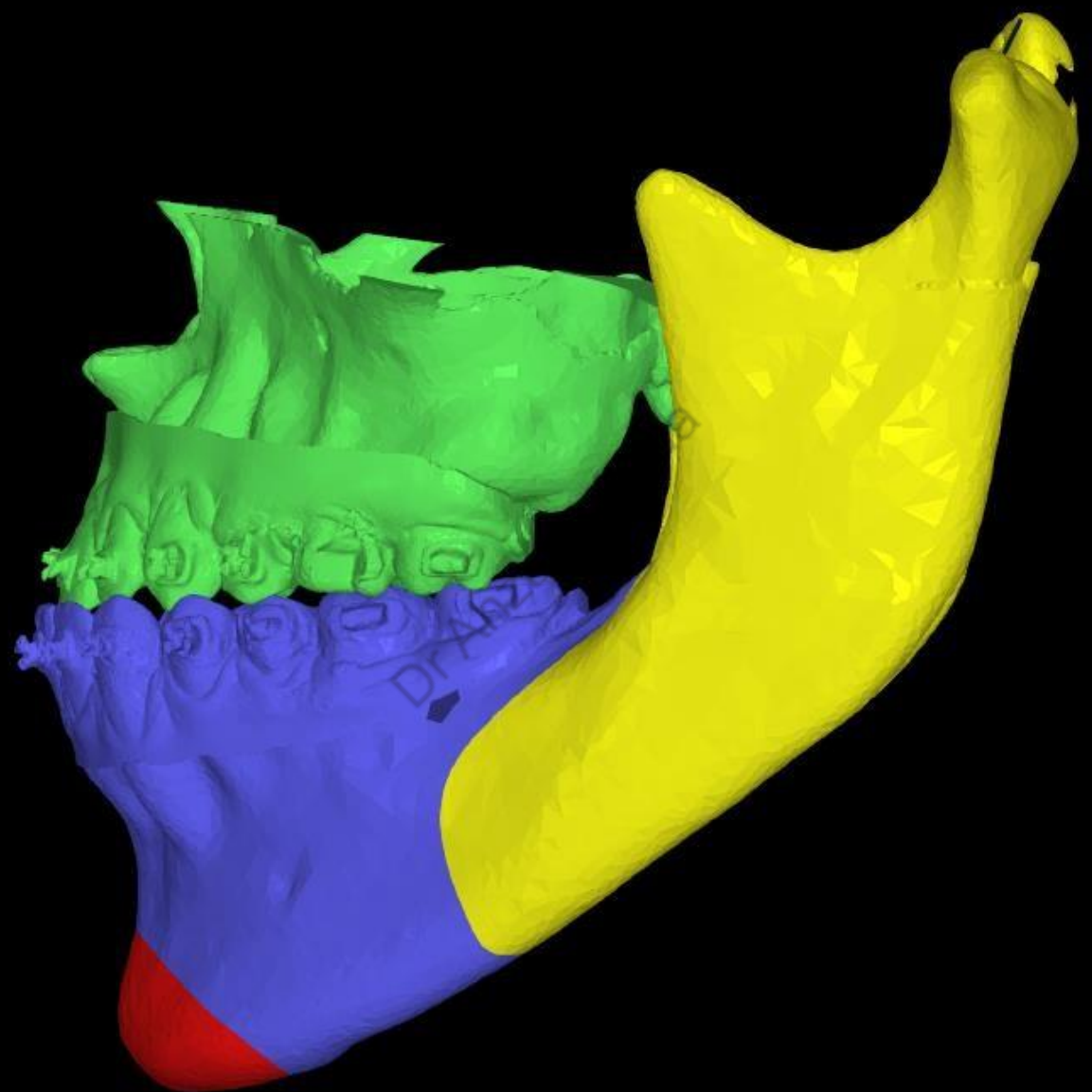




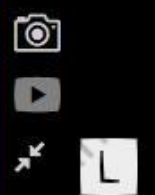NemoFAB

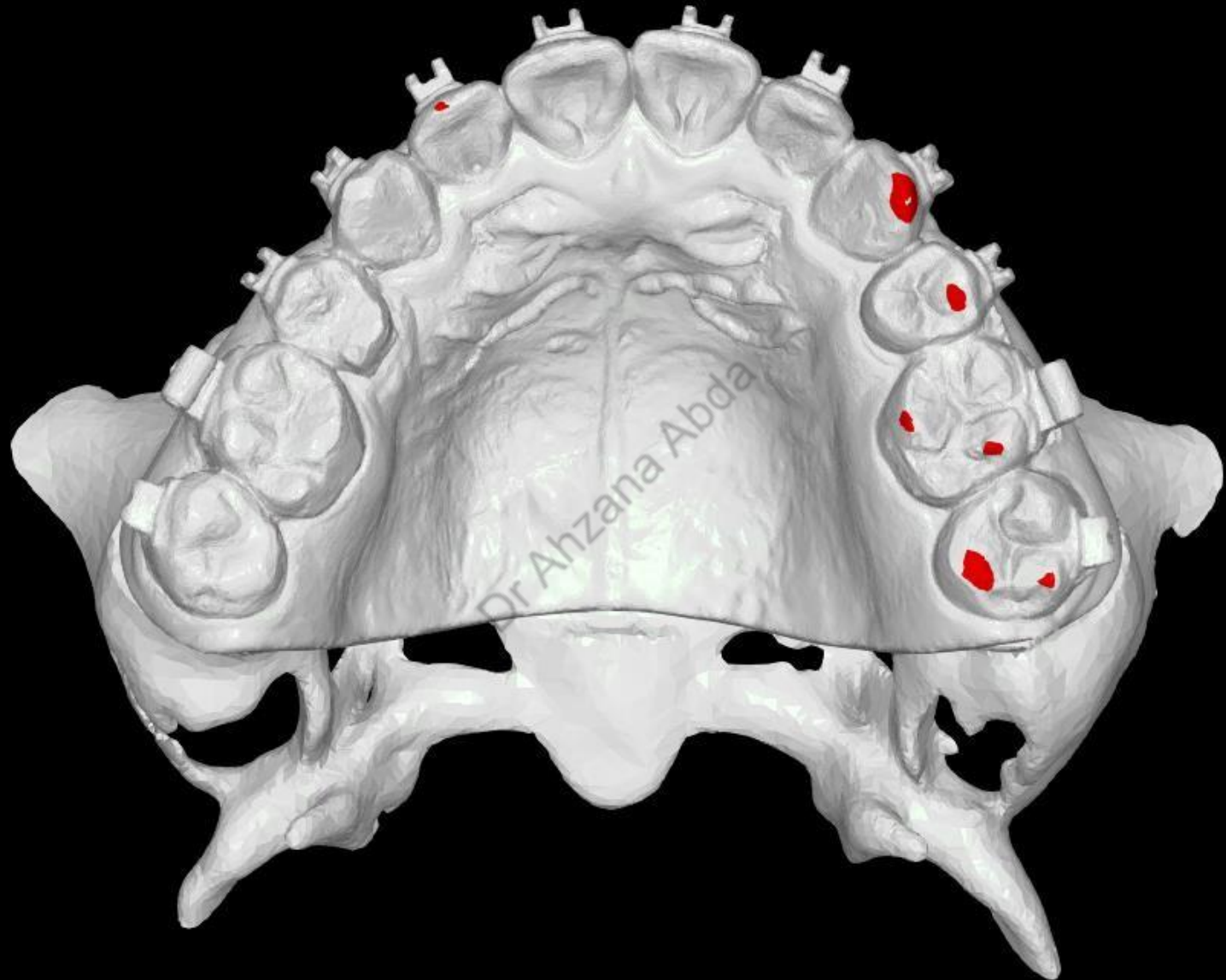


R



NemoFAB





Dr Ahzana Abda

NemoFAB



Dr A

Abda

# POST MANDIBULAR SURGERY

Dr. A

Dr. A

Abda

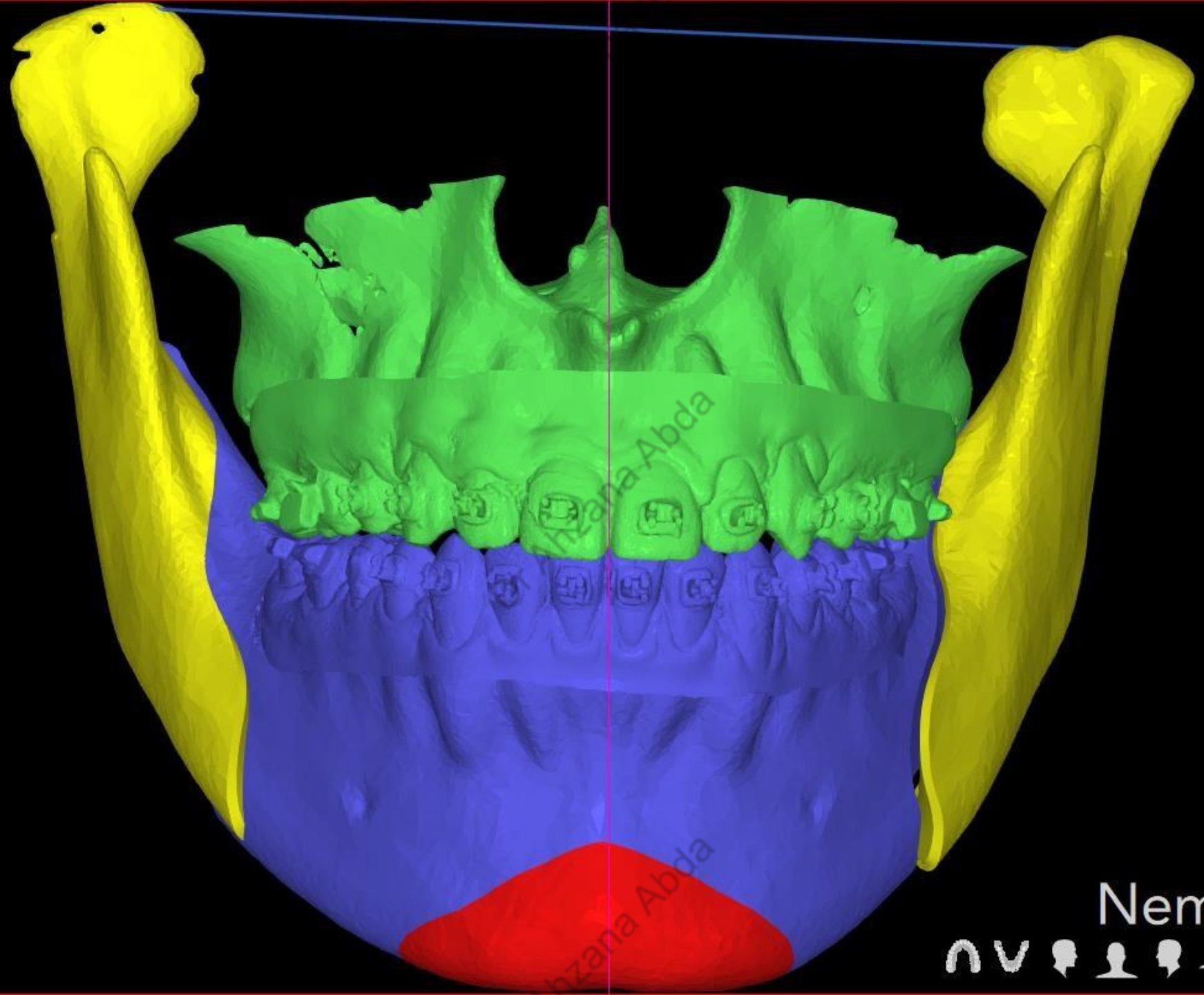
Abda

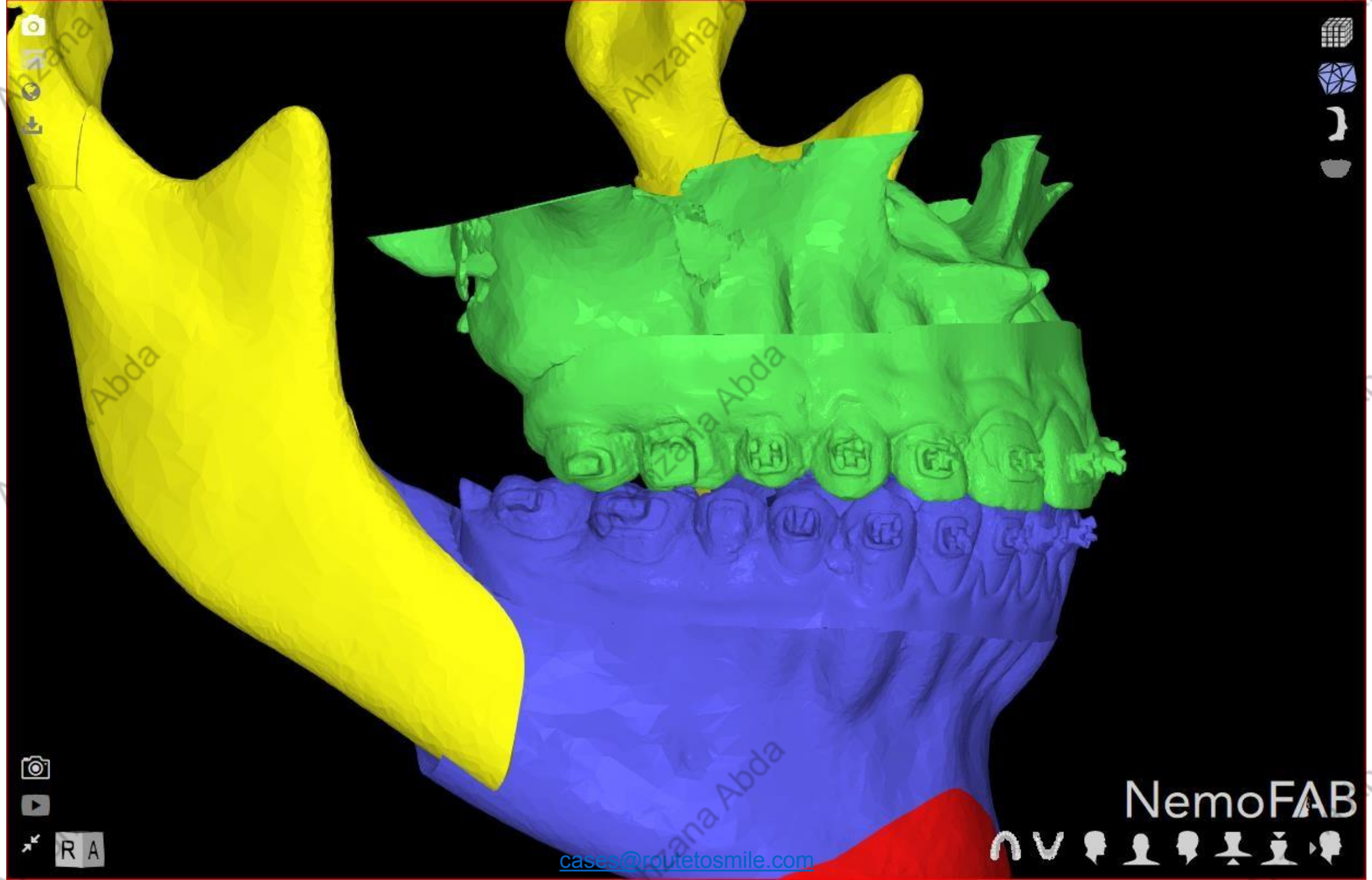
Abda

Abda



A





Dr. M. Zahana

Abda

Dr. A.

Ahzana

Zahana Abda

Zahana Abda

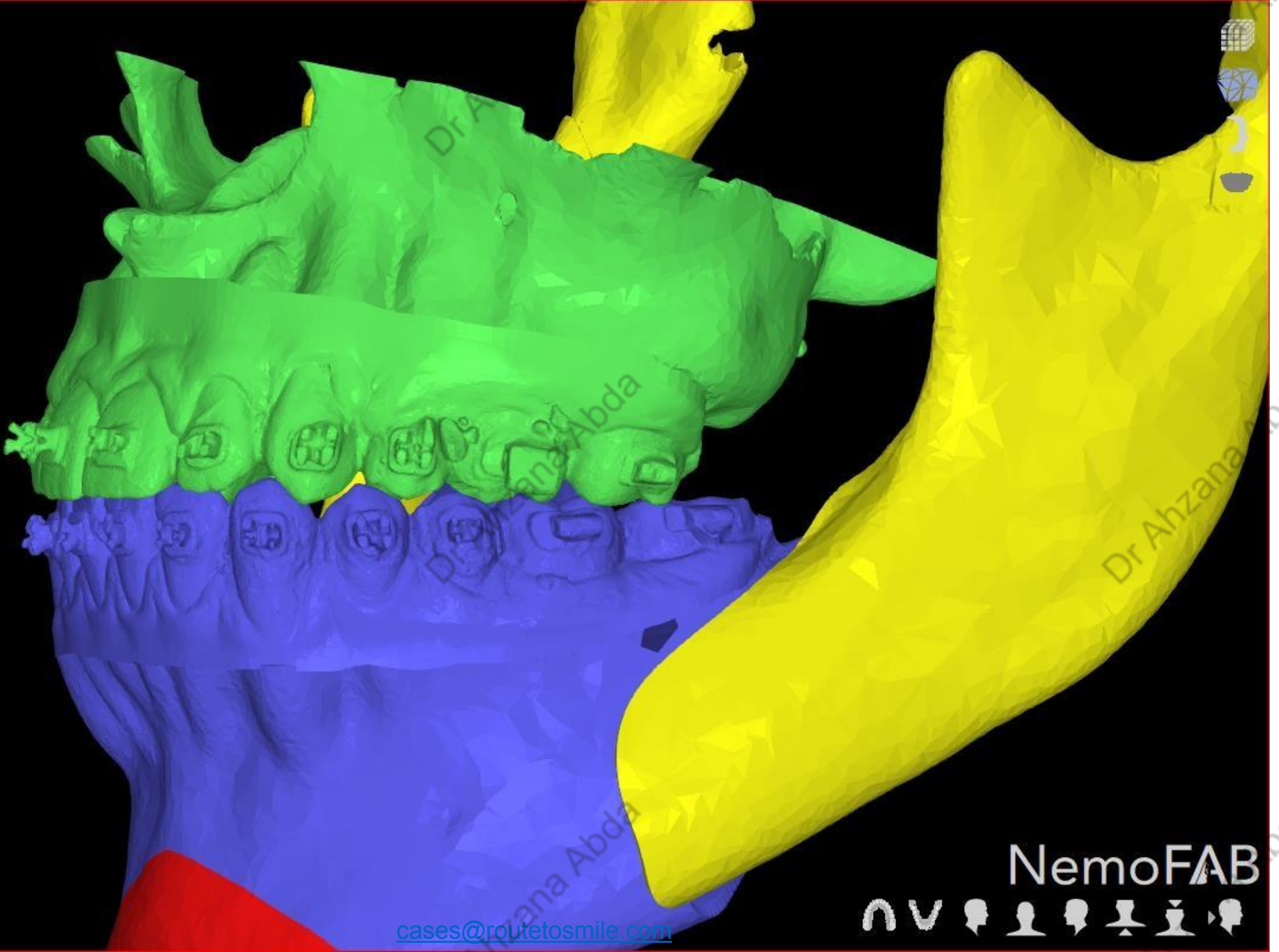


RA

[cases@routetosmile.com](mailto:cases@routetosmile.com)

NemoFAB





Dr A

Dr A

Dr Ahzana Abda

Dr Ahzana Abda

Dr Ahzana Abda

Dr Ahzana Abda

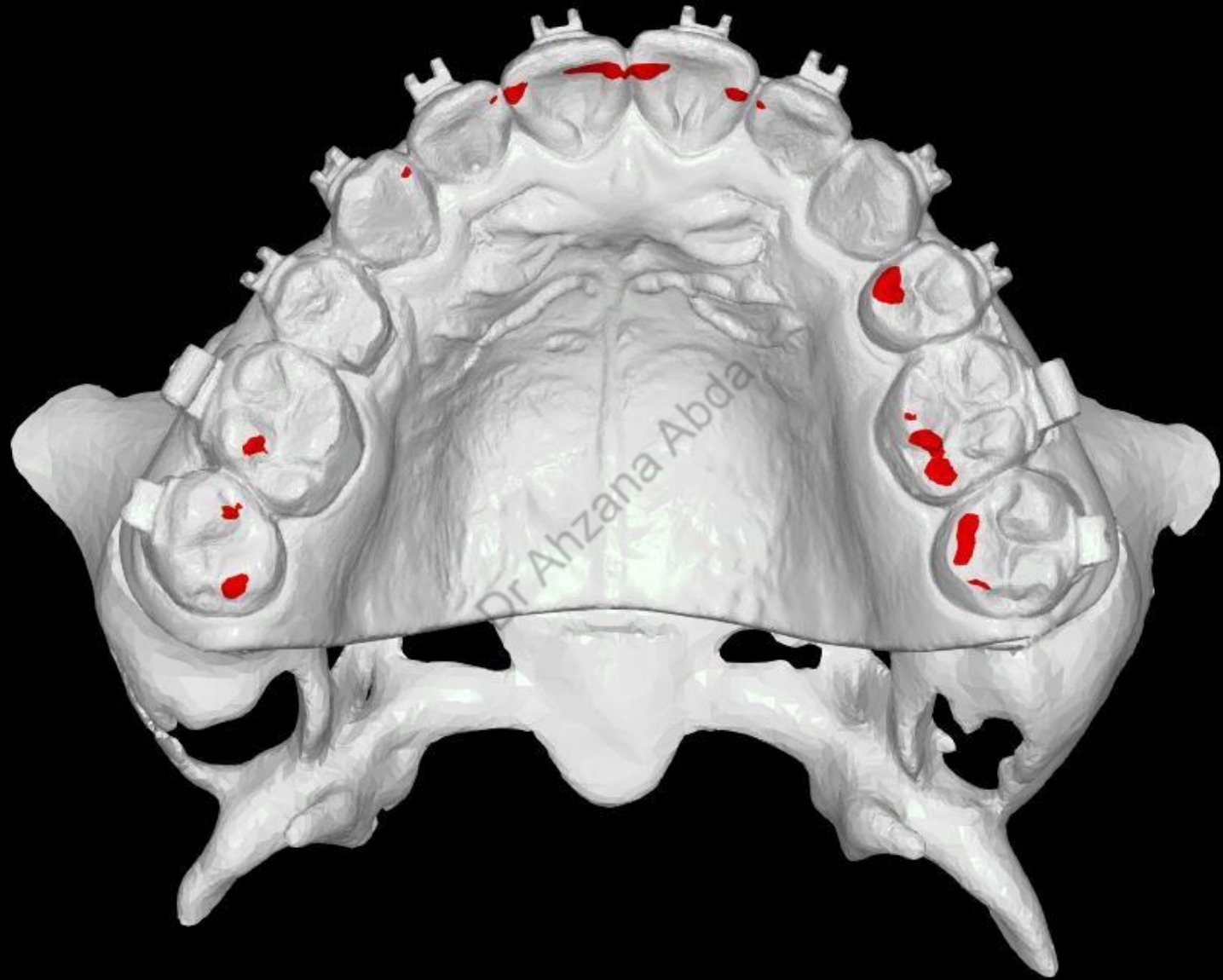


AL

[cases@routetosmile.com](mailto:cases@routetosmile.com)

NemoFAB





Dr Ahzana Abda

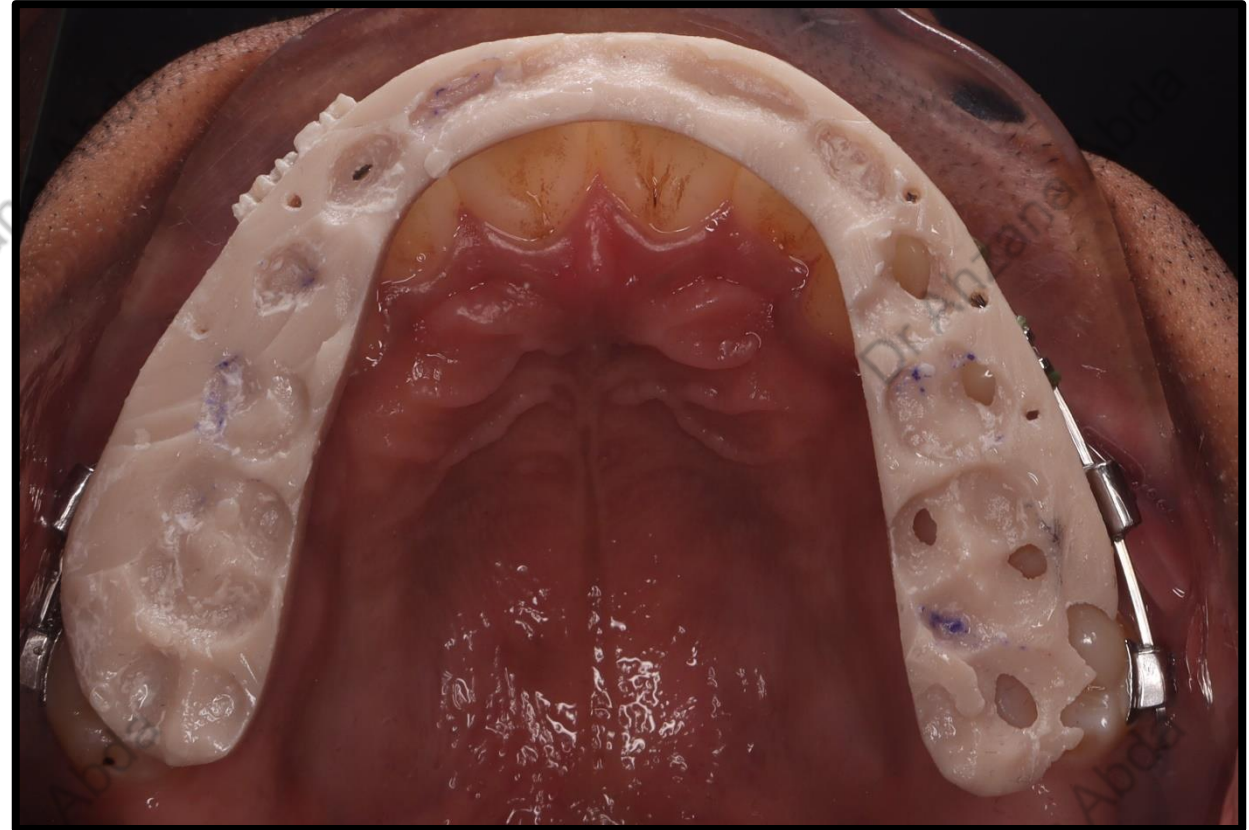
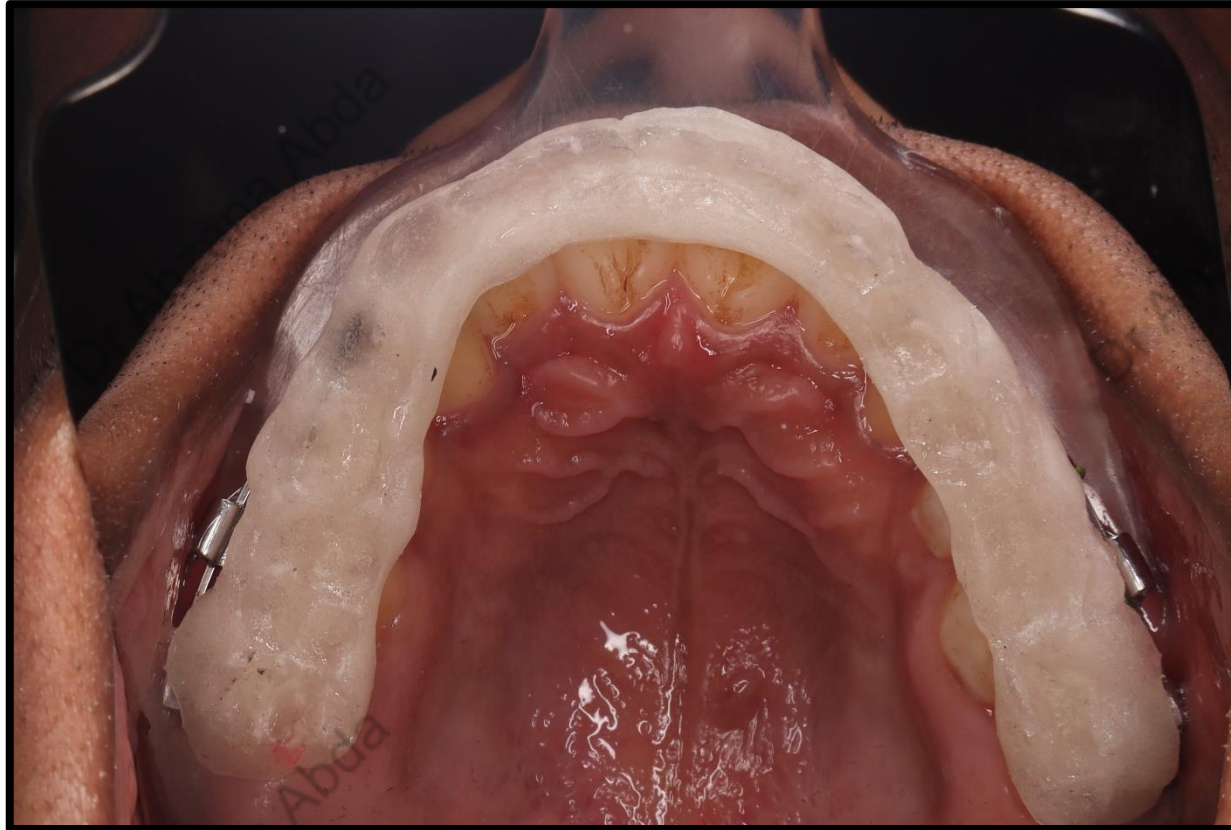NemoFAB



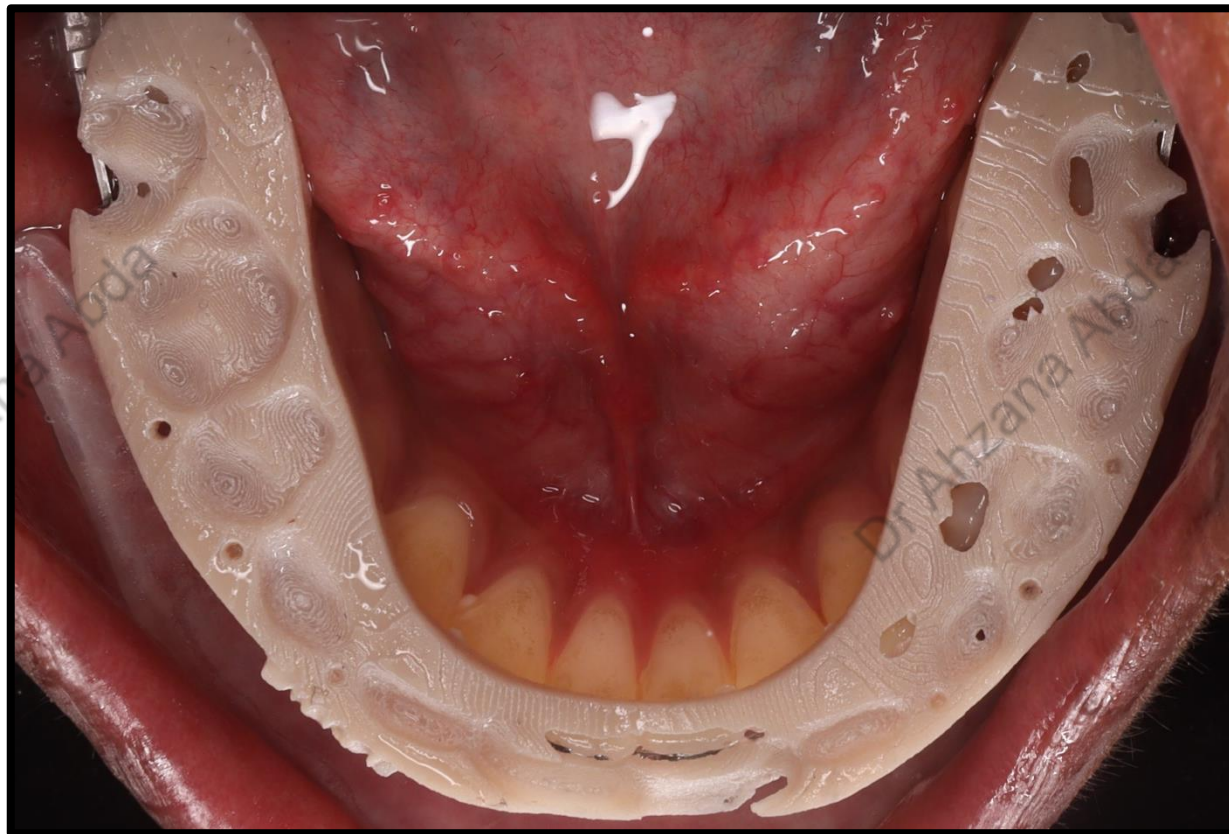
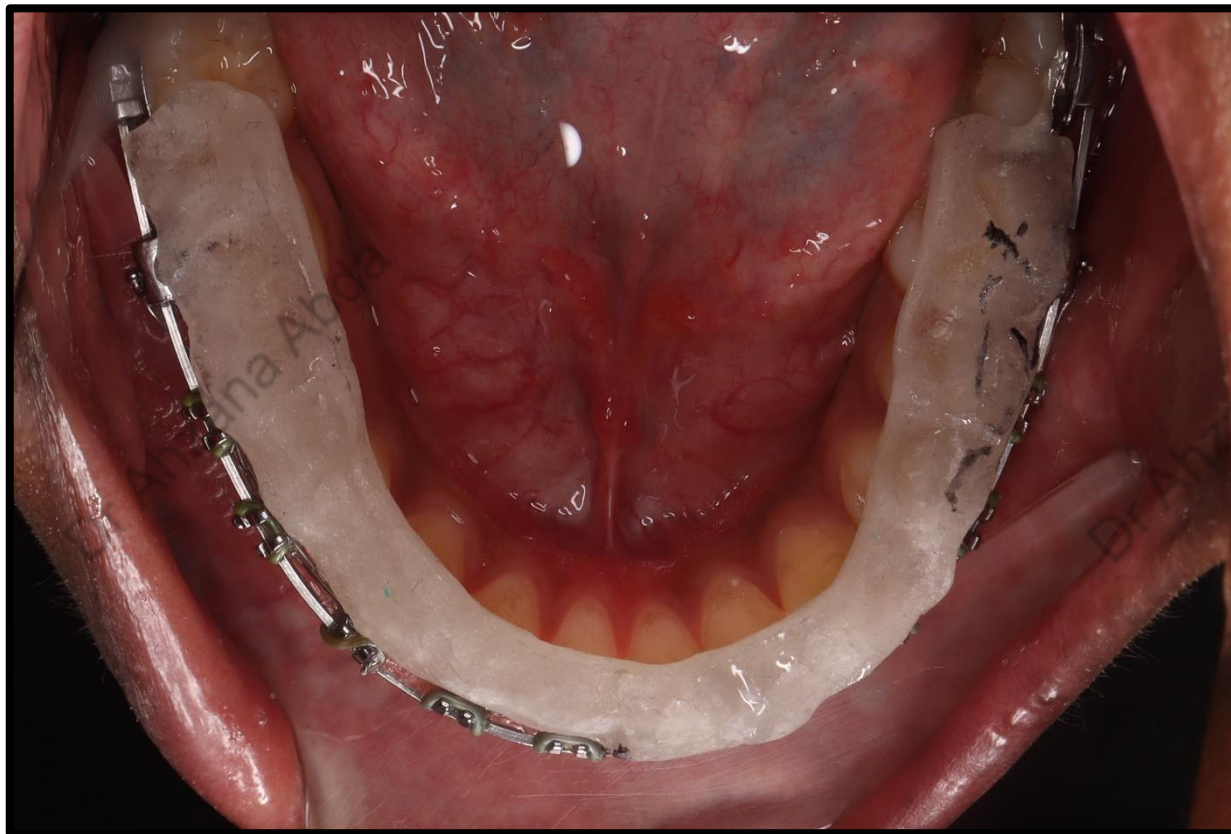
Dr A

Abda

## 3D VERSUS MANUAL INTERMEDIATE SPLINT

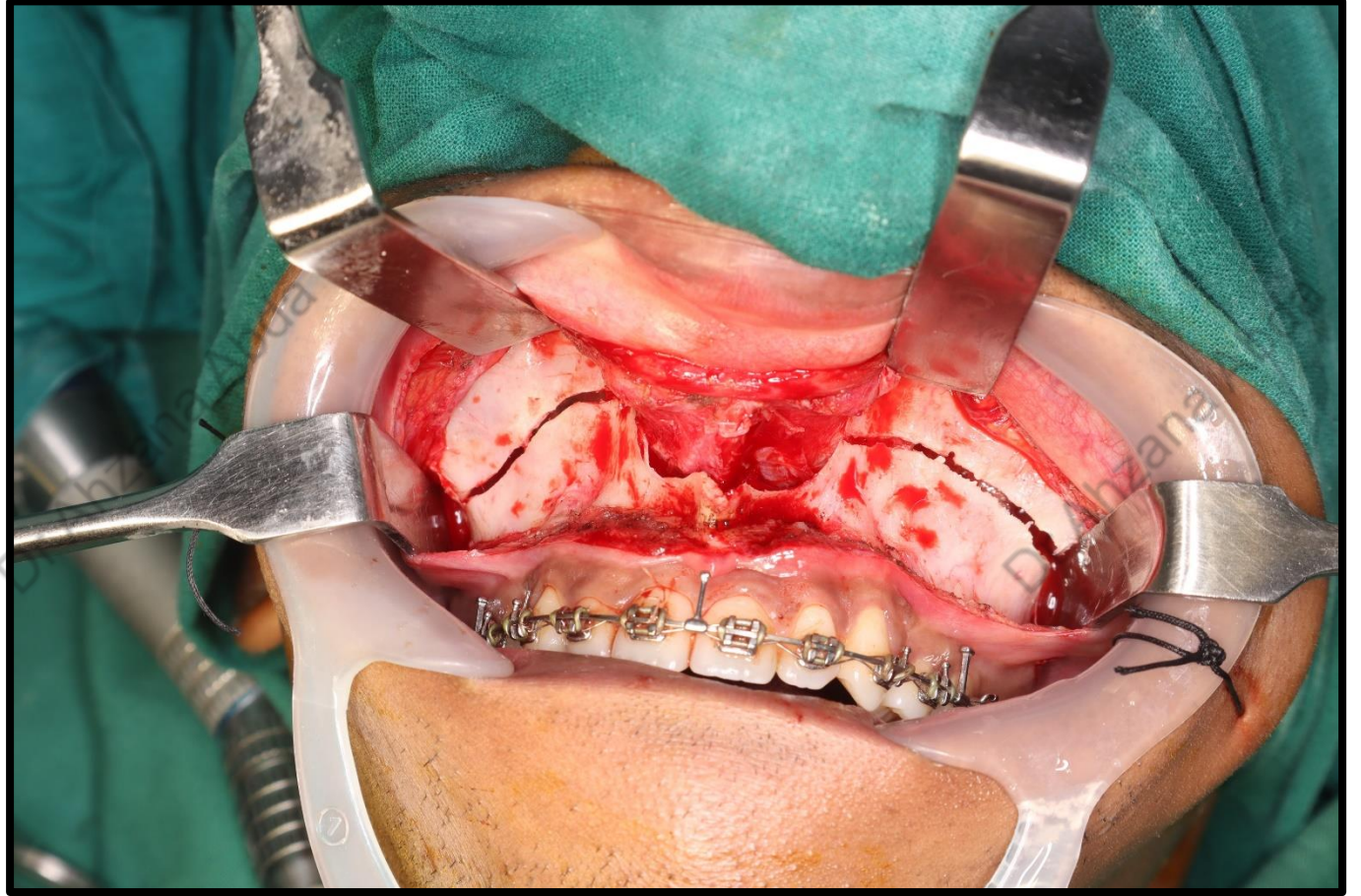
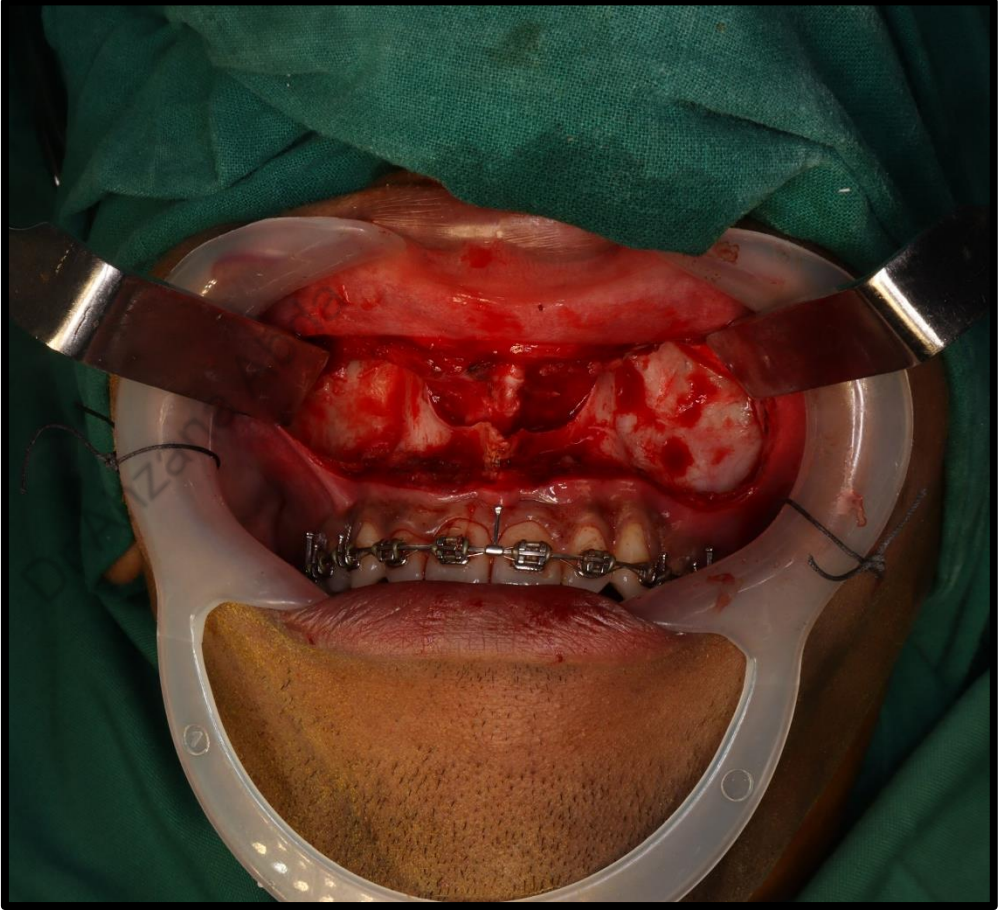


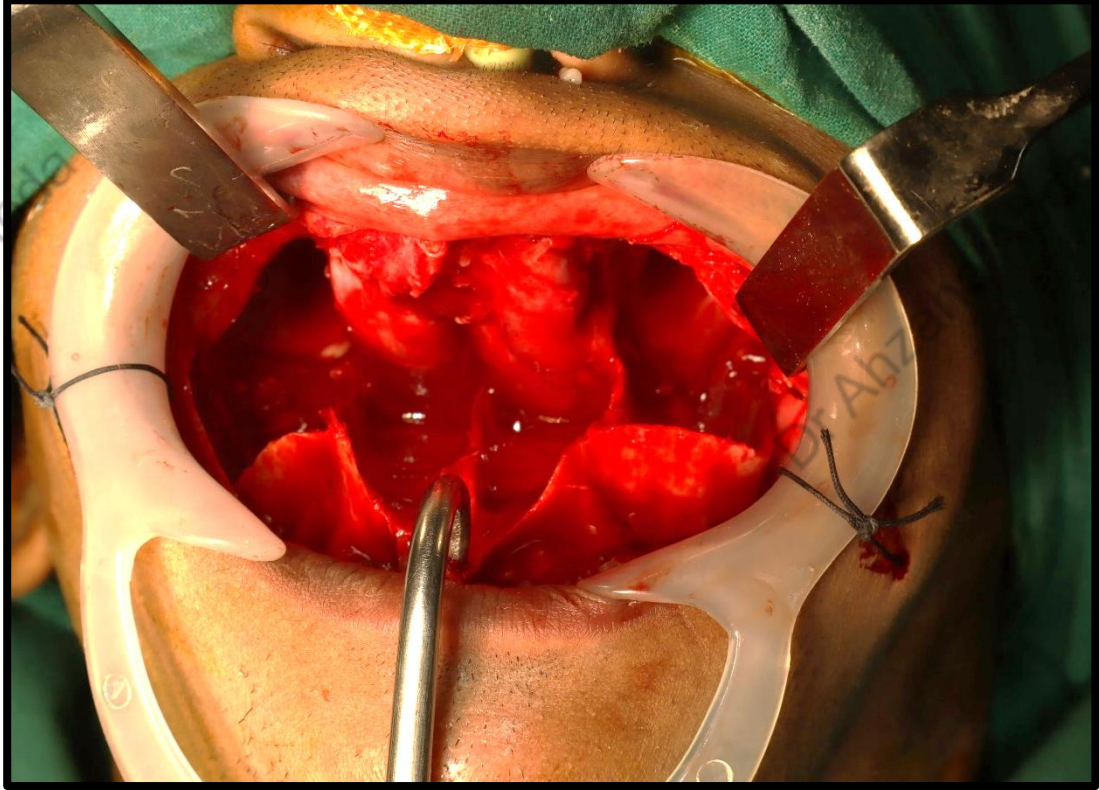
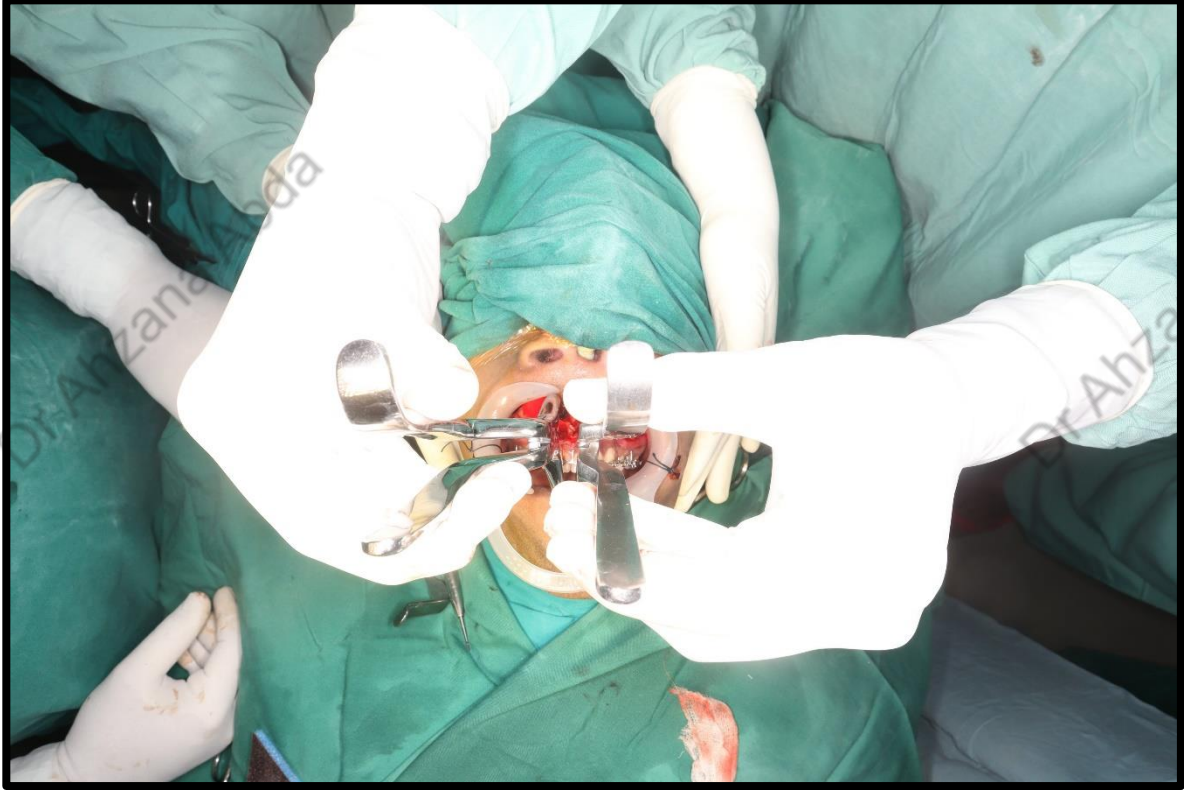## 3D VERSUS MANUAL FINAL SPLINT



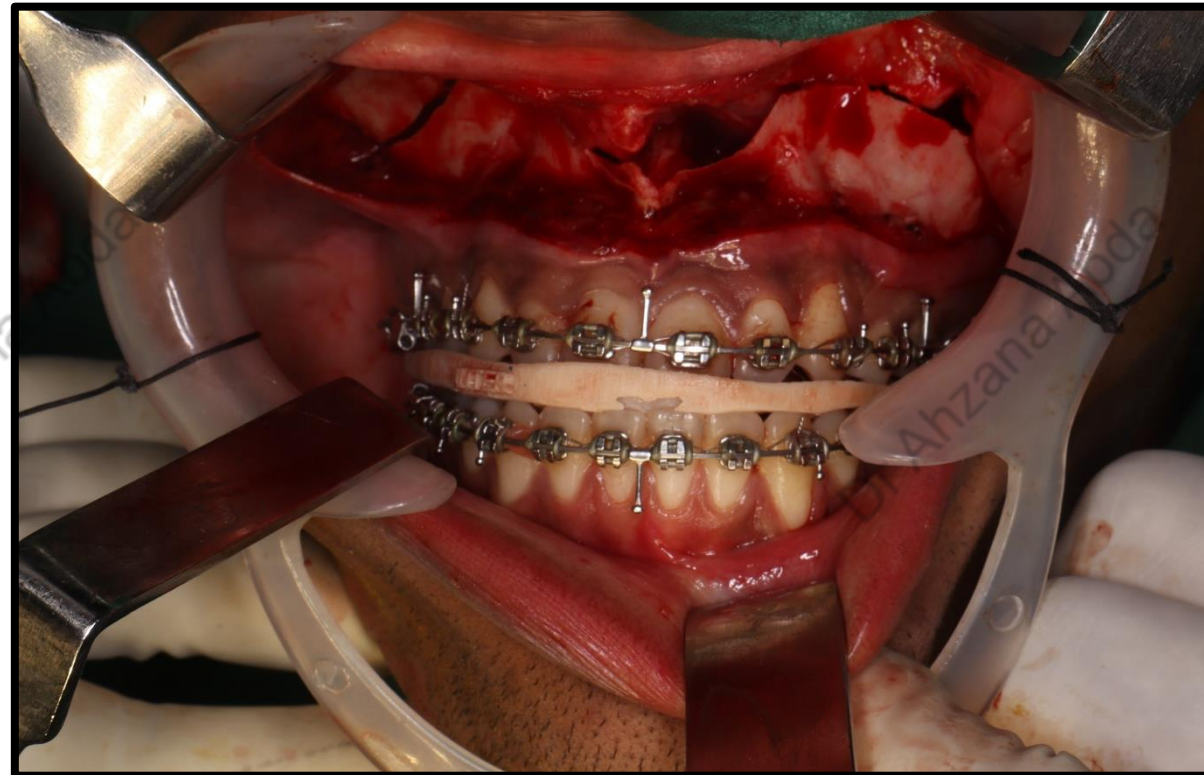
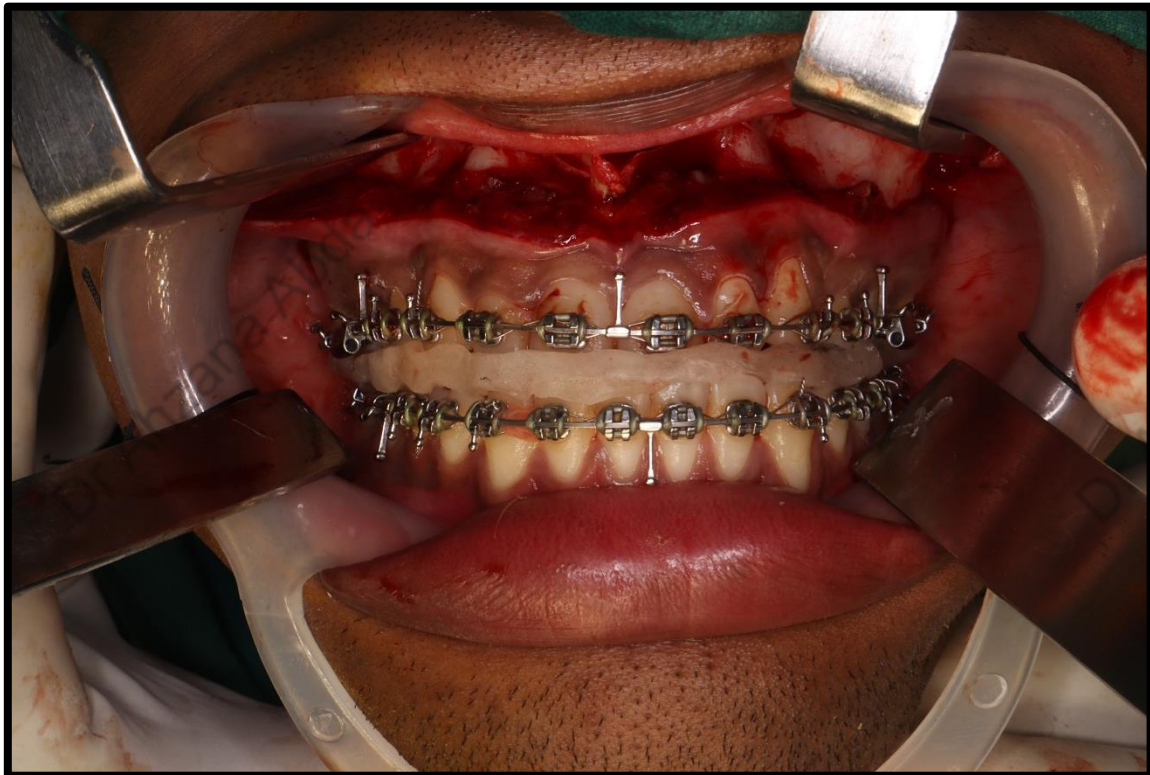


# SURGICAL PROCEDURES

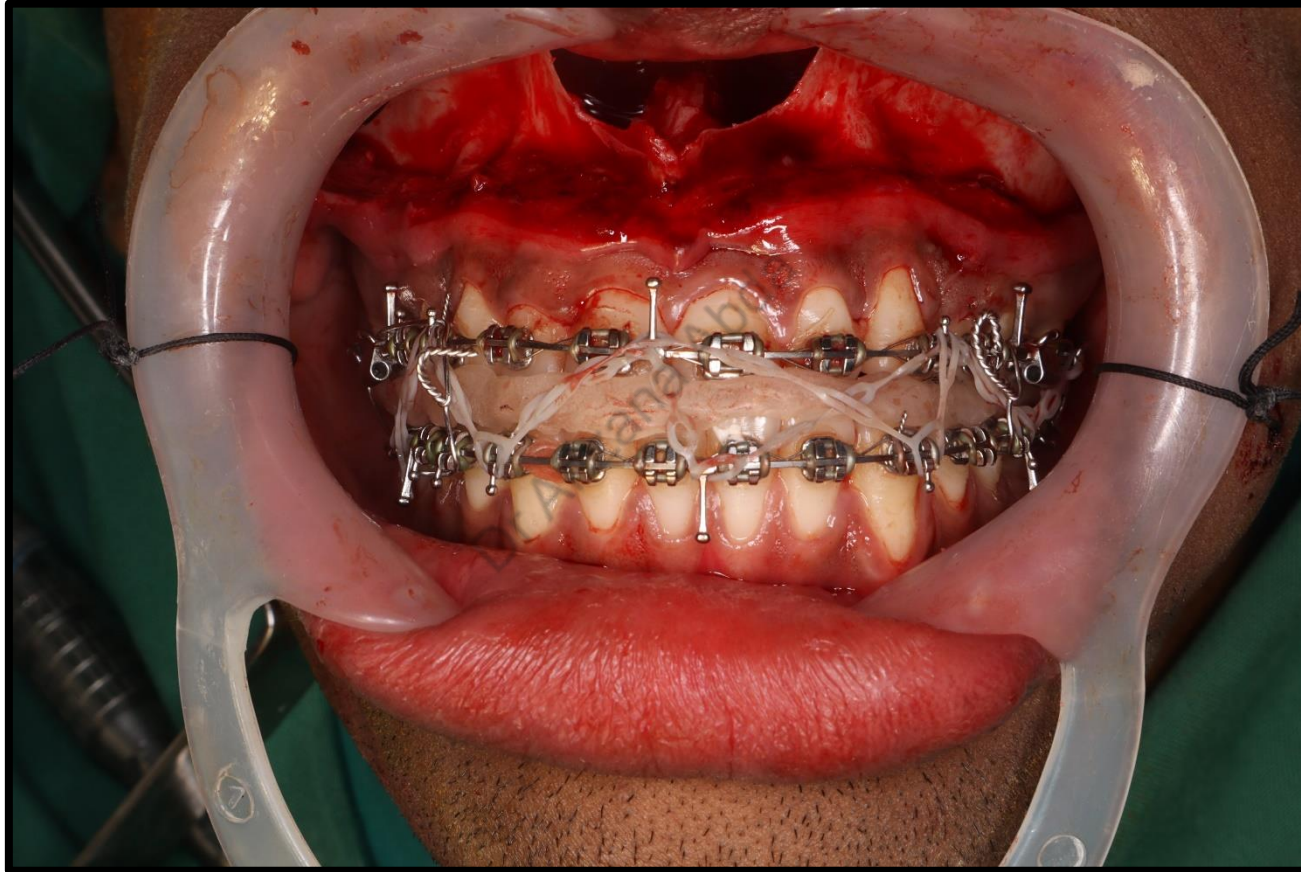


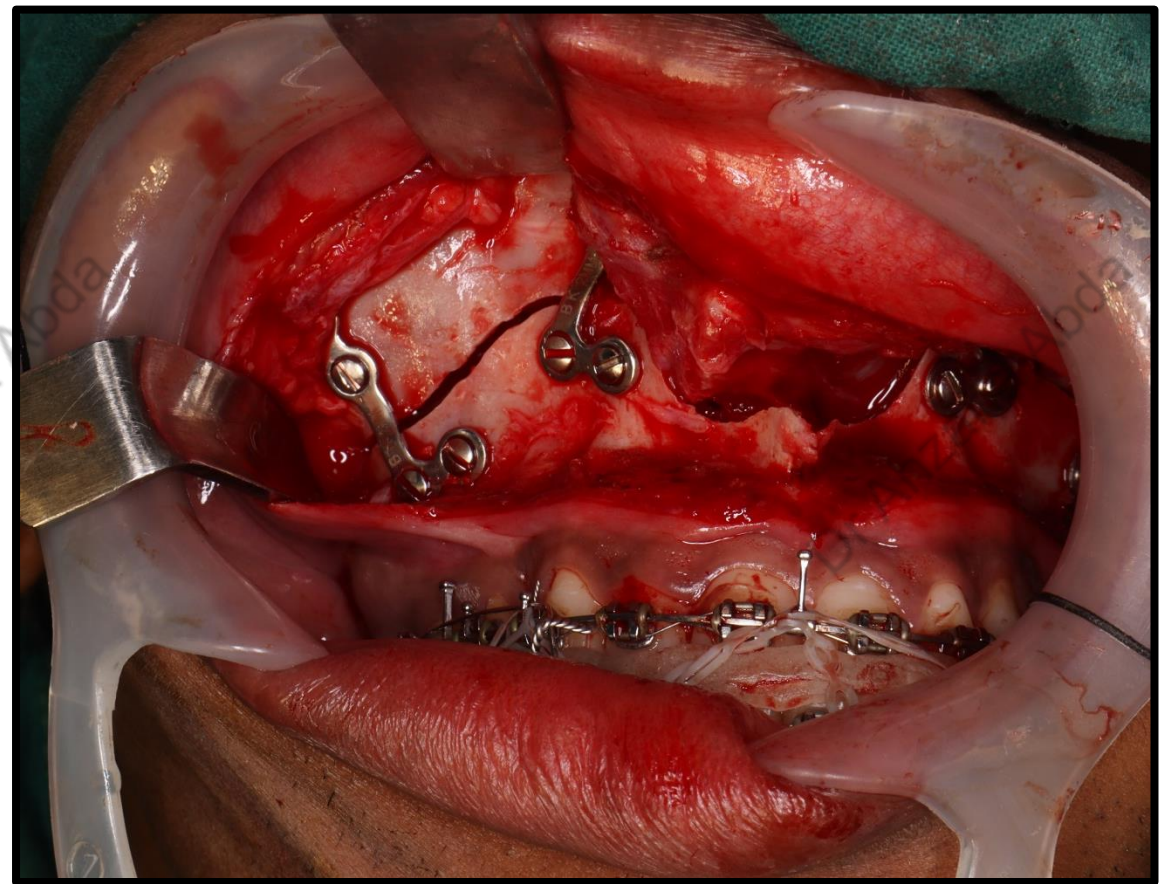
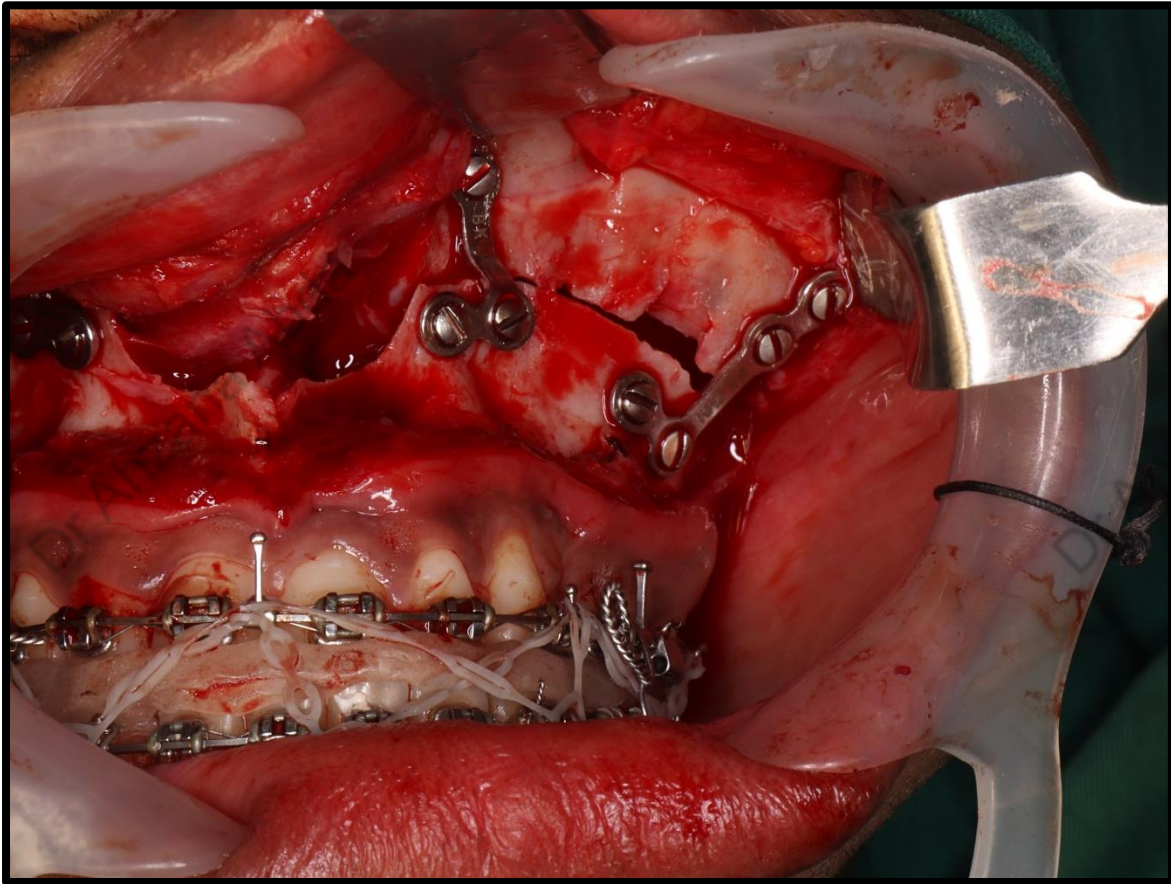


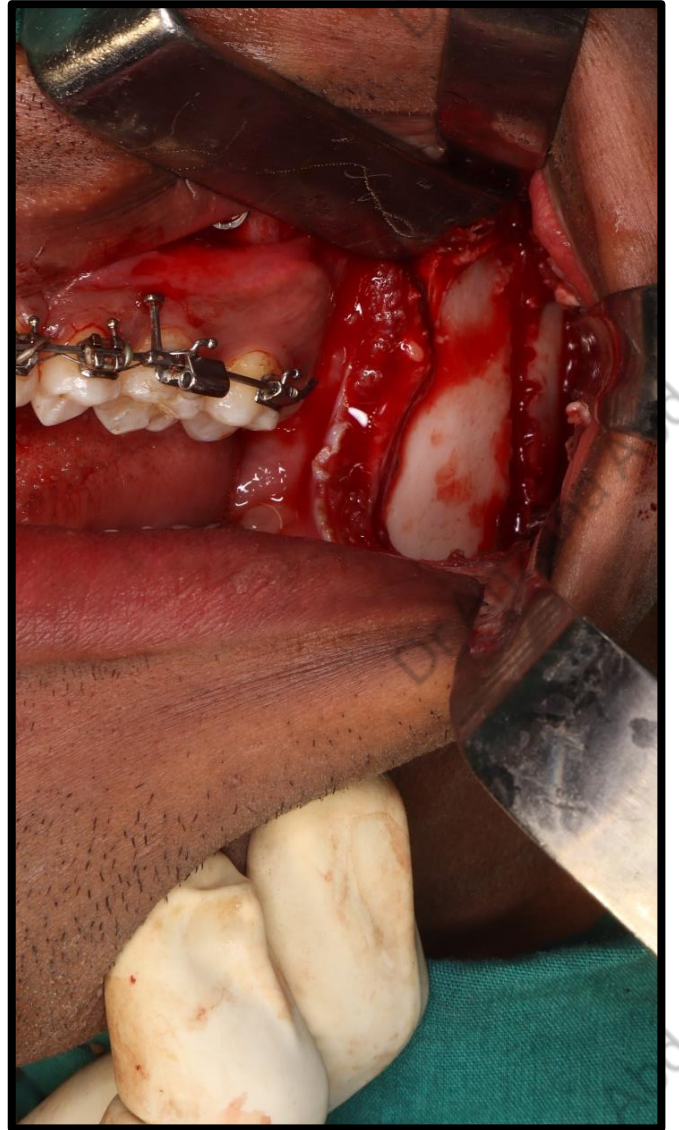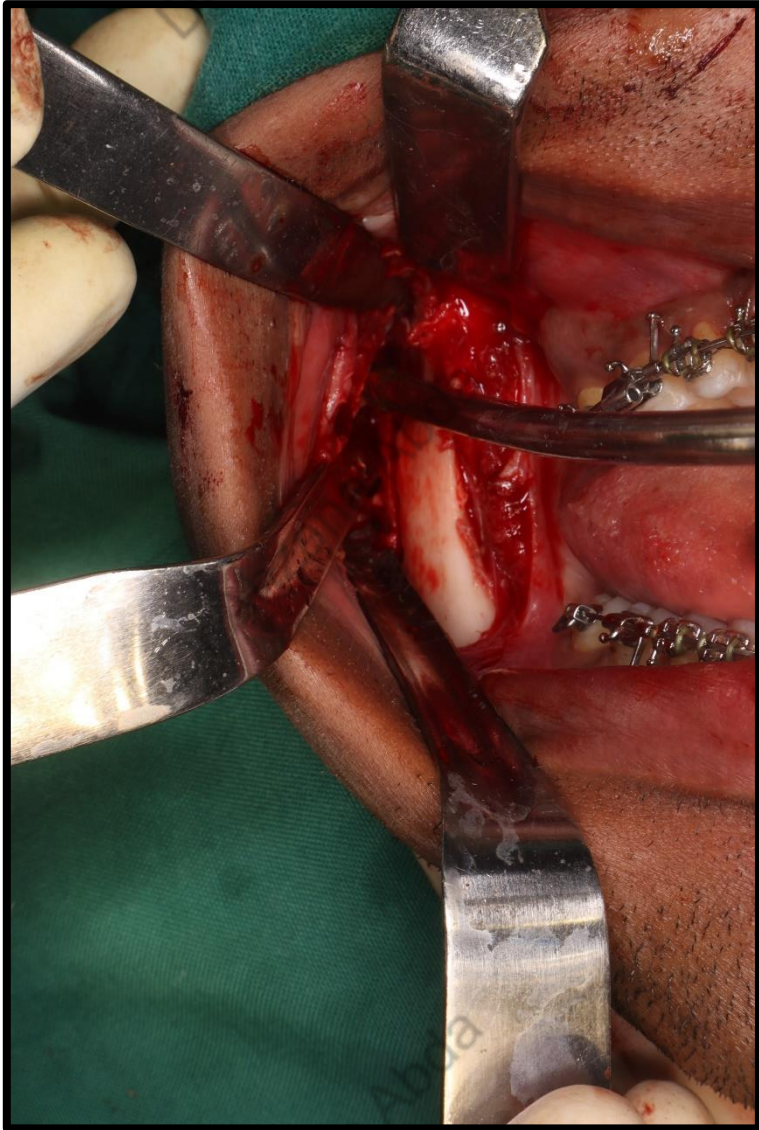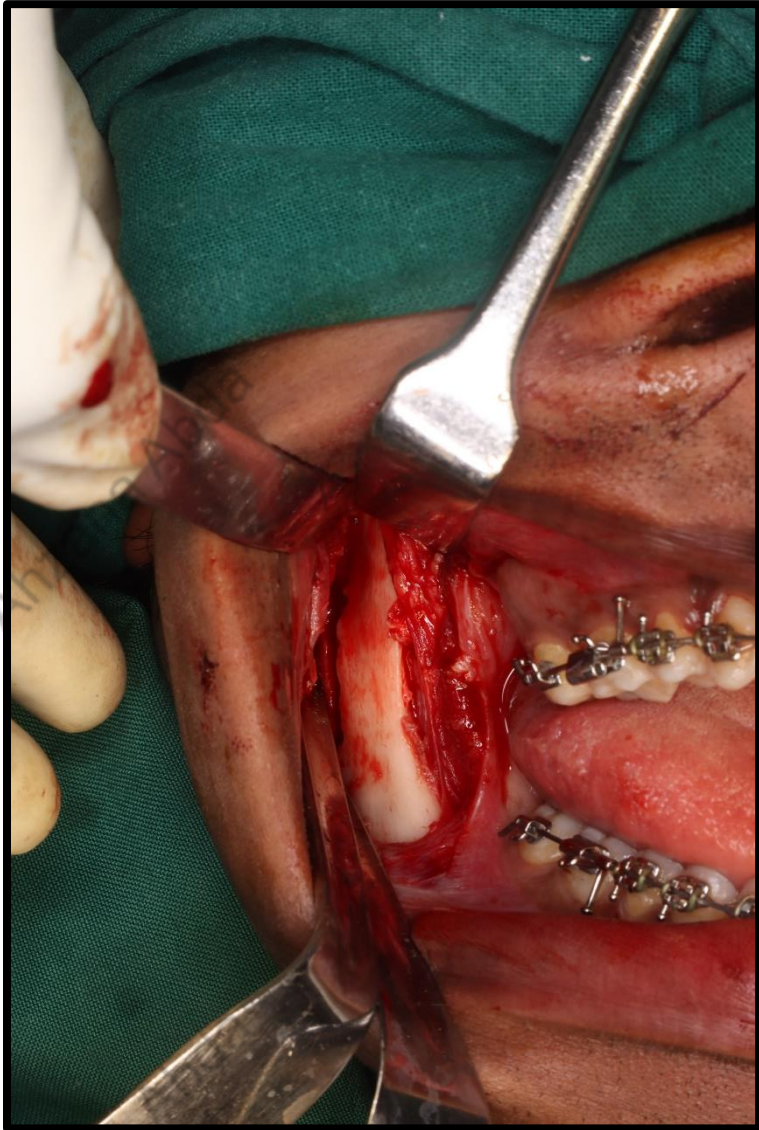
# INTERMEDIATE SPLINT

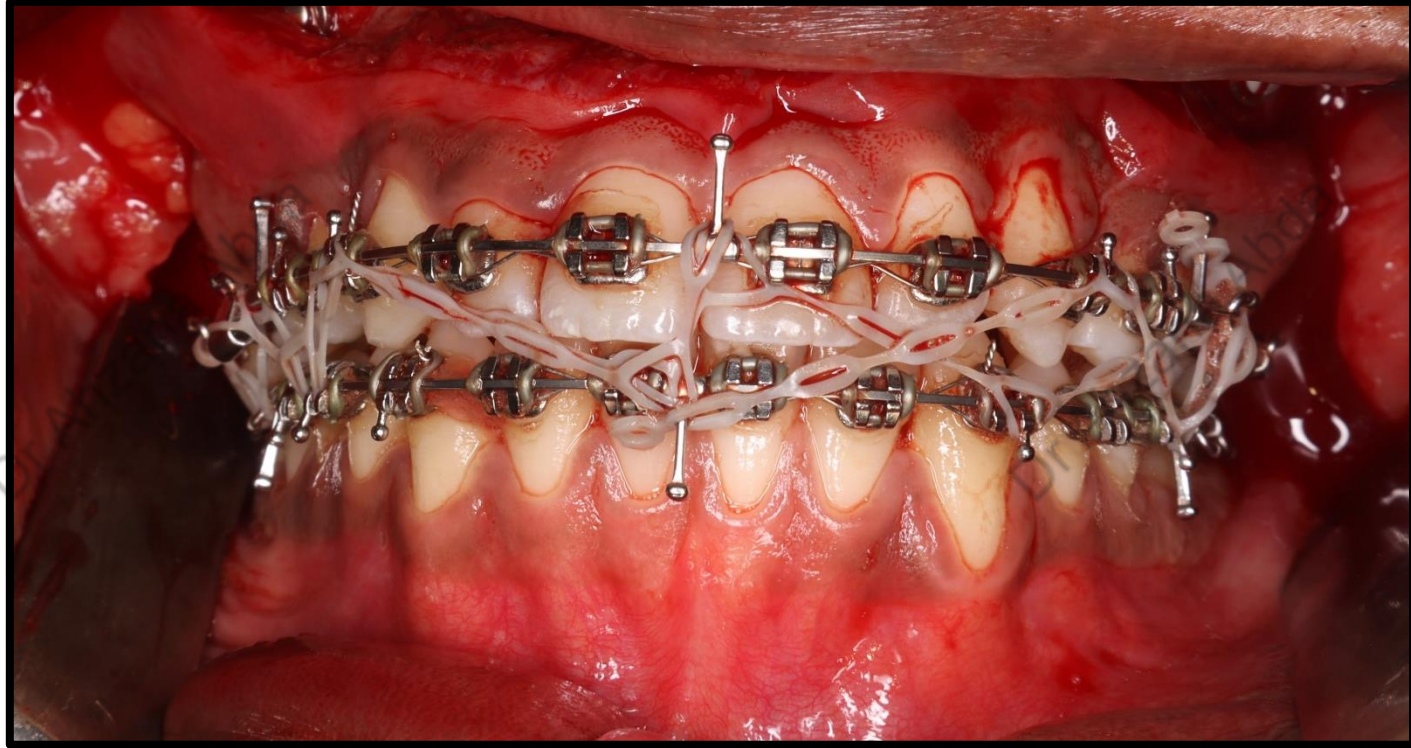
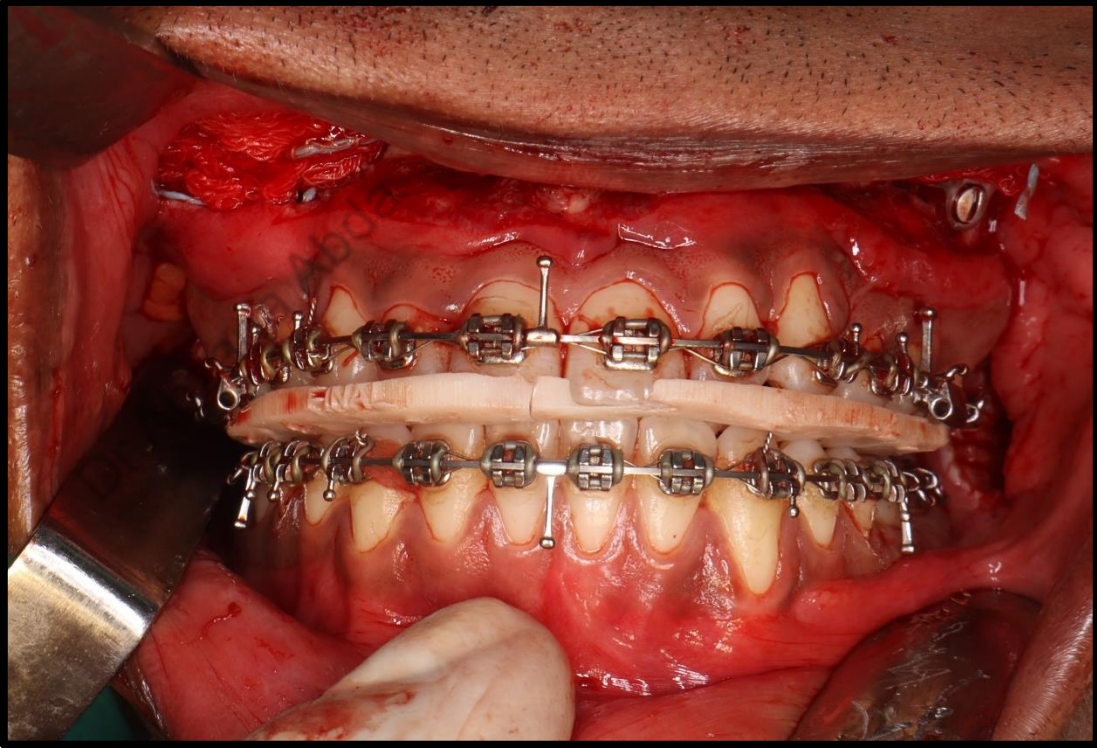


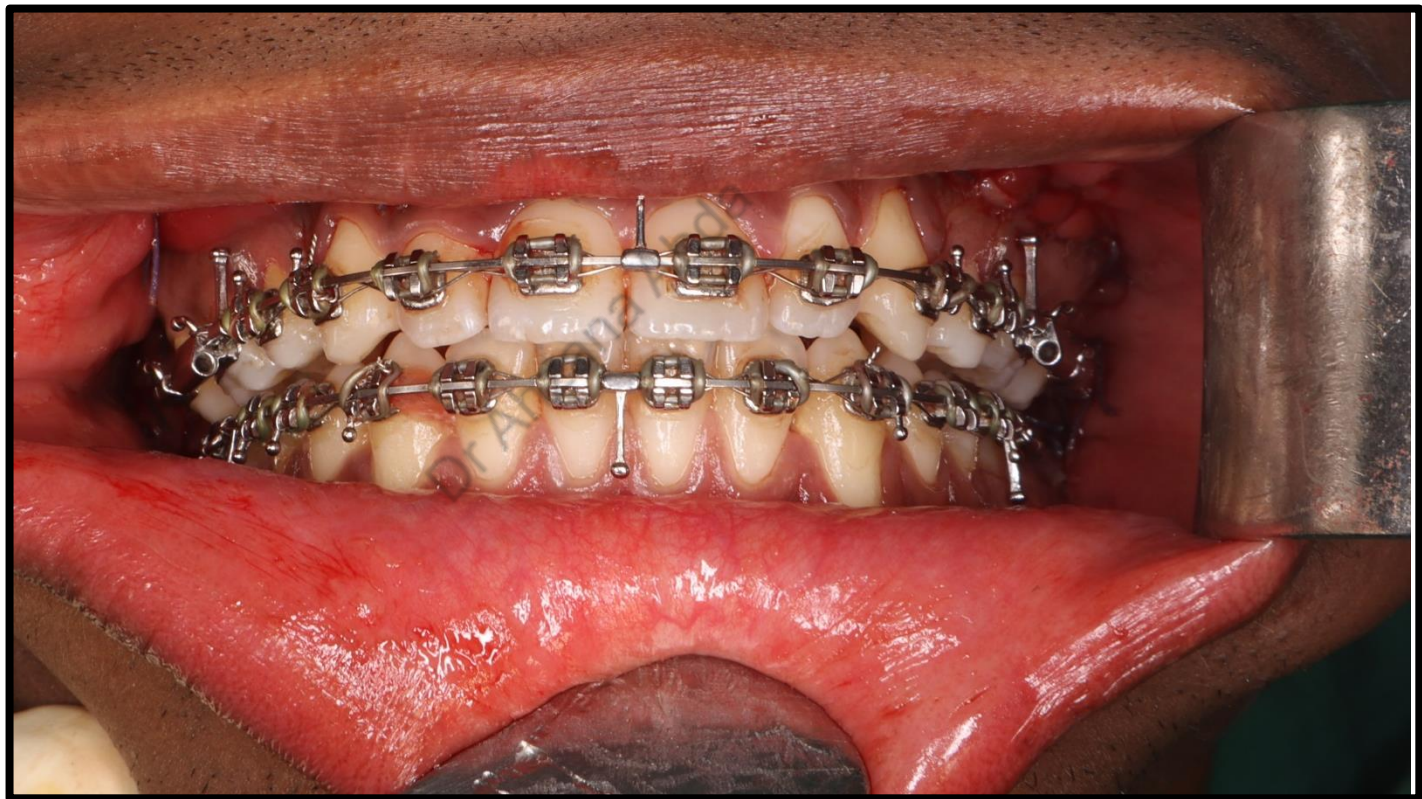
**IMF**







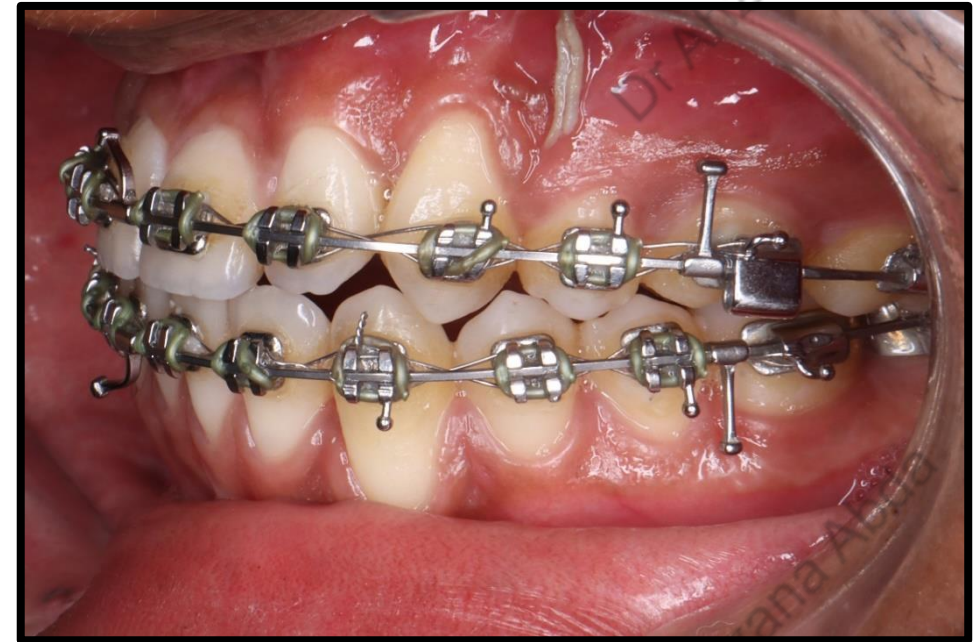
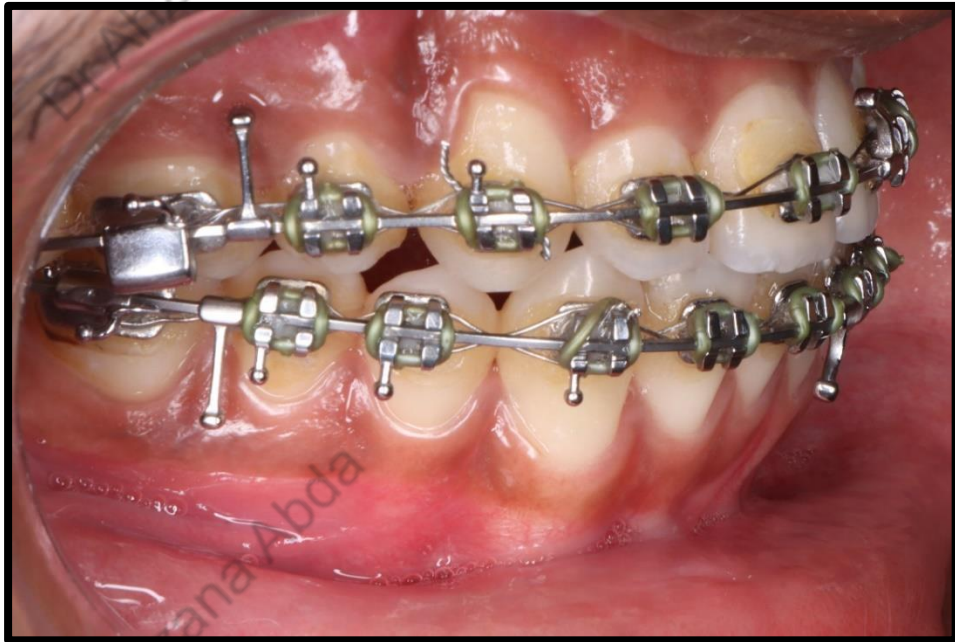
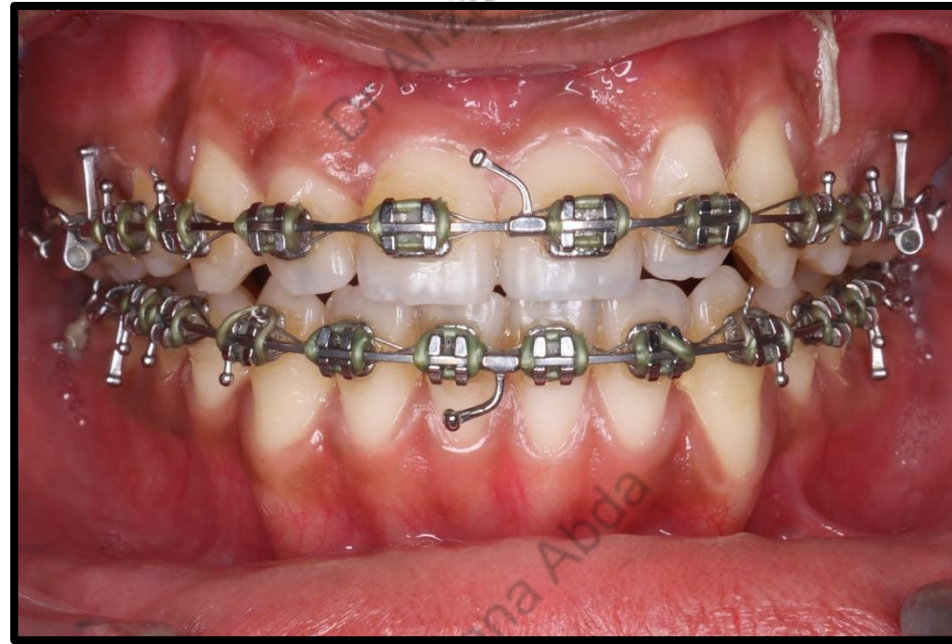



# POST SURGERY EXTRA ORAL PHOTOGRAPHS



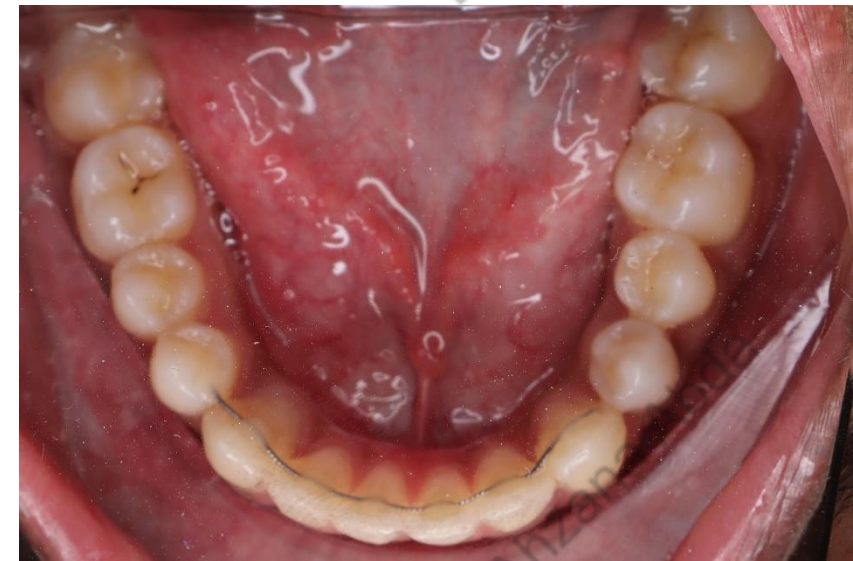
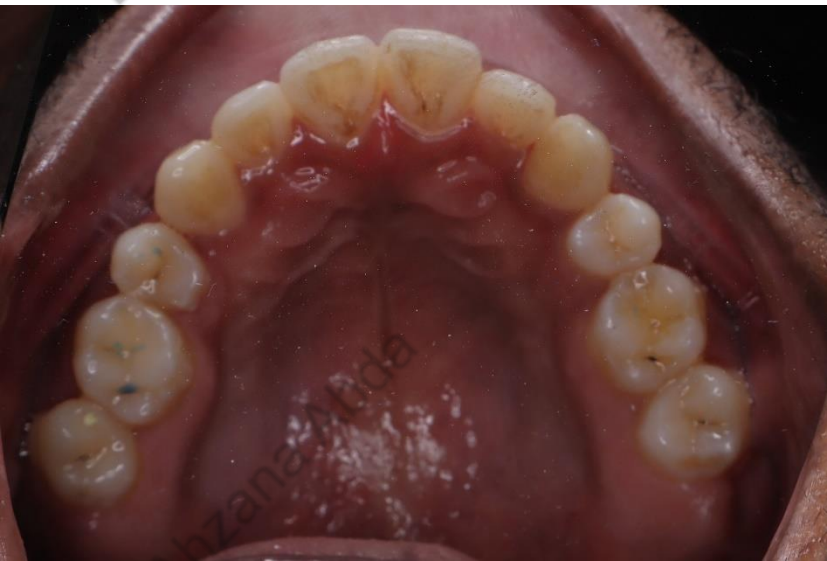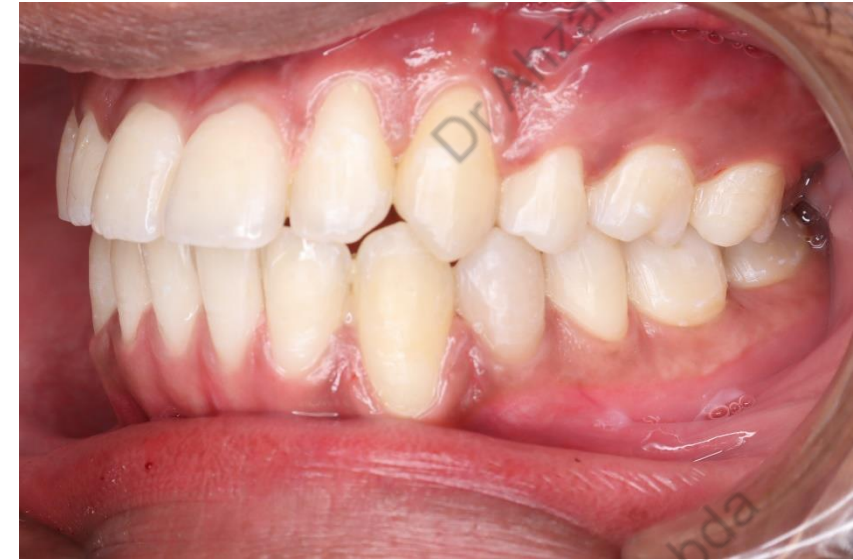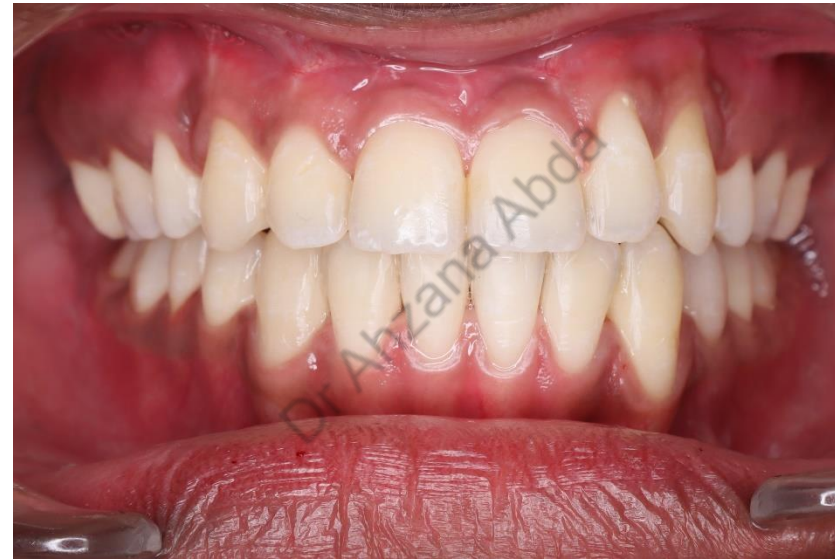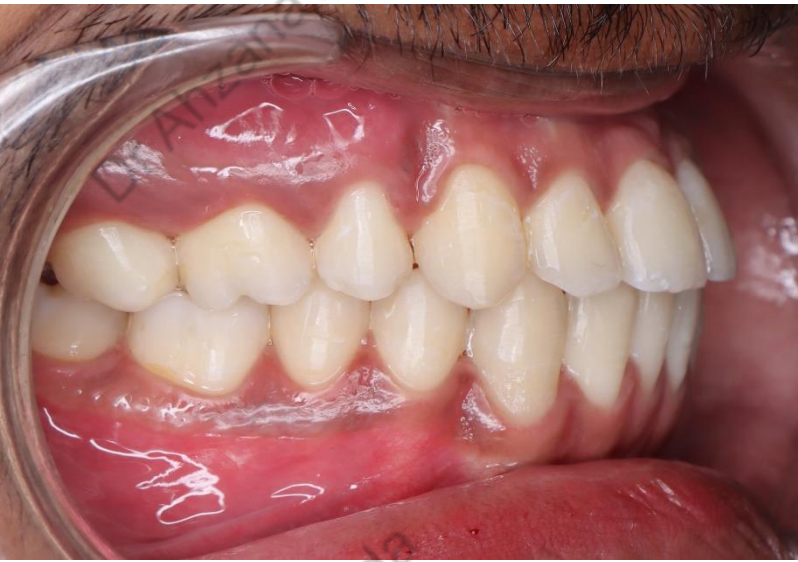# POST SURGERY INTRA ORAL PHOTOGRAPHS



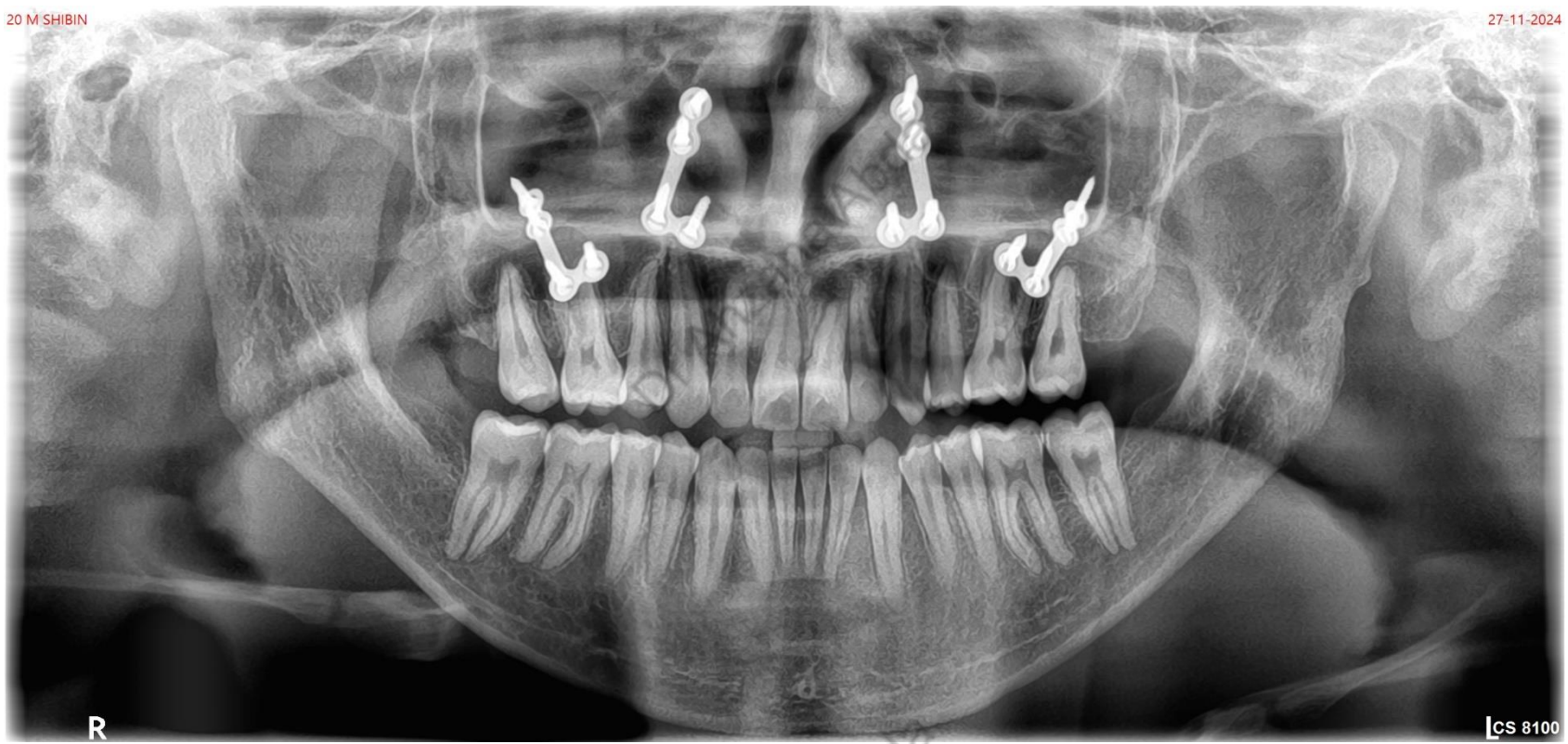
**POST TREATMENT EXTRA ORAL  
PHOTOGRAPHS**



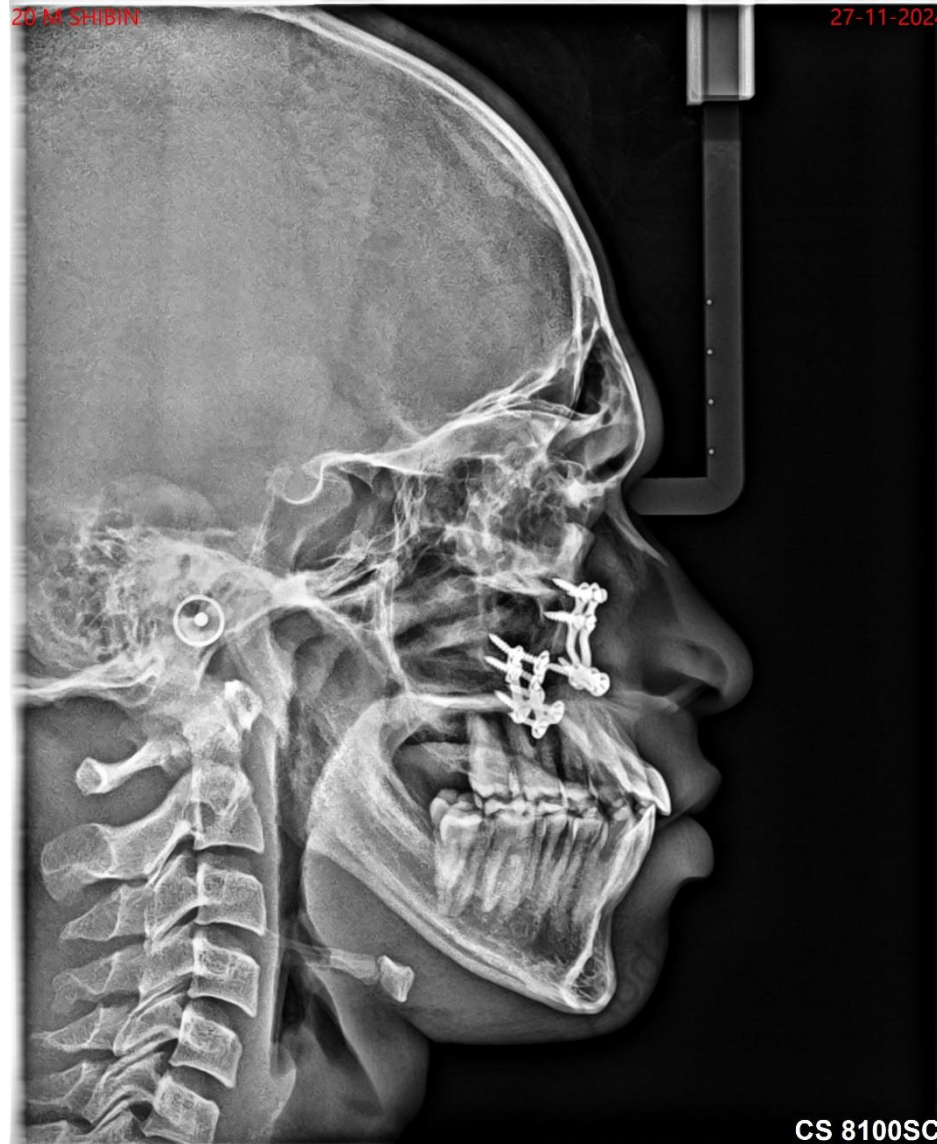# POST TREATMENT INTRA ORAL PHOTOGRAPHS



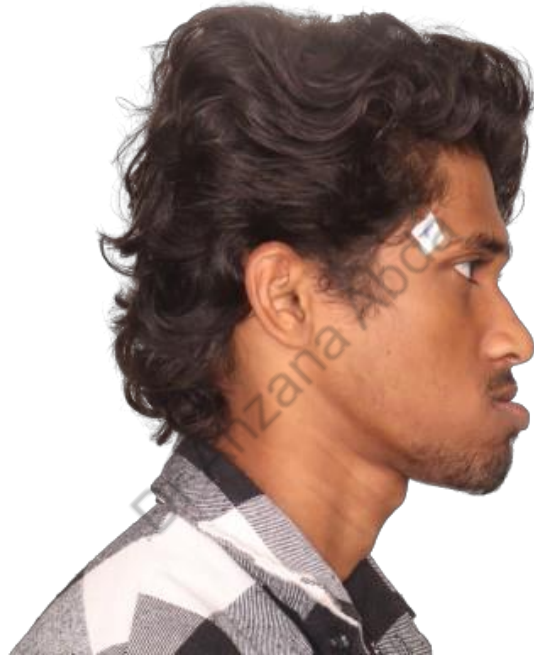# POST TREATMENT OPG



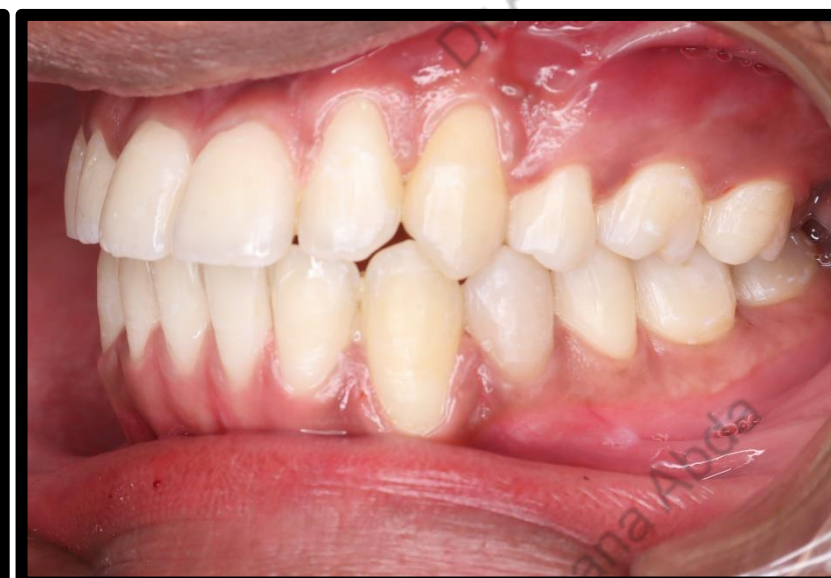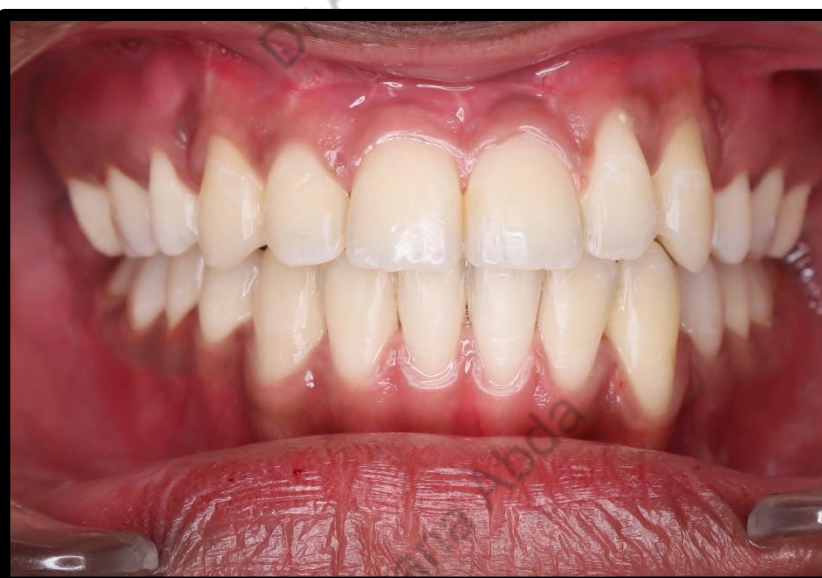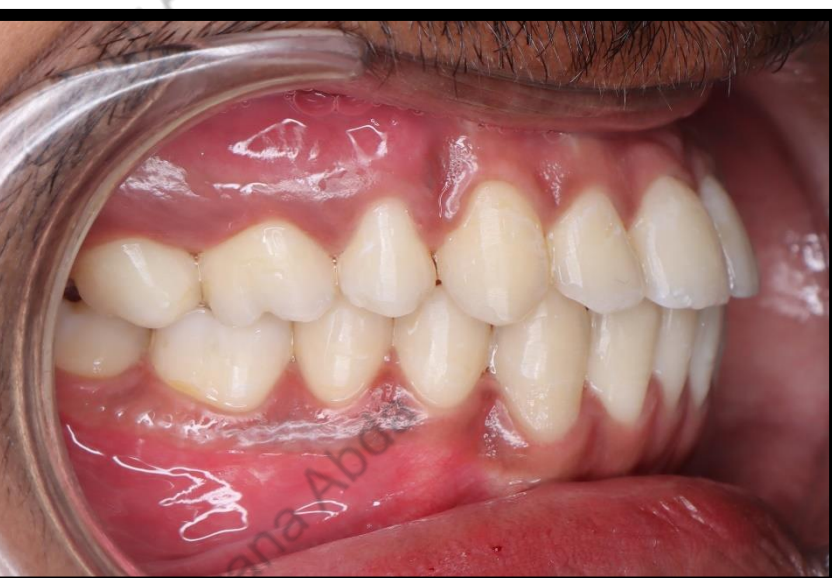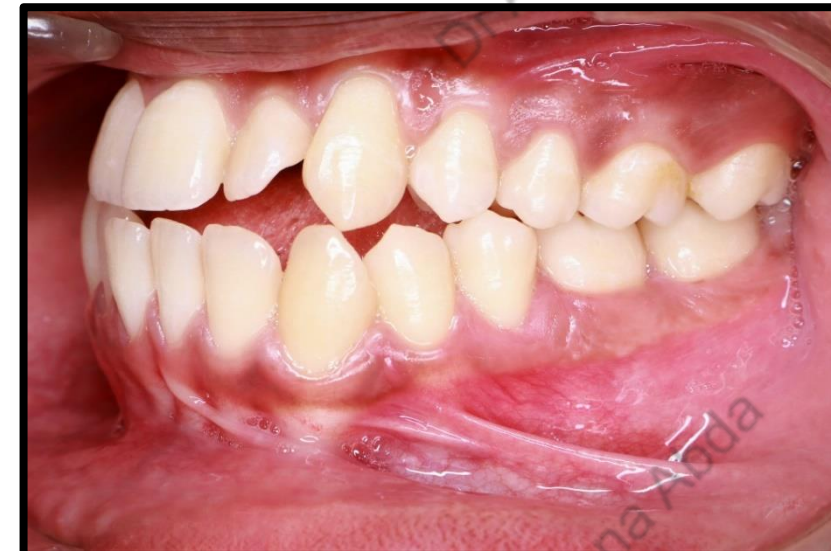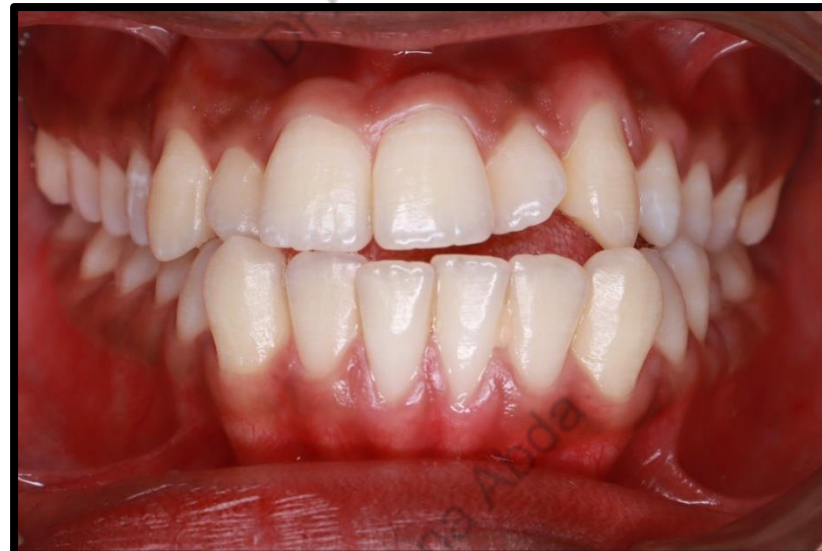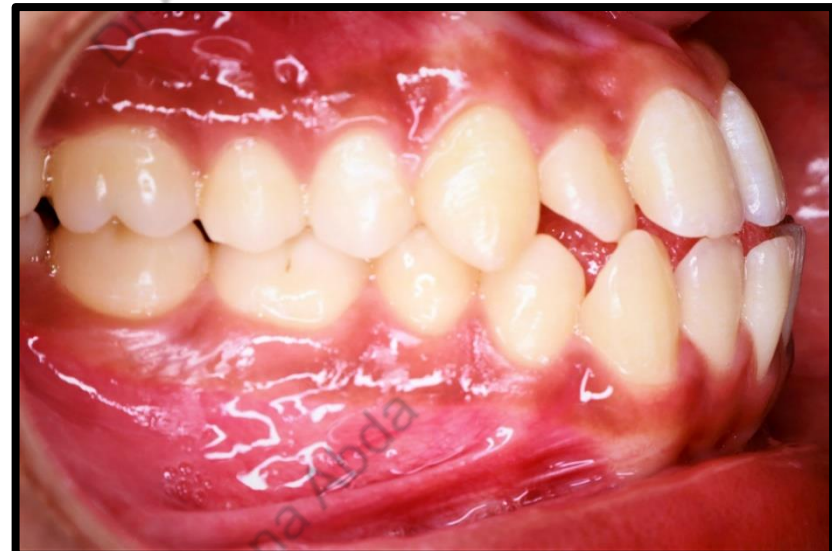# POST TREATMENT LATERAL CEPHALOGRAM



# EXTRA ORAL COMPARISON



# INTRA ORAL COMPARISON



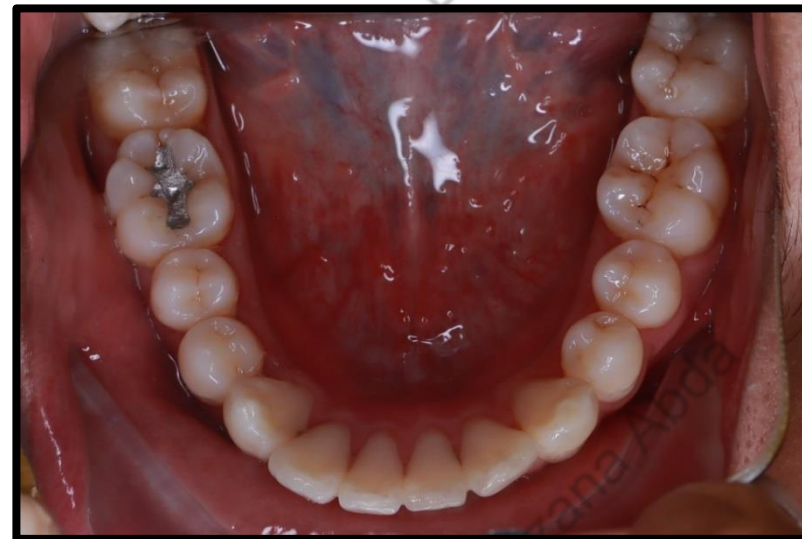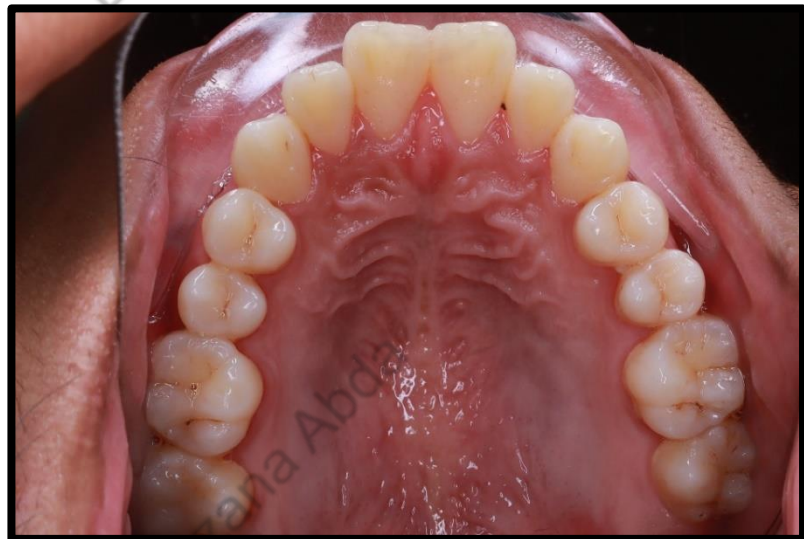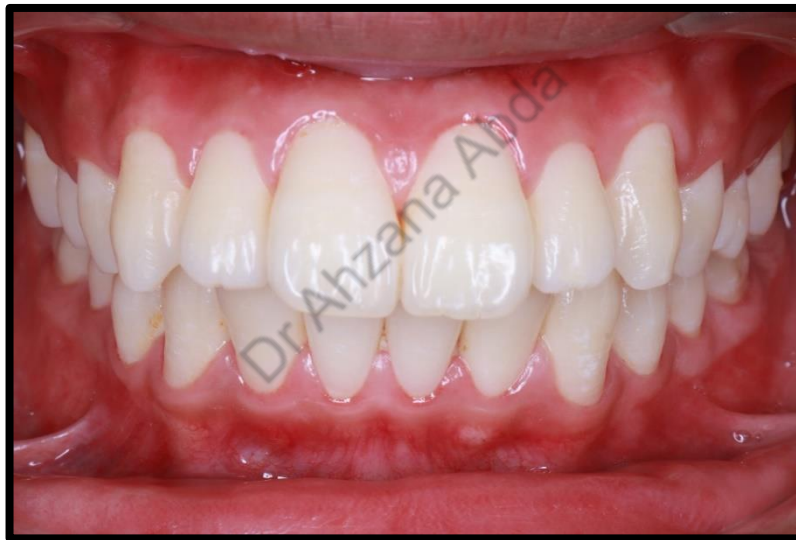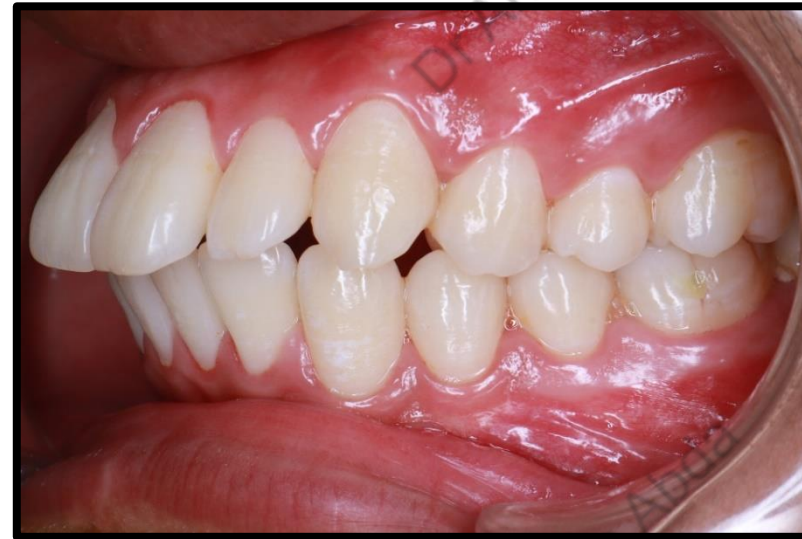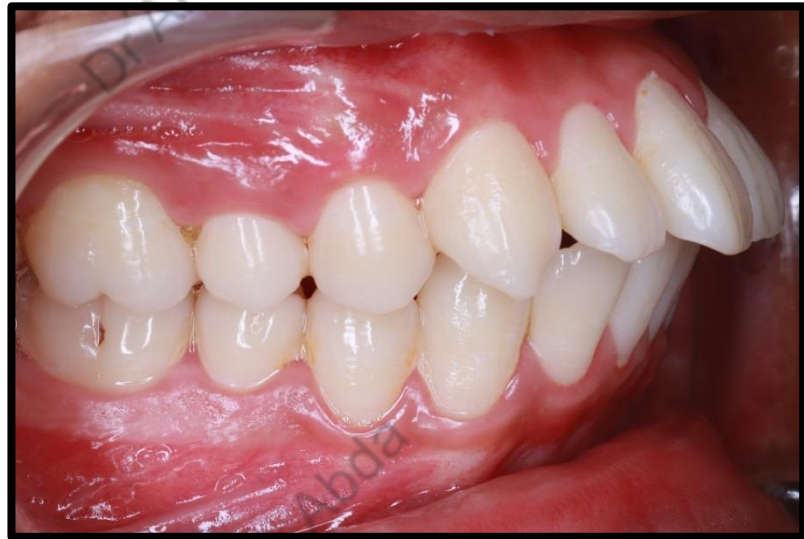# CASE VIII

**SOORAJ /M**

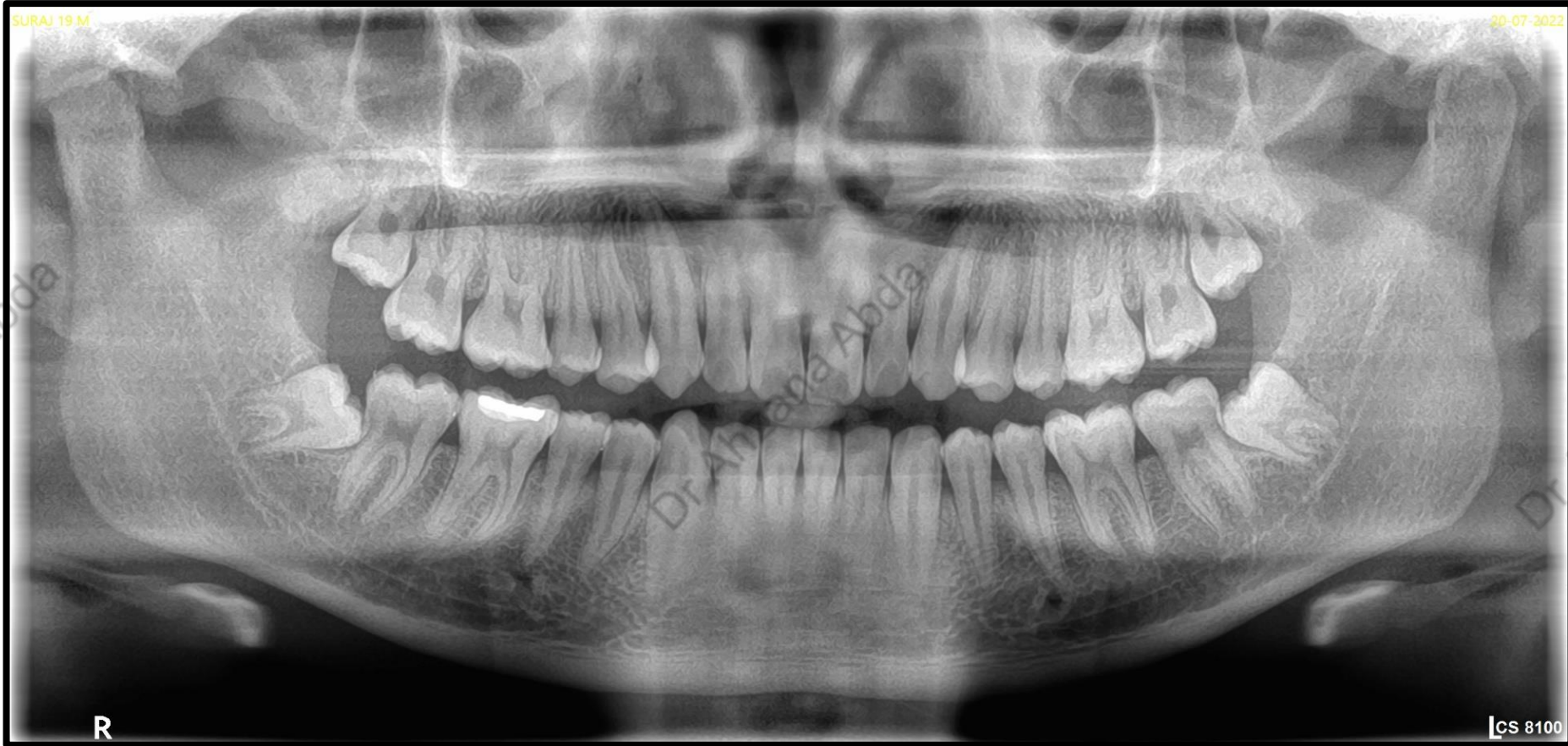
# PRE TREATMENT EXTRAORAL



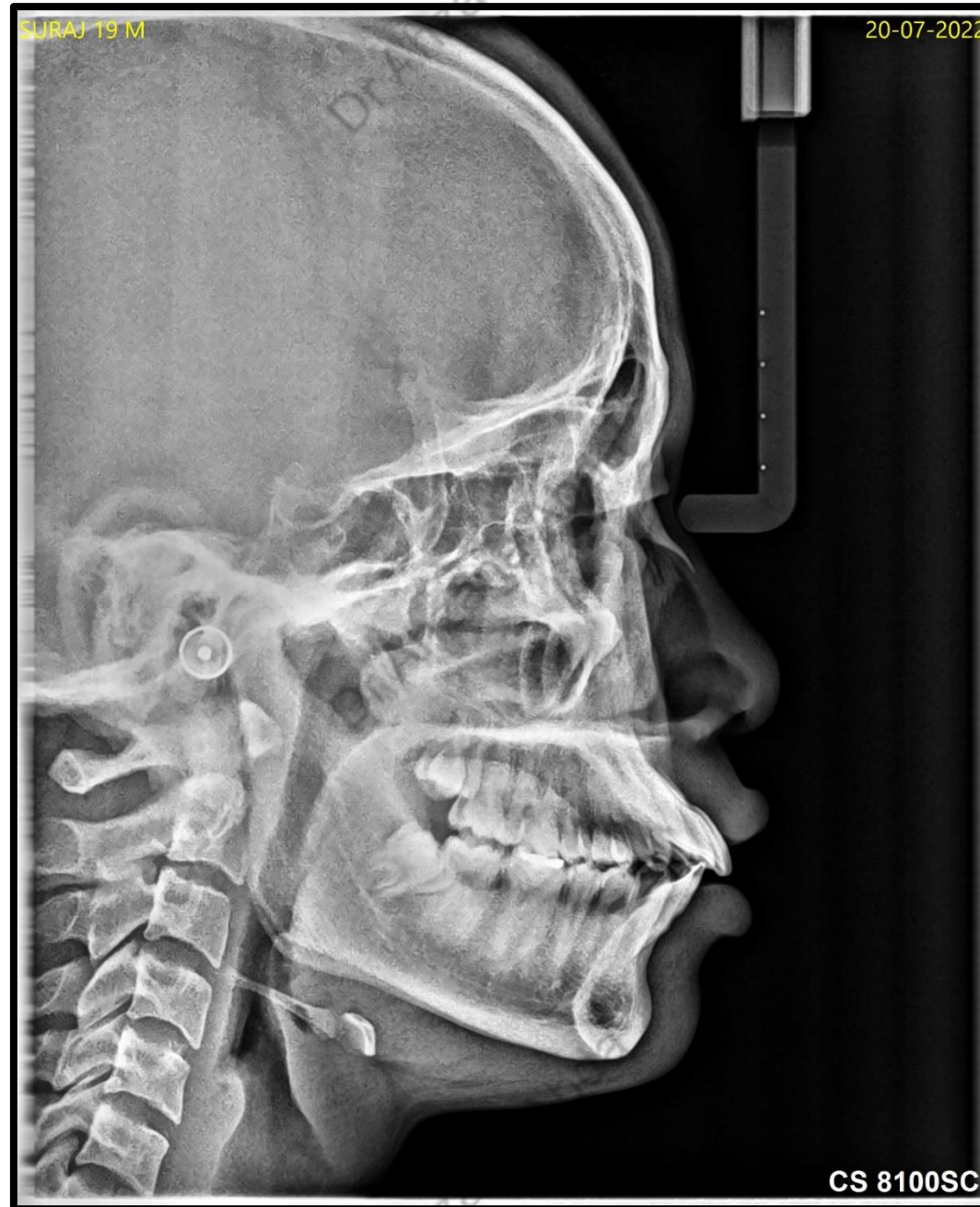
# PRE TREATMENT INTRAORAL



# PRE TREATMENT OPG



# PRE TREATMENT LATERAL CEPHALOGRAM



## **DIAGNOSIS**

- Class I Skeletal Pattern
- Angle's Class II subdivision Malocclusion with bidental proclination
- Horizontal Growth Pattern

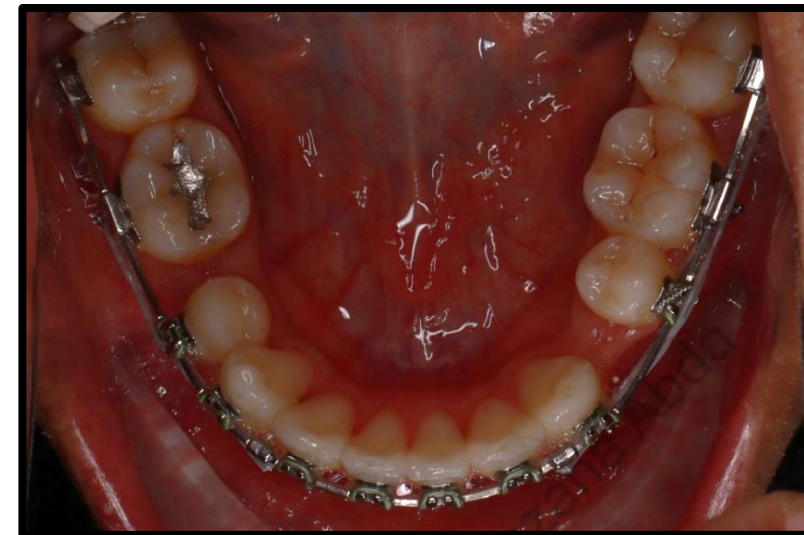
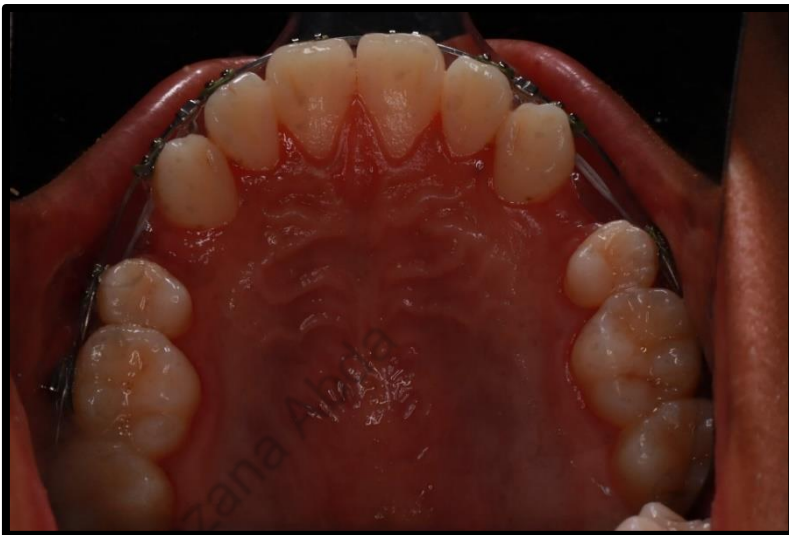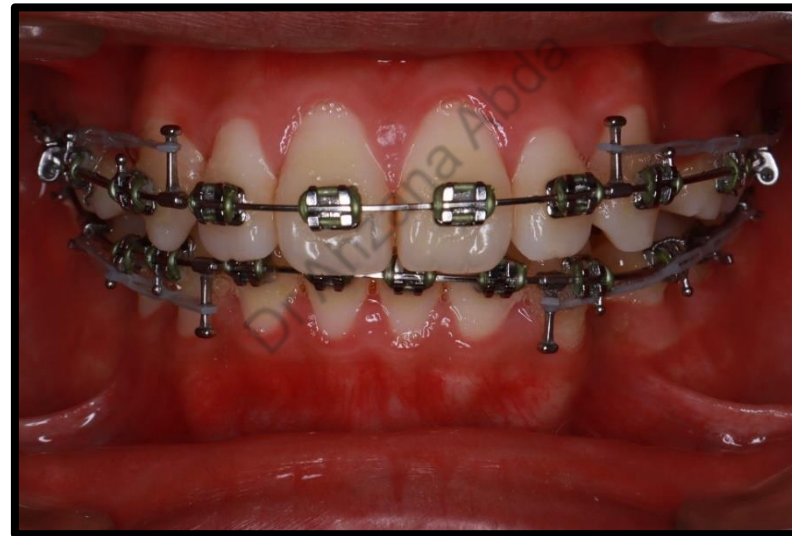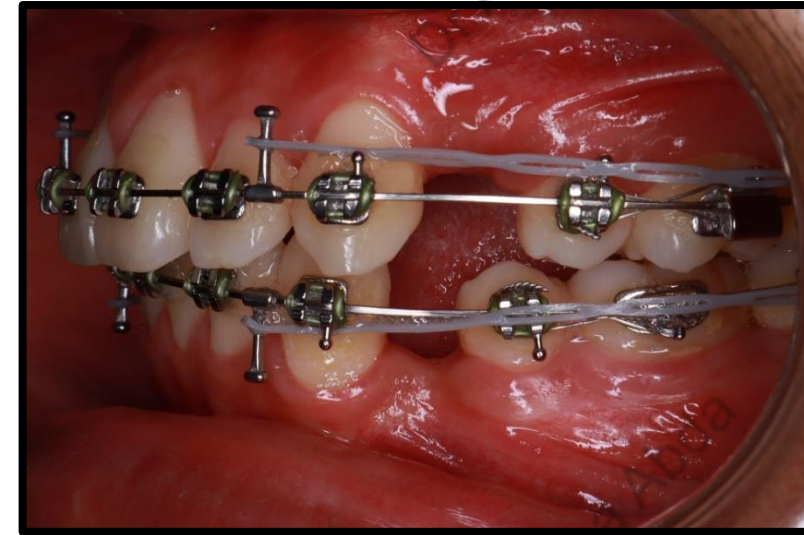
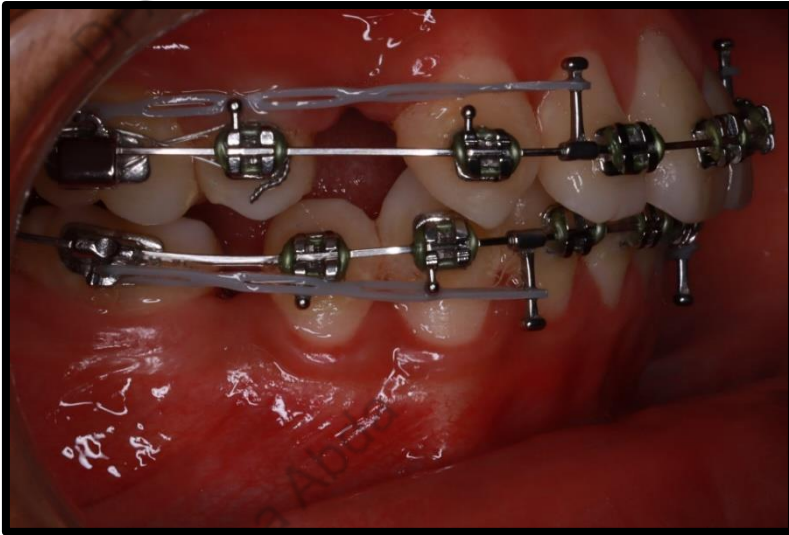
## **TREATMENT PLAN**

- 14,24,34,45 extraction

MID TREATMENT EXTRA ORAL



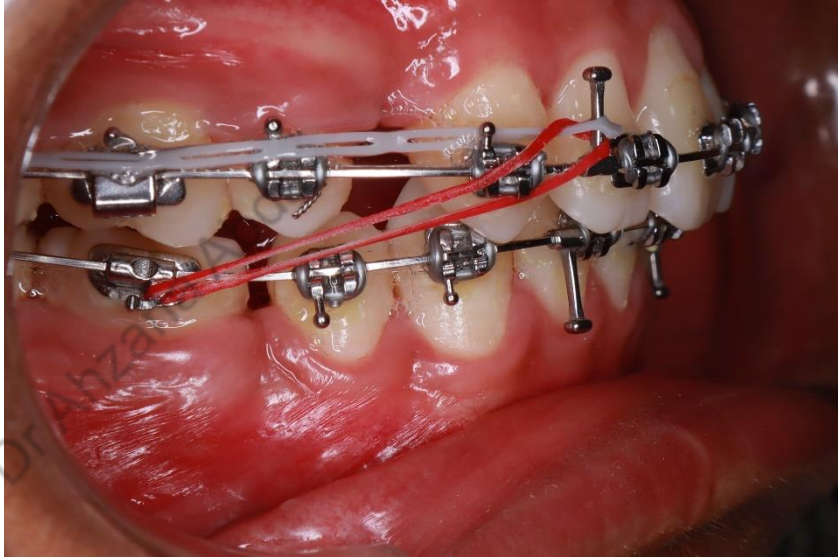
# MID TREATMENT INTRA ORAL



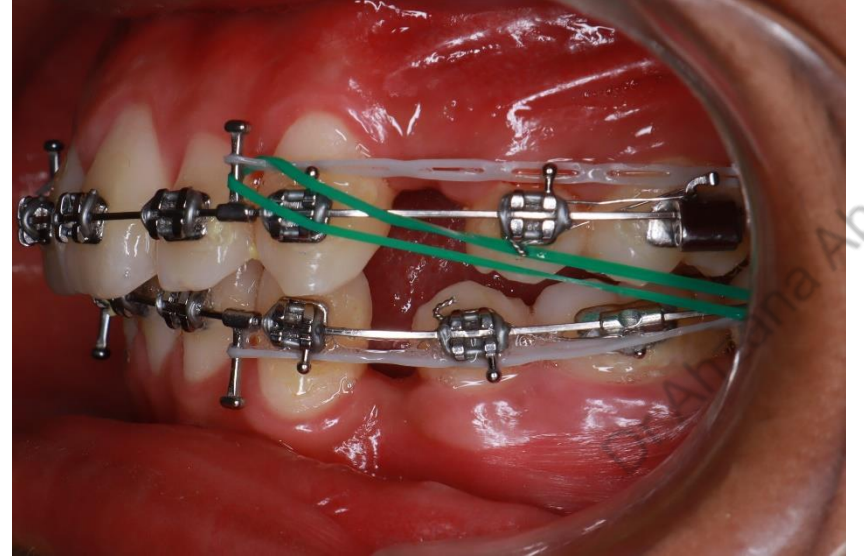
Dr Ahzana A

Dr Ahzana A

Dr Ahzana A



Dr Ahzana Abda



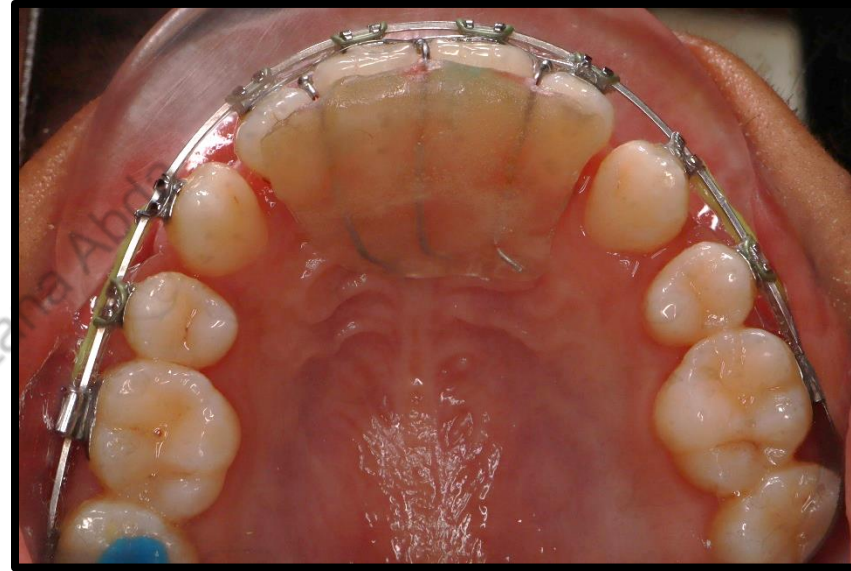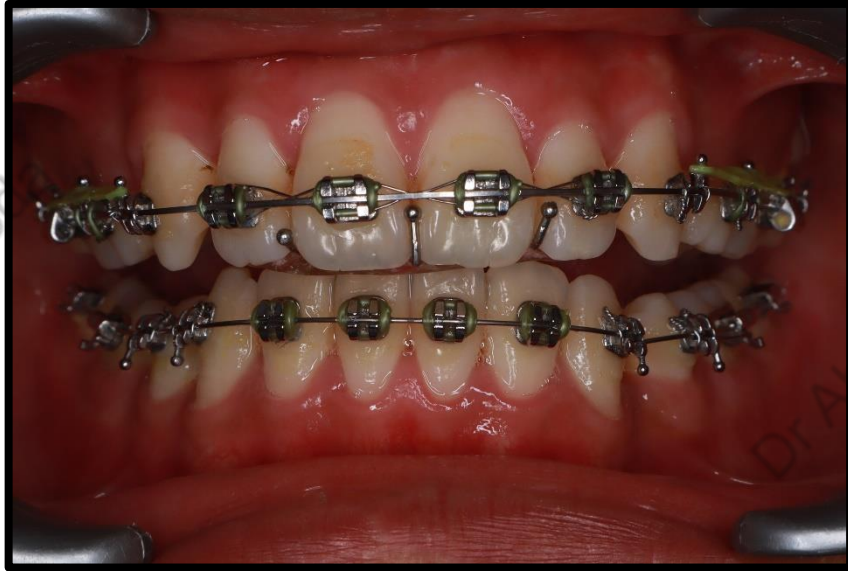Dr Ahzana Abda

Dr Ahzana Abda

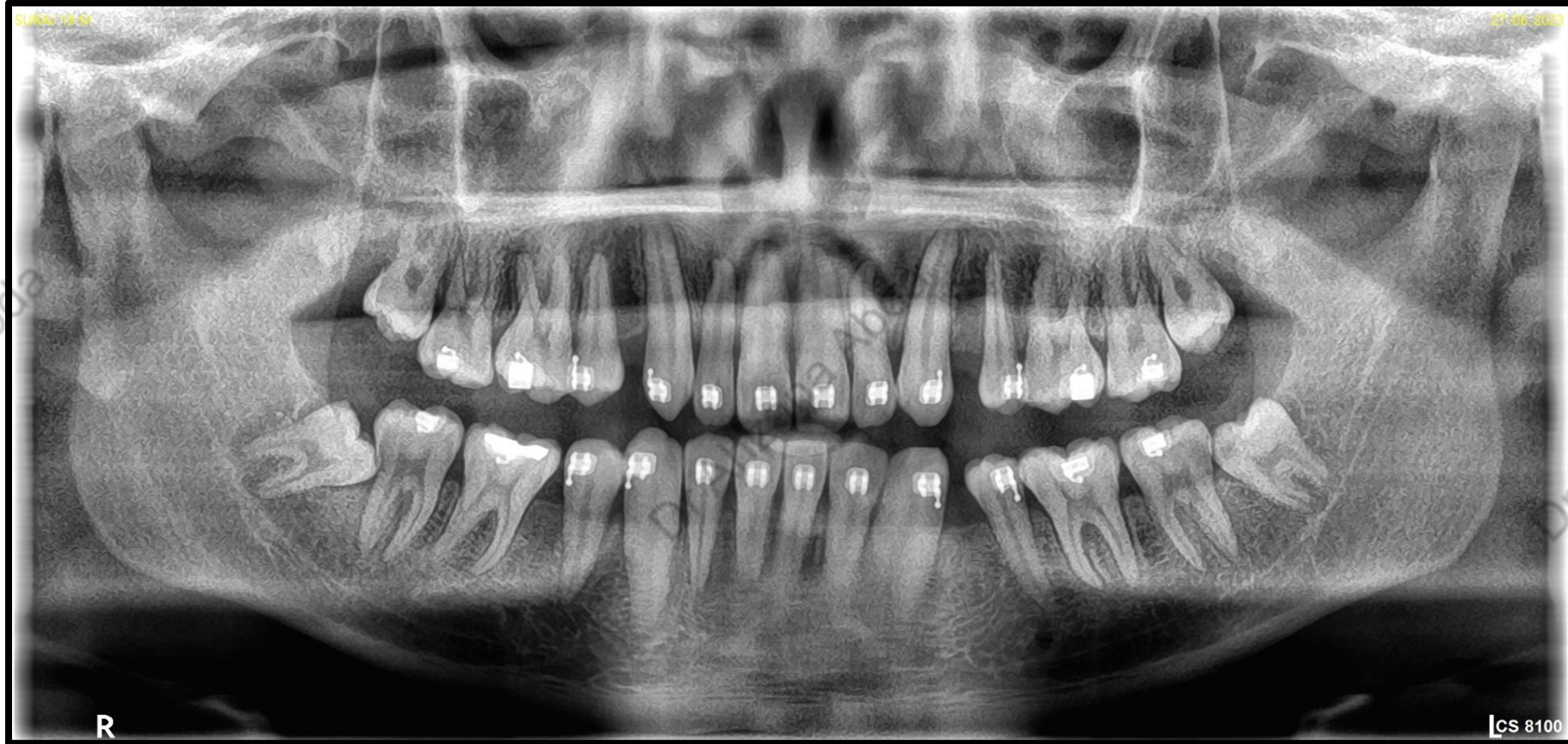Dr Ahzana Abda

Dr Ahzana Abda

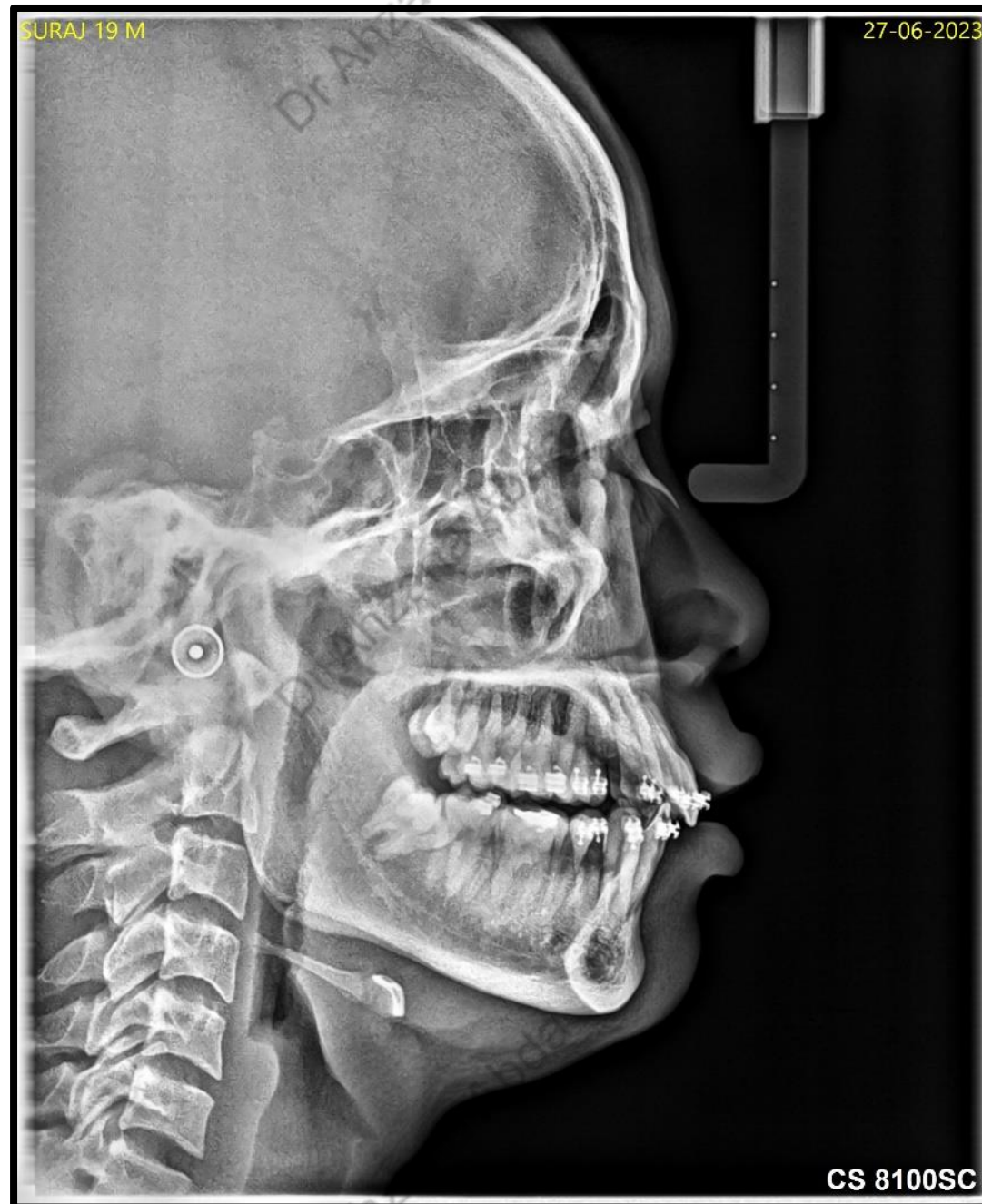
## ANTERIOR BITE PLANE



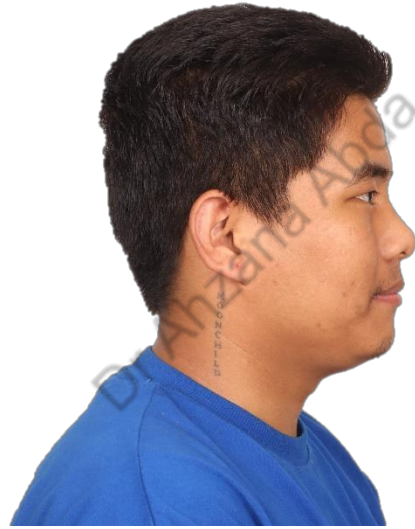# MID TREATMENT OPG



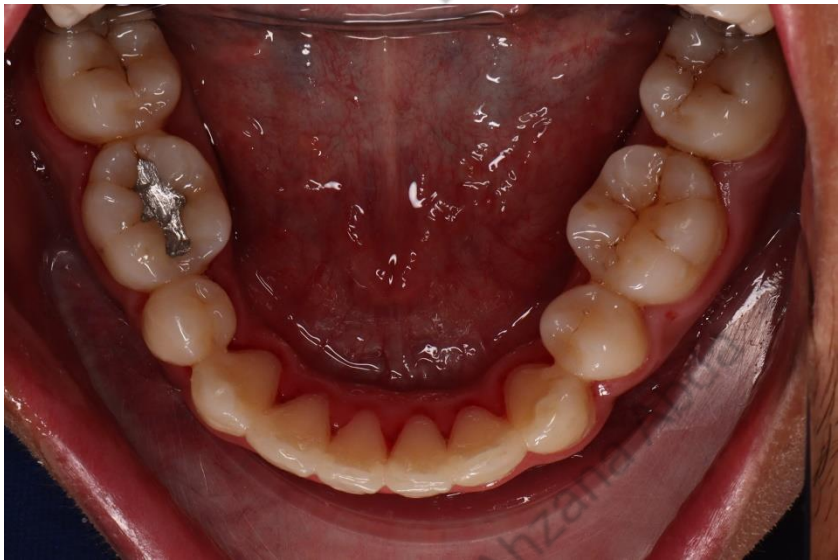
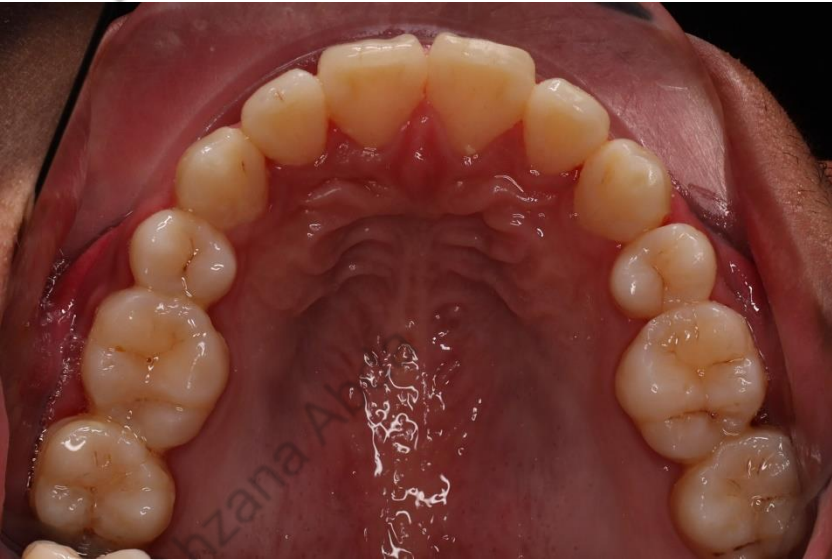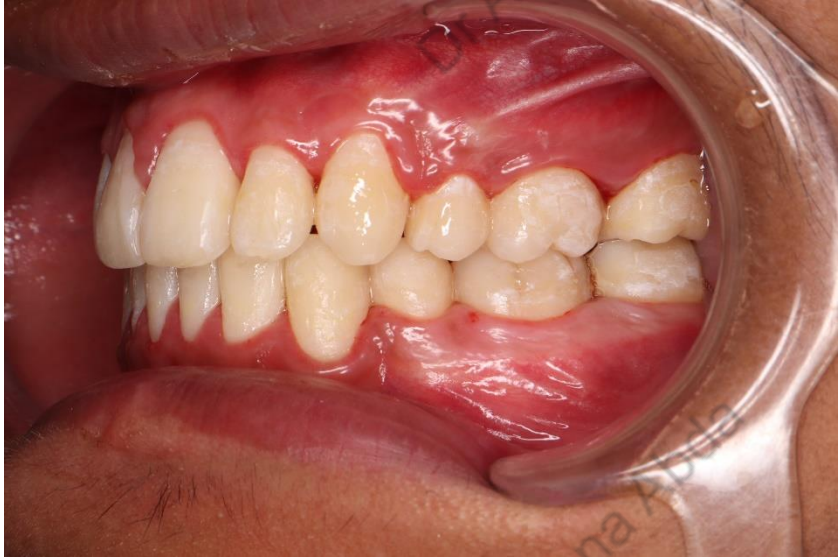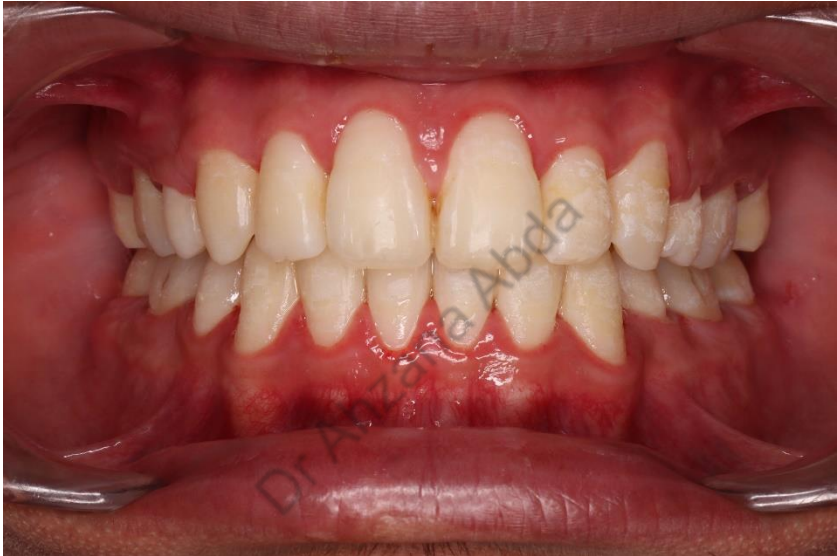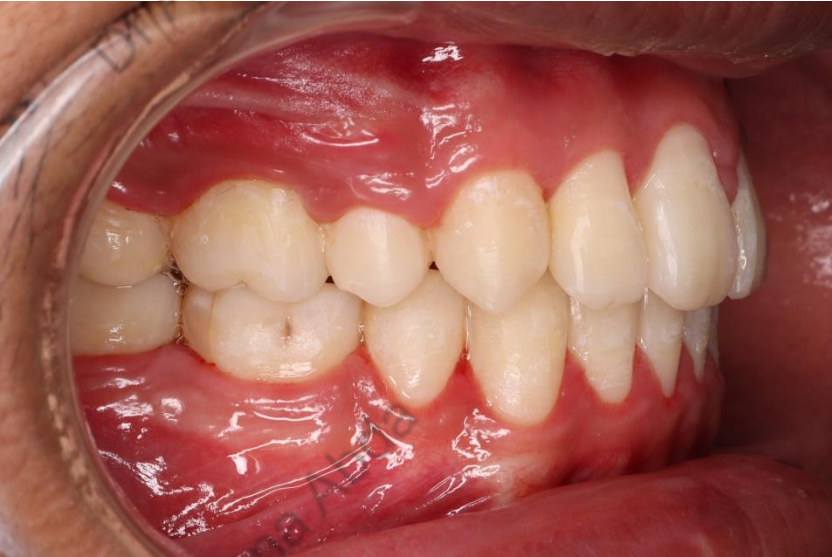# MID TREATMENT LATERAL CEPHALOGRAM



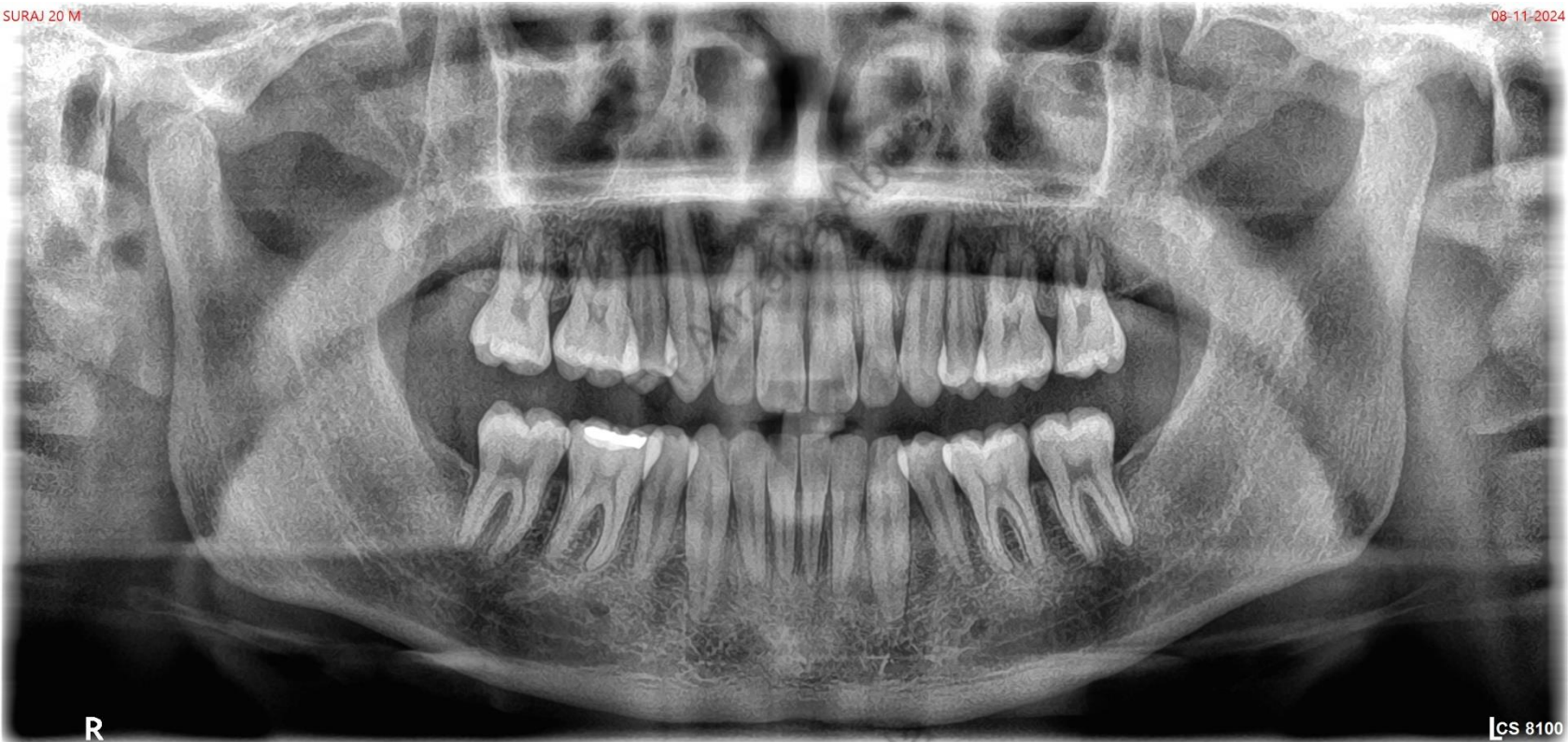**POST TREATMENT EXTRA ORAL**



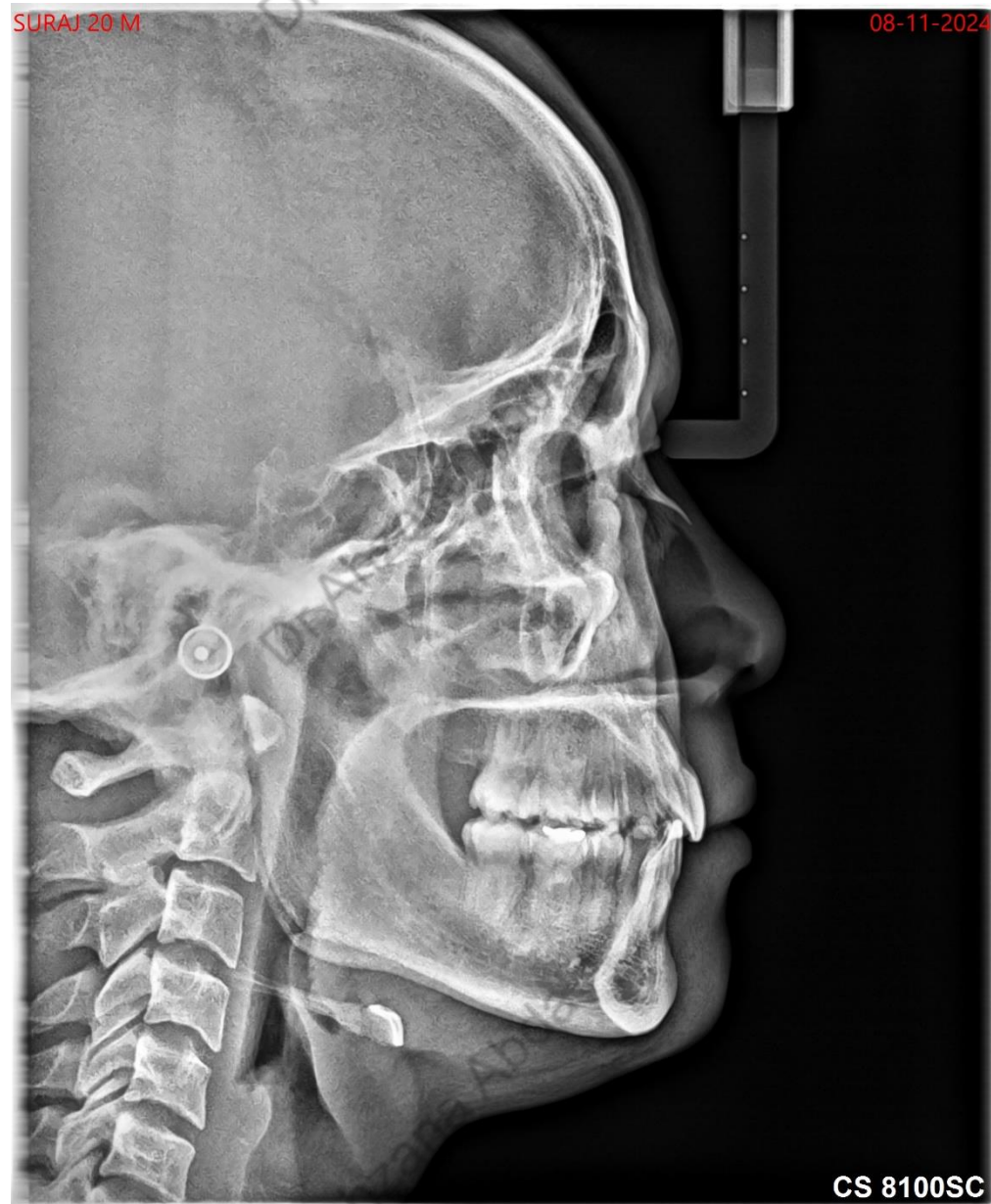**POST TREATMENT INTRAORAL**



# POST TREATMENT OPG



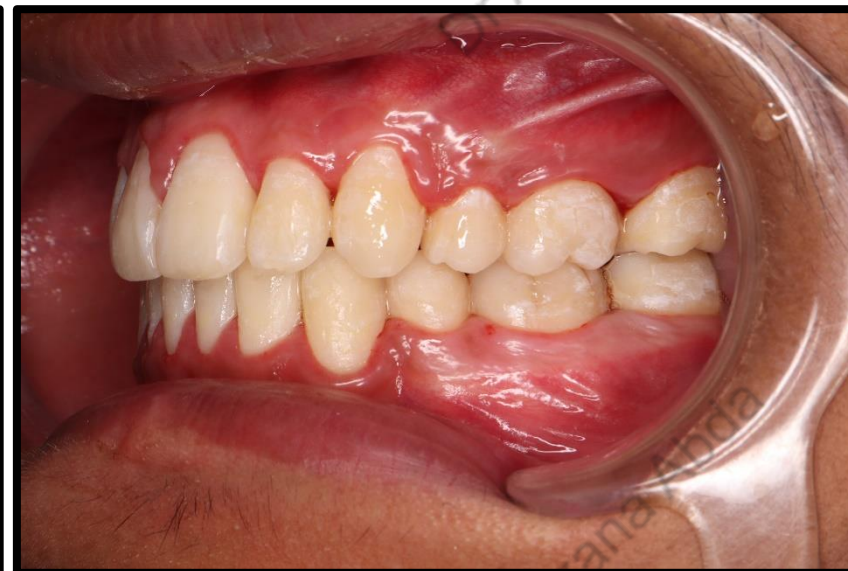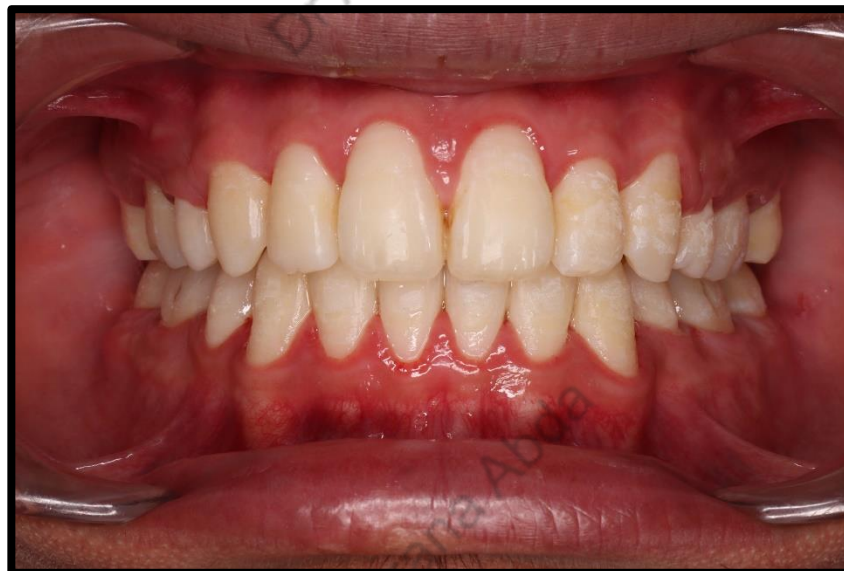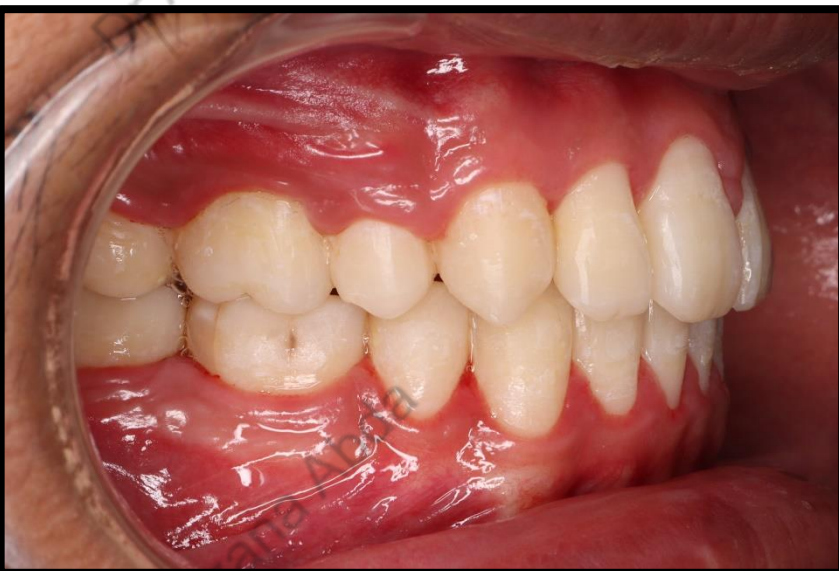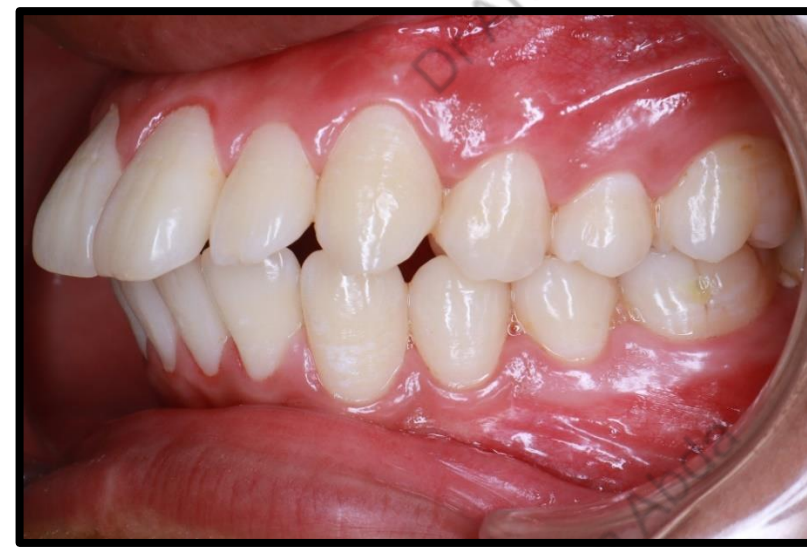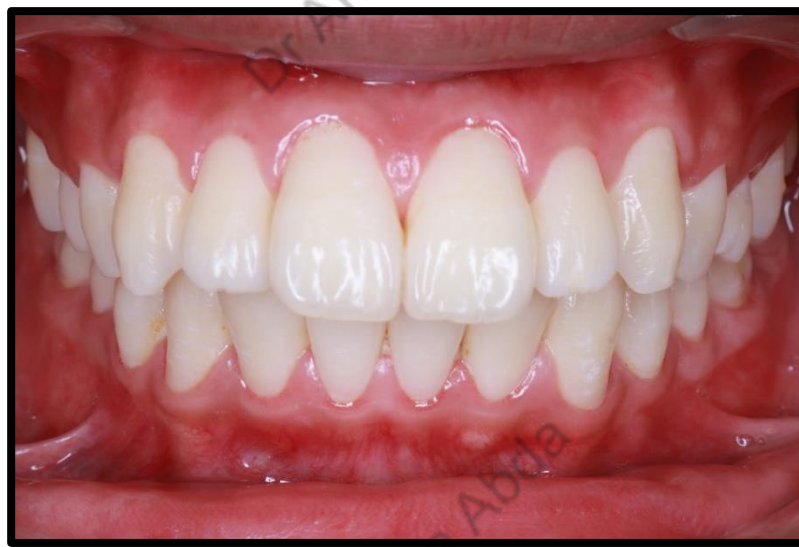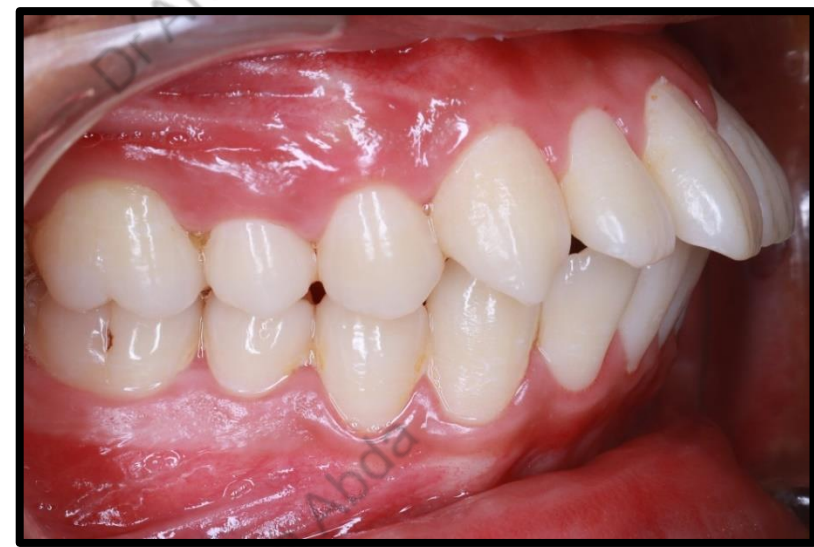# POST TREATMENT LATERAL CEPHALOGRAM



# EXTRA ORAL COMPARISON



# INTRA ORAL COMPARISON



Dr Ahzana A

Dr Ahzana A

Dr Ahzana A

Dr Ahzana Abda

Dr Ahzana Abda

Dr Ahzana Abda

Ahzana Abda

Ahzana Abda

Ahzana Abda