
BASSAM ALI ALI NASSER

Saudi Arabia

0556144131 | Bassam9538@gmail.com

OBJECTIVE

A licensed General Dentist with over 2 years of experience providing comprehensive dental care. Skilled in diagnosis, treatment planning, and performing a wide range of dental procedures using advanced technologies. Committed to patient satisfaction, continuous learning, and high-quality dental service.

EXPERIENCE

- | | |
|----------------------------|--|
| March 2025 - May - 2025 | <ul style="list-style-type: none">• General Dentist
Farhan Center and Clinics<ul style="list-style-type: none">- Manage patients efficiently.- Provide high-quality endodontic, prosthodontic, cosmetic, and oral surgery treatments.- Perform extractions and restorative procedures. |
| April,2023 - August,2024 | <ul style="list-style-type: none">• Dentist
XP Dental Center<ul style="list-style-type: none">-Manage patient care and dental procedures.- Deliver quality endodontic, prosthodontic, and cosmetic treatments.- Perform photography and utilize advanced digital dental tools (3D X-ray, Digital Smile Design, rotary systems, microscope, and oral scanner). |
| March,2023 - December,2023 | <ul style="list-style-type: none">• Dentist
Republican Teaching Hospital Authority<ul style="list-style-type: none">-Manage patients and provide endodontic, cosmetic, and surgical treatments.- Work effectively under pressure within a multidisciplinary team. |
| August 2022 - January,2023 | <ul style="list-style-type: none">• Volunteer in Dental Mission
Tarlac Provincial Hospital
Educate the patient care, providing a dental examination and extraction |
| 2020 - 2022 | <ul style="list-style-type: none">• Virgen Milagrosa University Foundation
Clinical Requirements Internship
Clinical requirement during my internship |
| 2019 - 2022 | <ul style="list-style-type: none">• Red Cross (Philippines) Volunteer
Red Cross
Participate in the activities as of blood donation and educate people how to be save awhile there are earthquakes, fire and injuries |

EDUCATION

- | | |
|------|--|
| 2022 | <ul style="list-style-type: none">• Virgen Milagrosa University Foundation (VMUF)
Bachelor of Dental Medicine |
| 2013 | <ul style="list-style-type: none">• King Abdullah Complex
High school |

LANGUAGES

- Arabic - native
- English - intermediate
- Tagalog(Philippines)- Deal with the patient

SKILLS

- - Patient management and dental diagnosis
- - Endodontic and prosthodontic treatments
- - Oral surgery and extractions
- - Cosmetic and restorative dentistry
- - Dental photography and digital smile design
- - Infection control and sterilization protocols

COURSES

- Certificate of attending intensive theoretical and preclinical training course in Rotary Endodontic system, Crown and bridge preparation techniques, Composite Restoration Techniques, Dental photography and Digital smile Design. Held in XP Dental Center (80Hours)
- Certificate of crown and bridge held in Addison Institute for Medical and Administrative Training (22hrs)
- Certificate of attending a Dental Missions

Issued: 25/02/2025
Expired: 26/02/2027



Profile Number: 24720124
Membership Status: Practicing

Bassam Ali Ali Nasser

General Dentist-General Dentistry

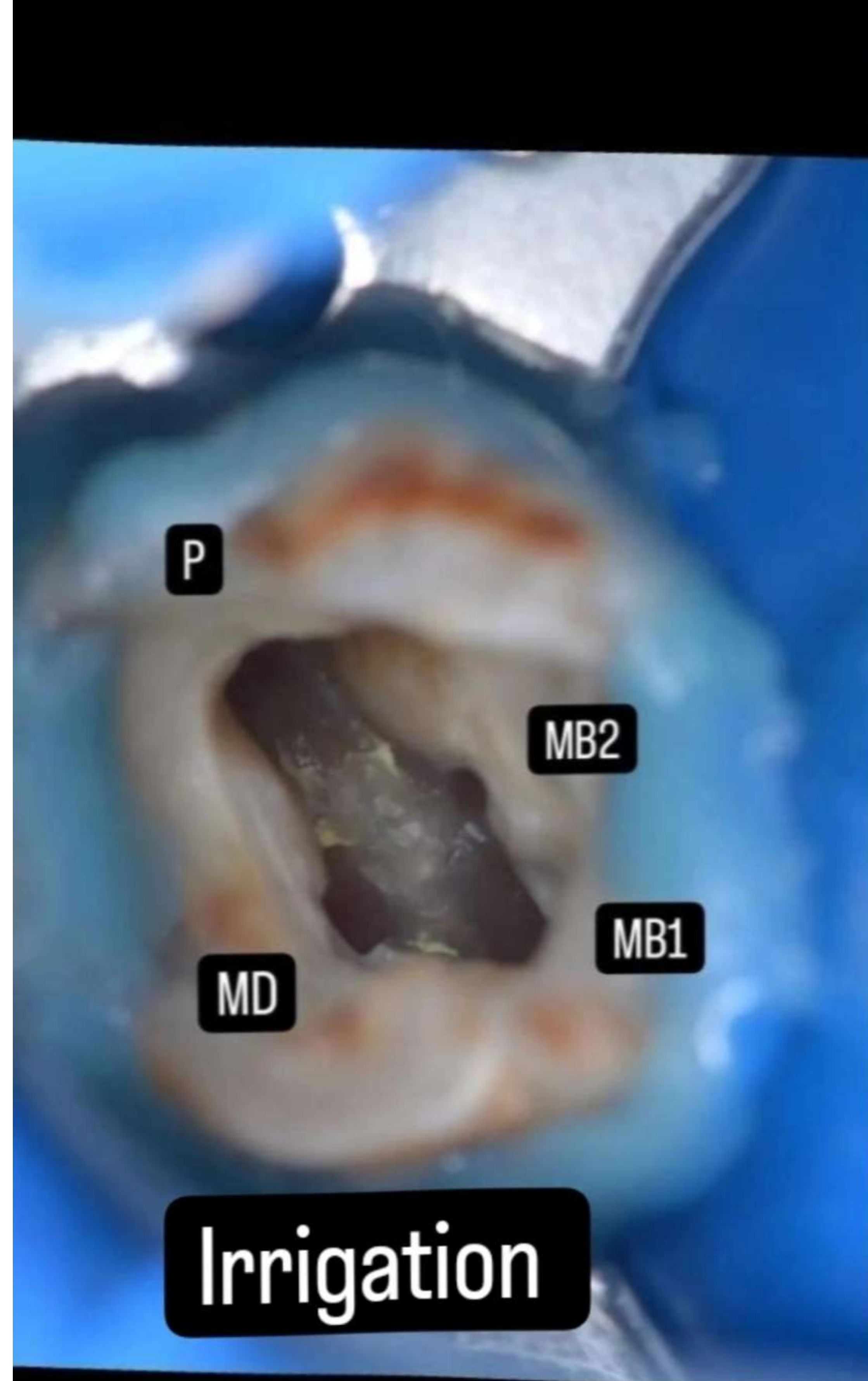
Dentistry and Related Specialties

Nationality Yemen
National/Iqama ID
Date of Birth 01/01/1993

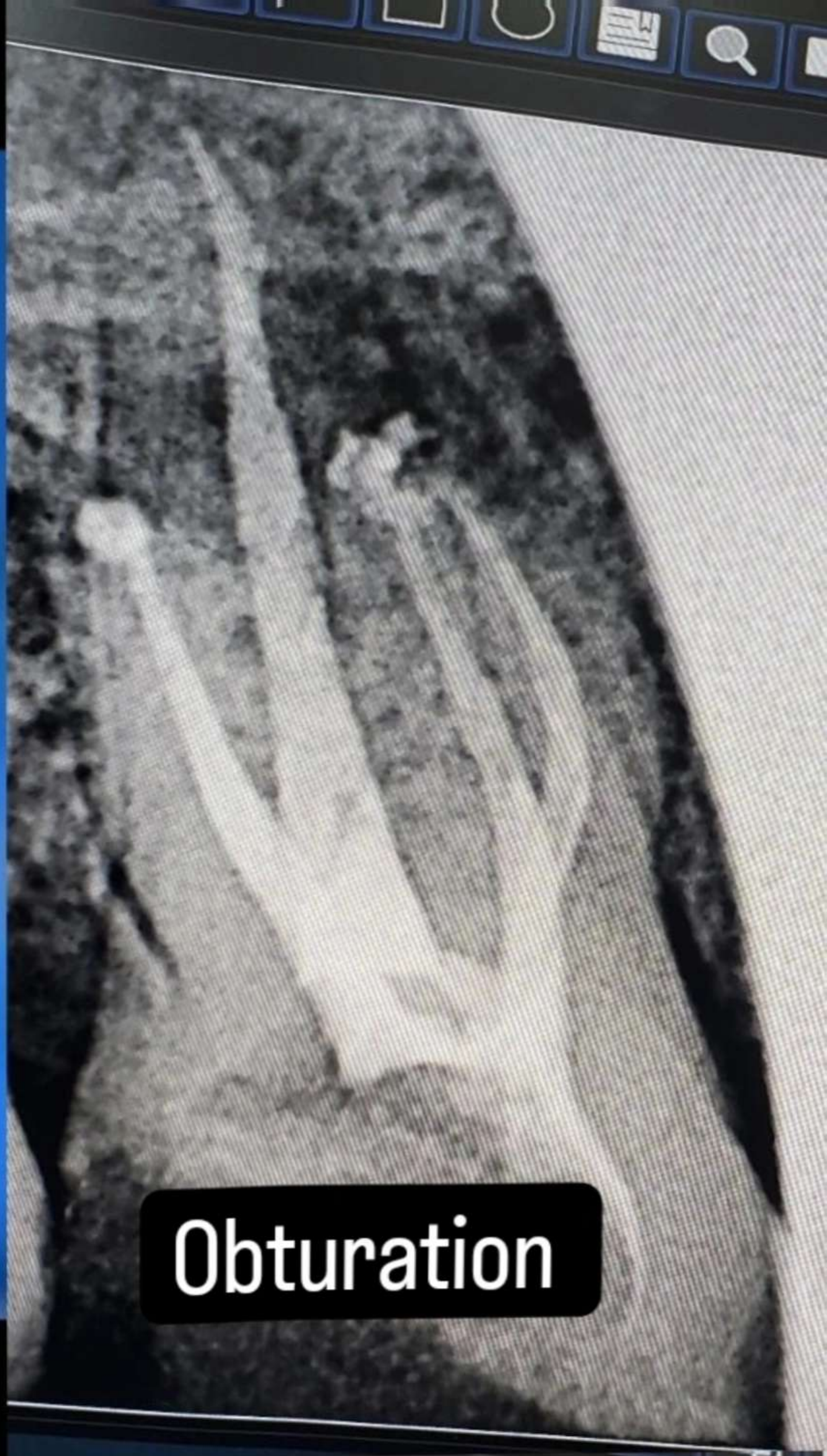Registration Record

Decision Date	Decision type	Qualification	Country	Awarding Date	Rank	Speciality	Sub Speciality
26/02/2025	Professional Classification	doctor of dental medicen	Philippines	05/08/2022	General Dentist	General Dentistry	

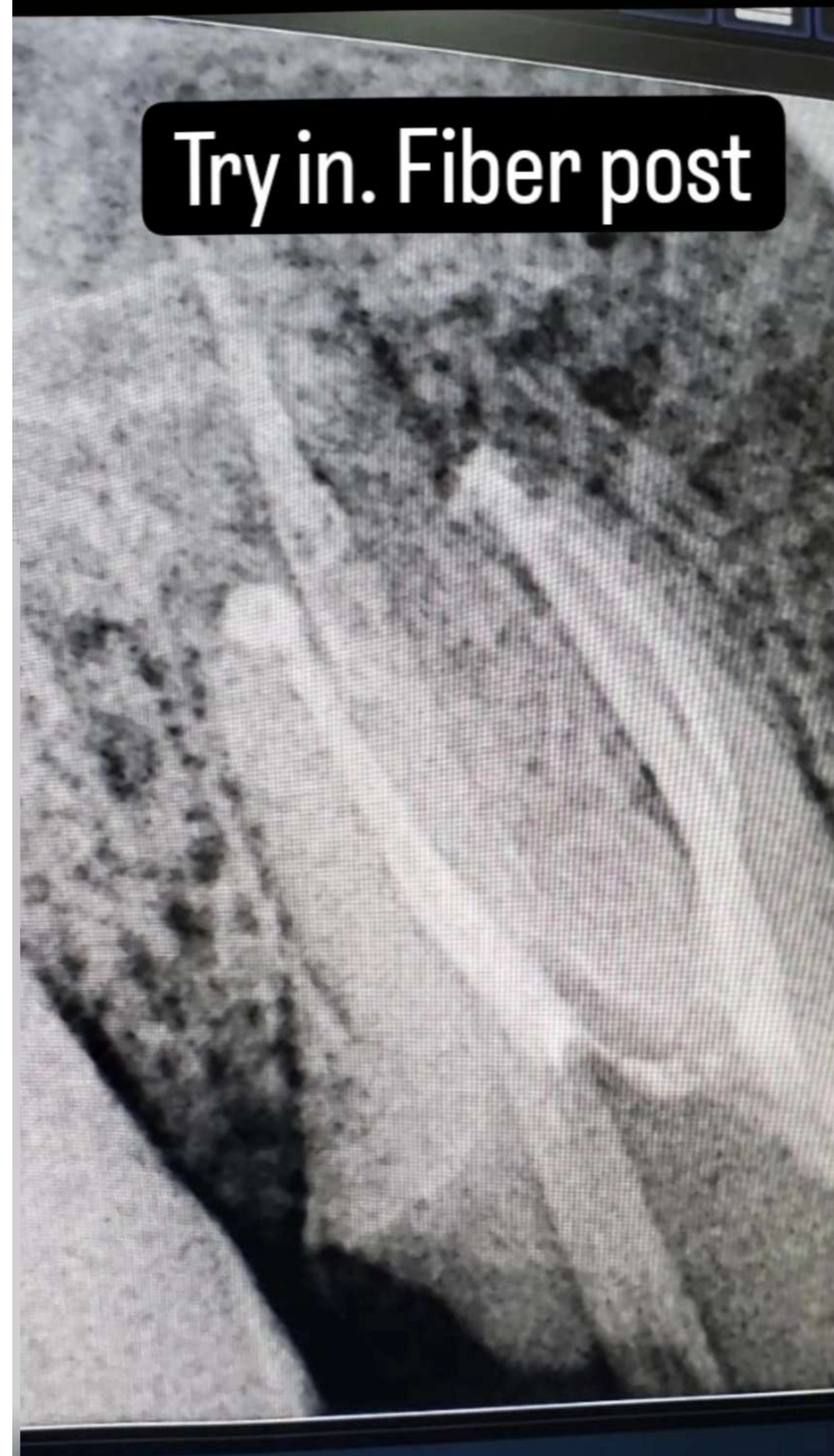This certificate is printed electronically ,for verification visit <https://www.scfhs.org.sa>



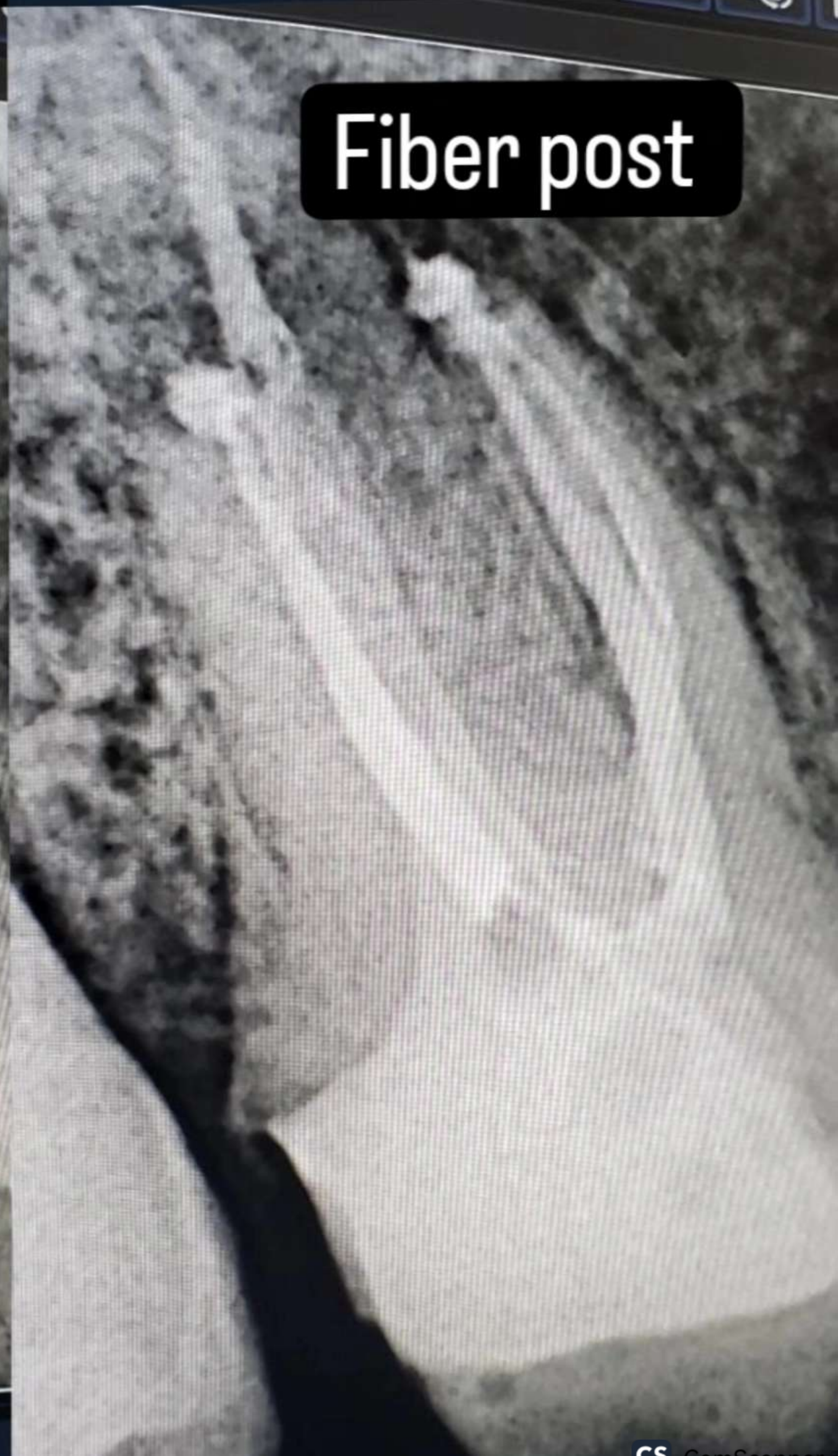Irrigation



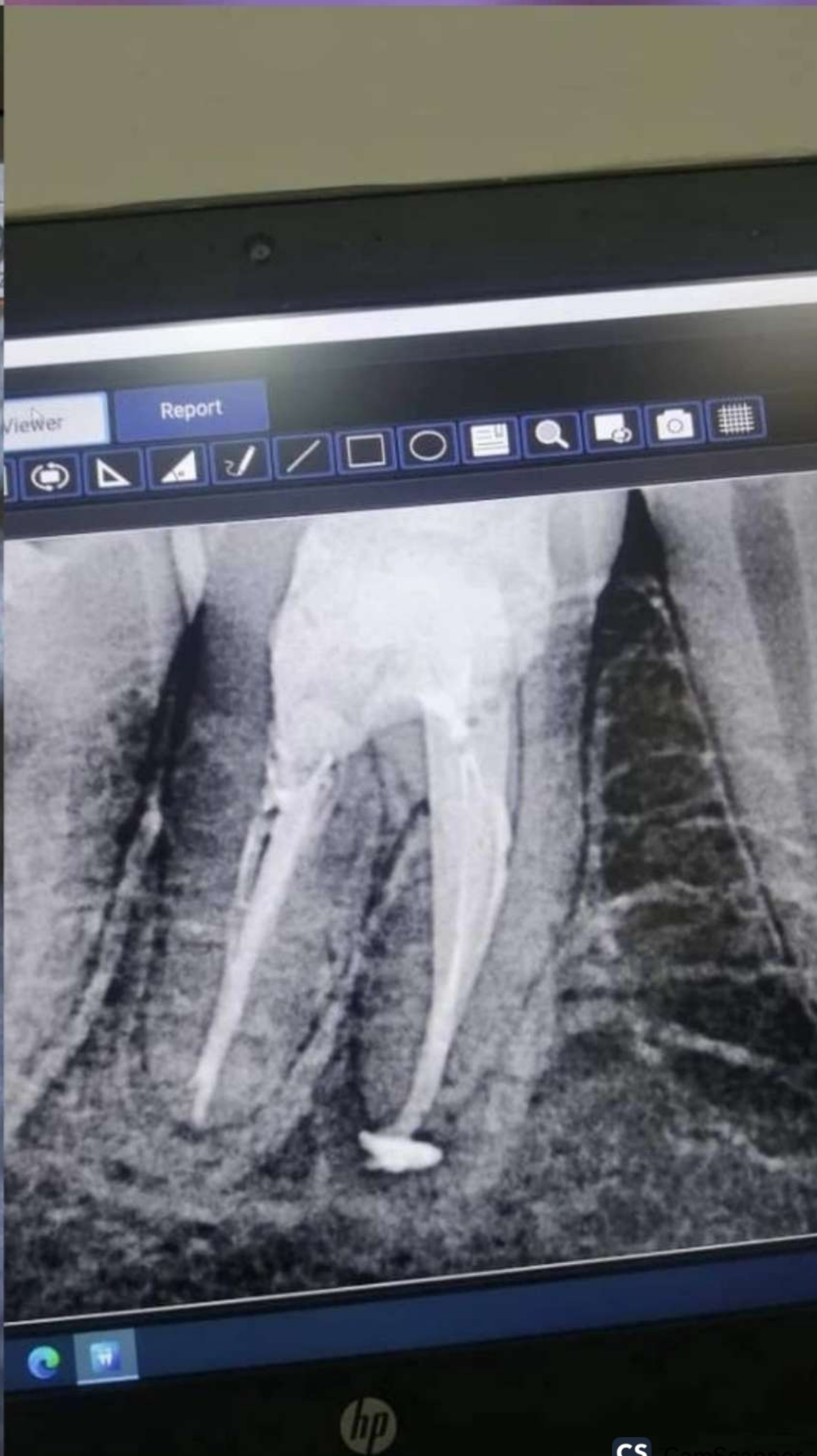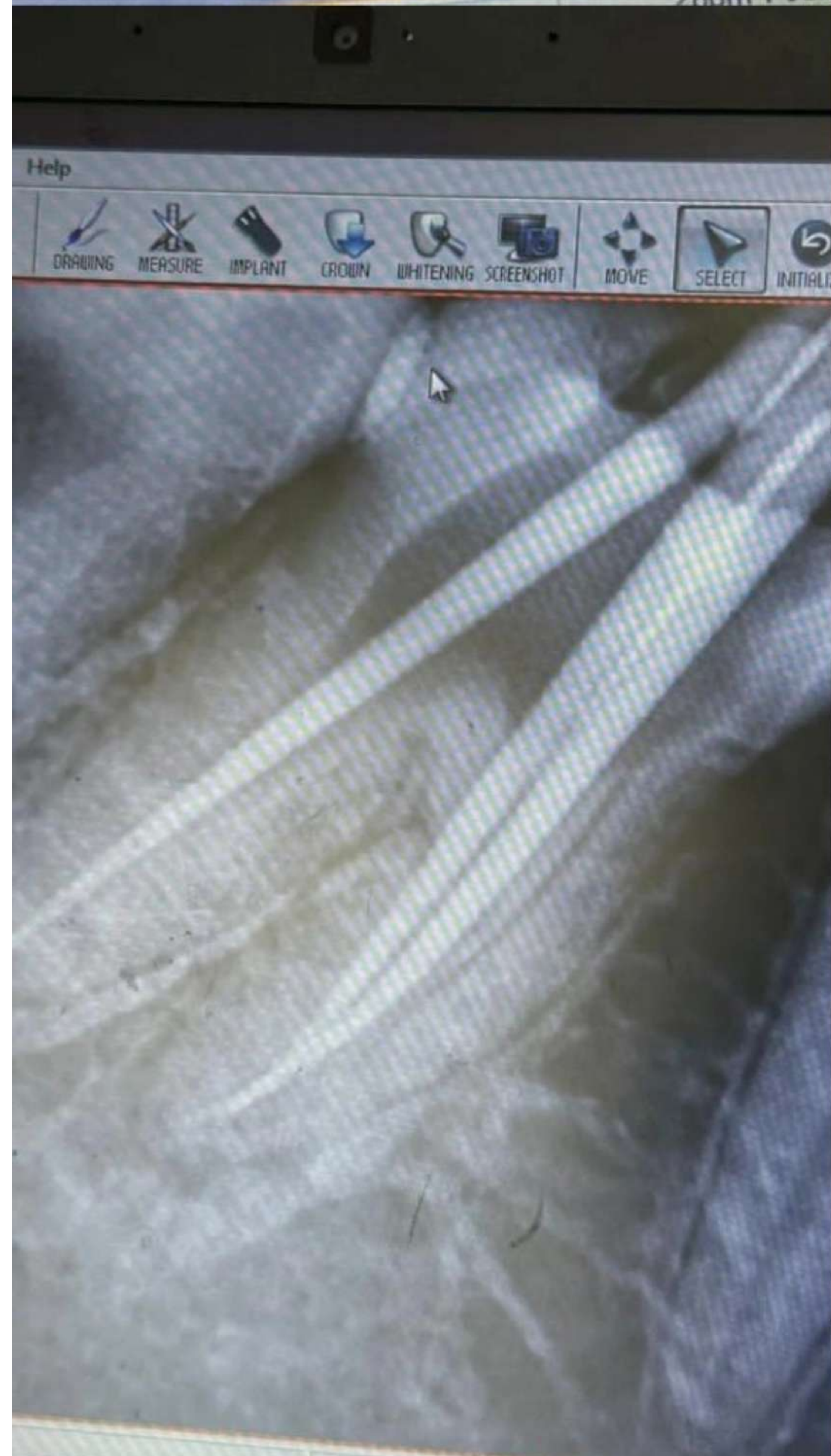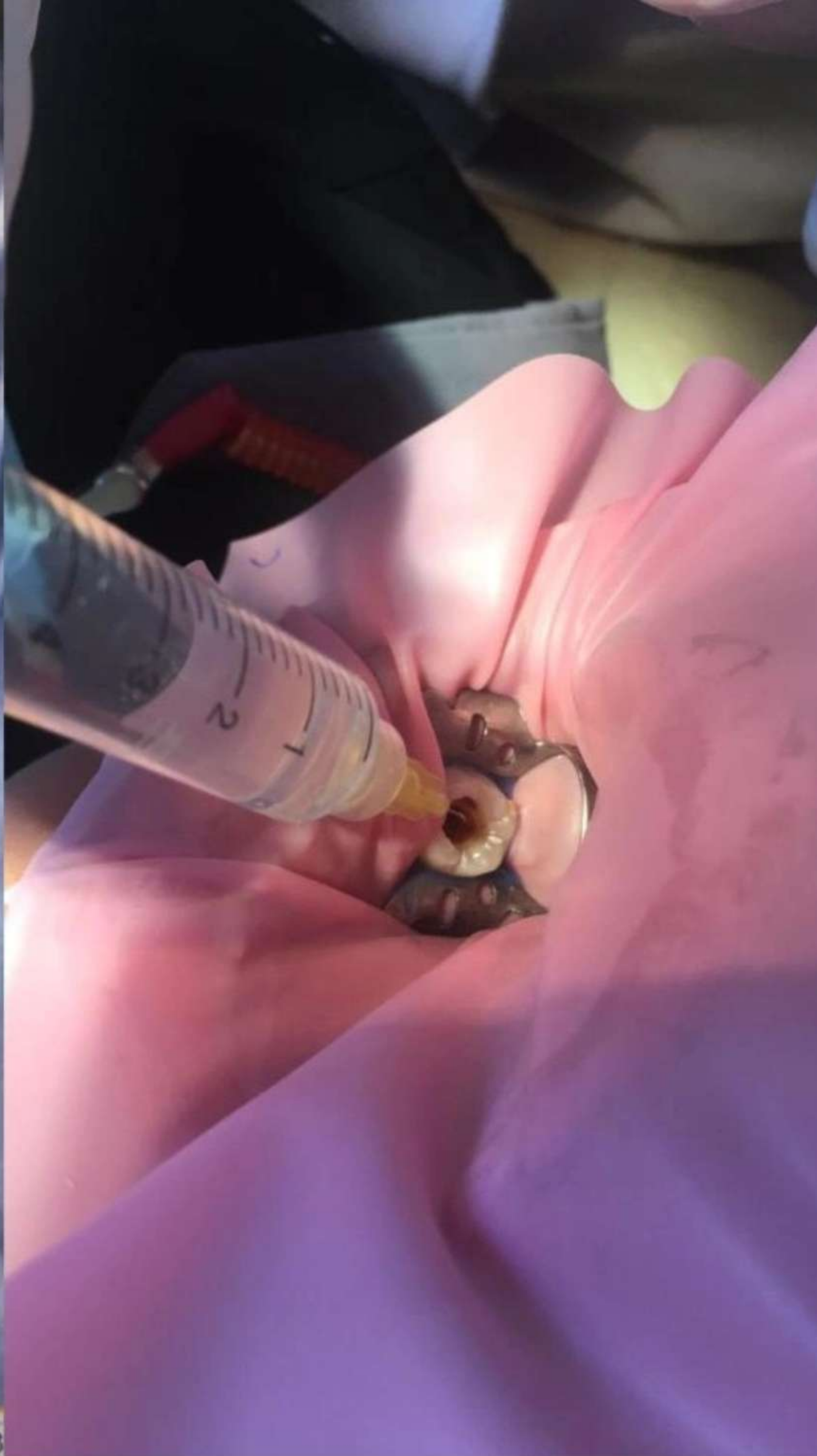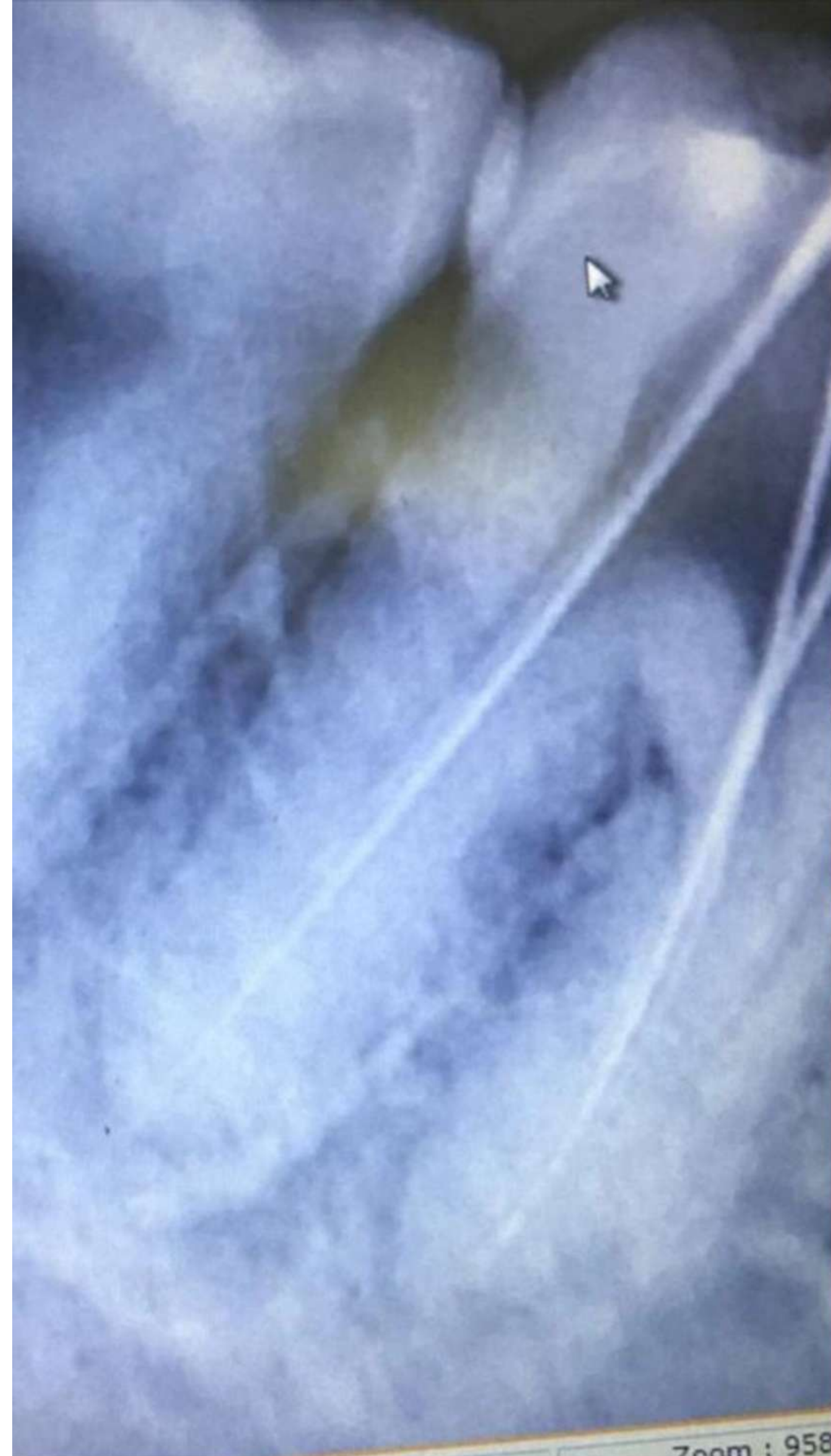Obturation

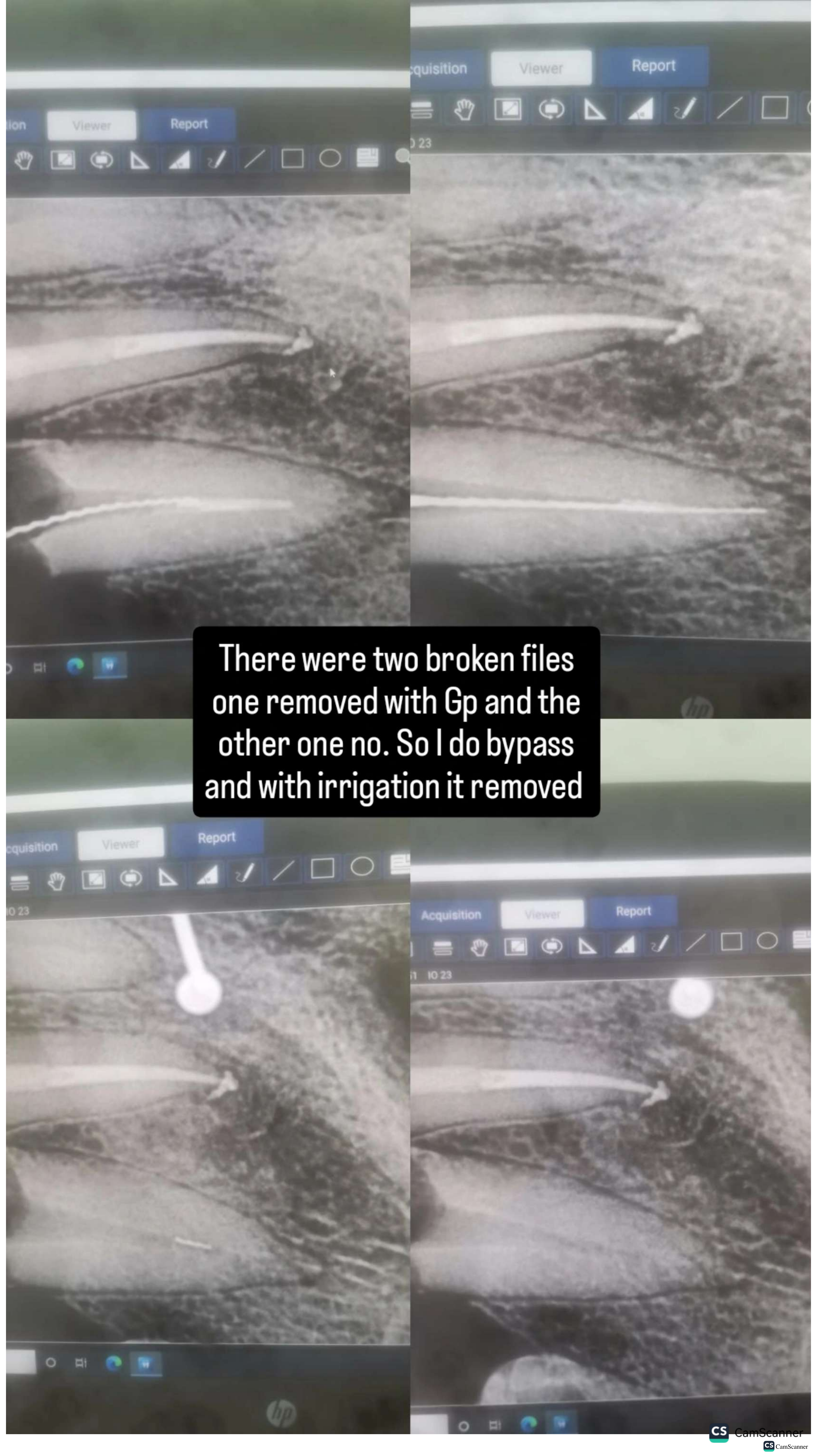


Try in. Fiber post

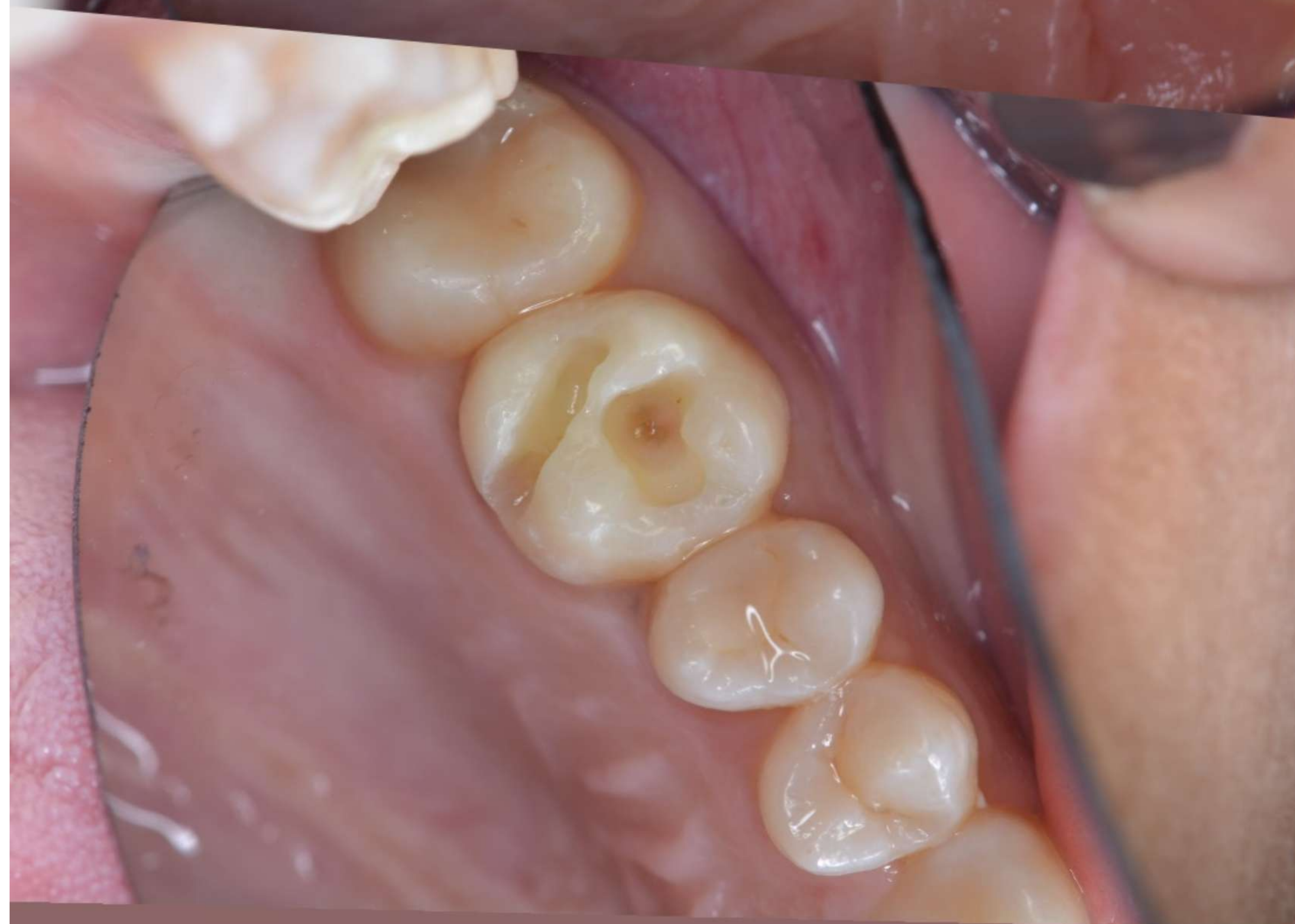
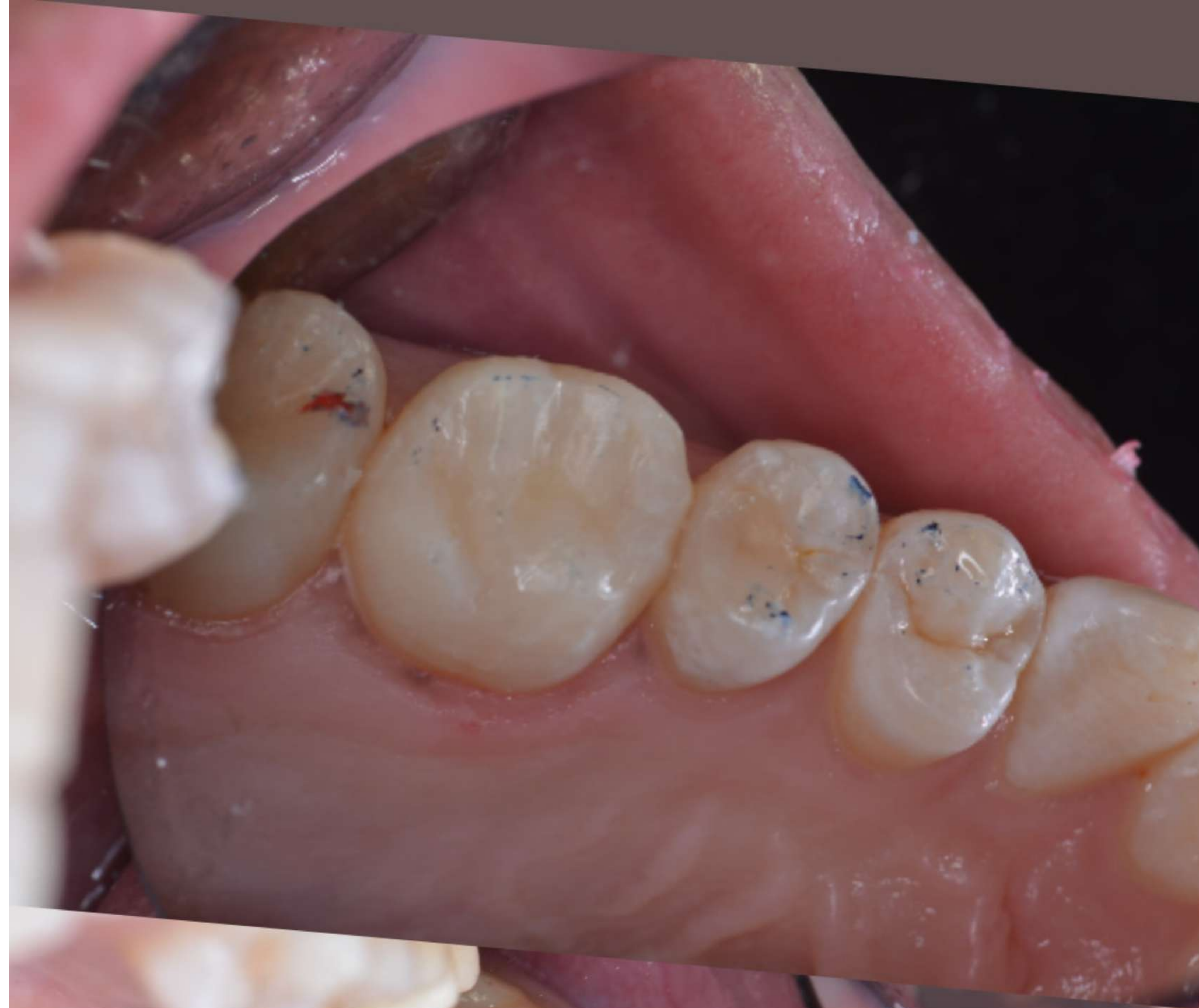

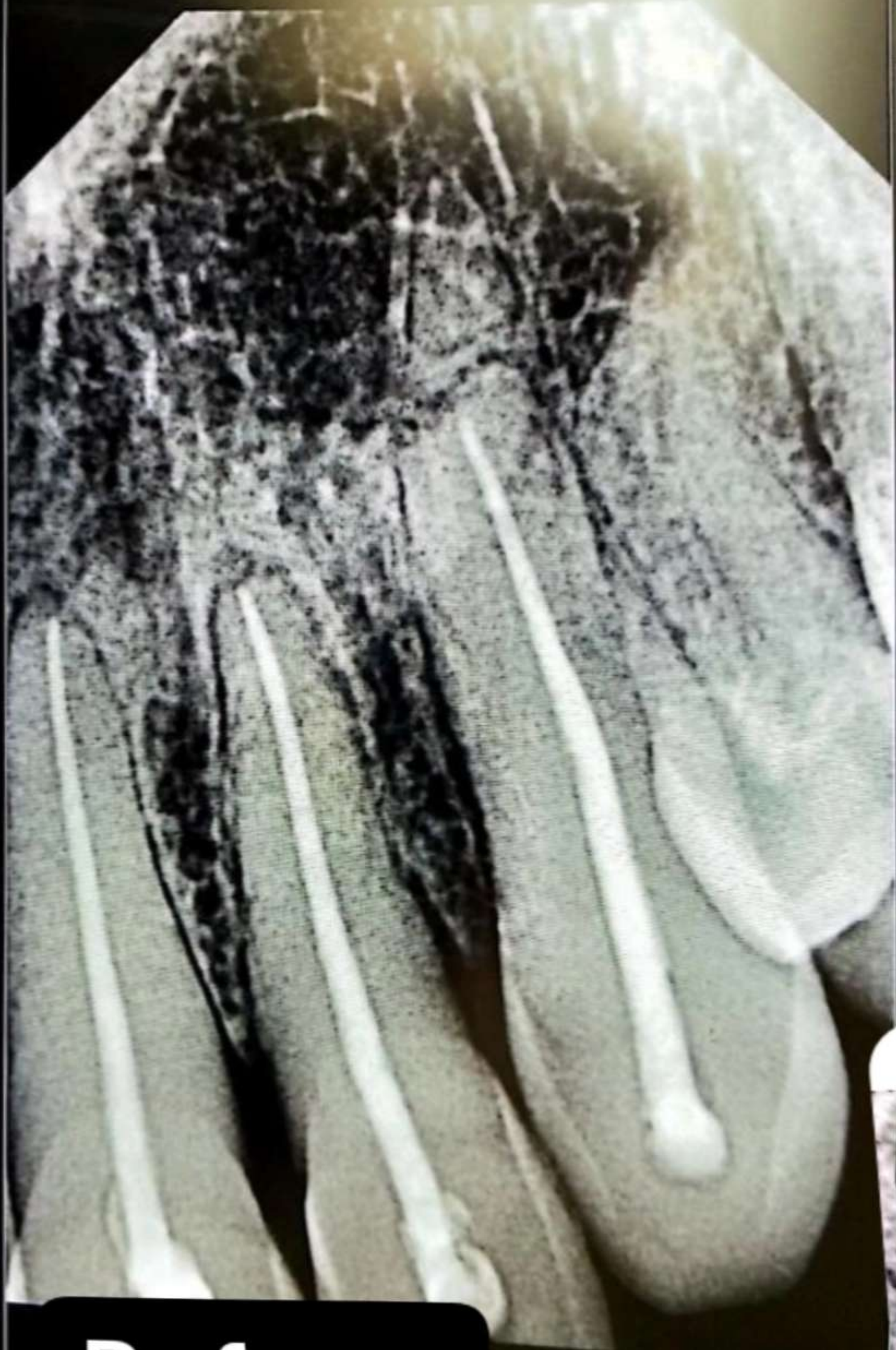Fiber post





There were two broken files
one removed with Gp and the
other one no. So I do bypass
and with irrigation it removed

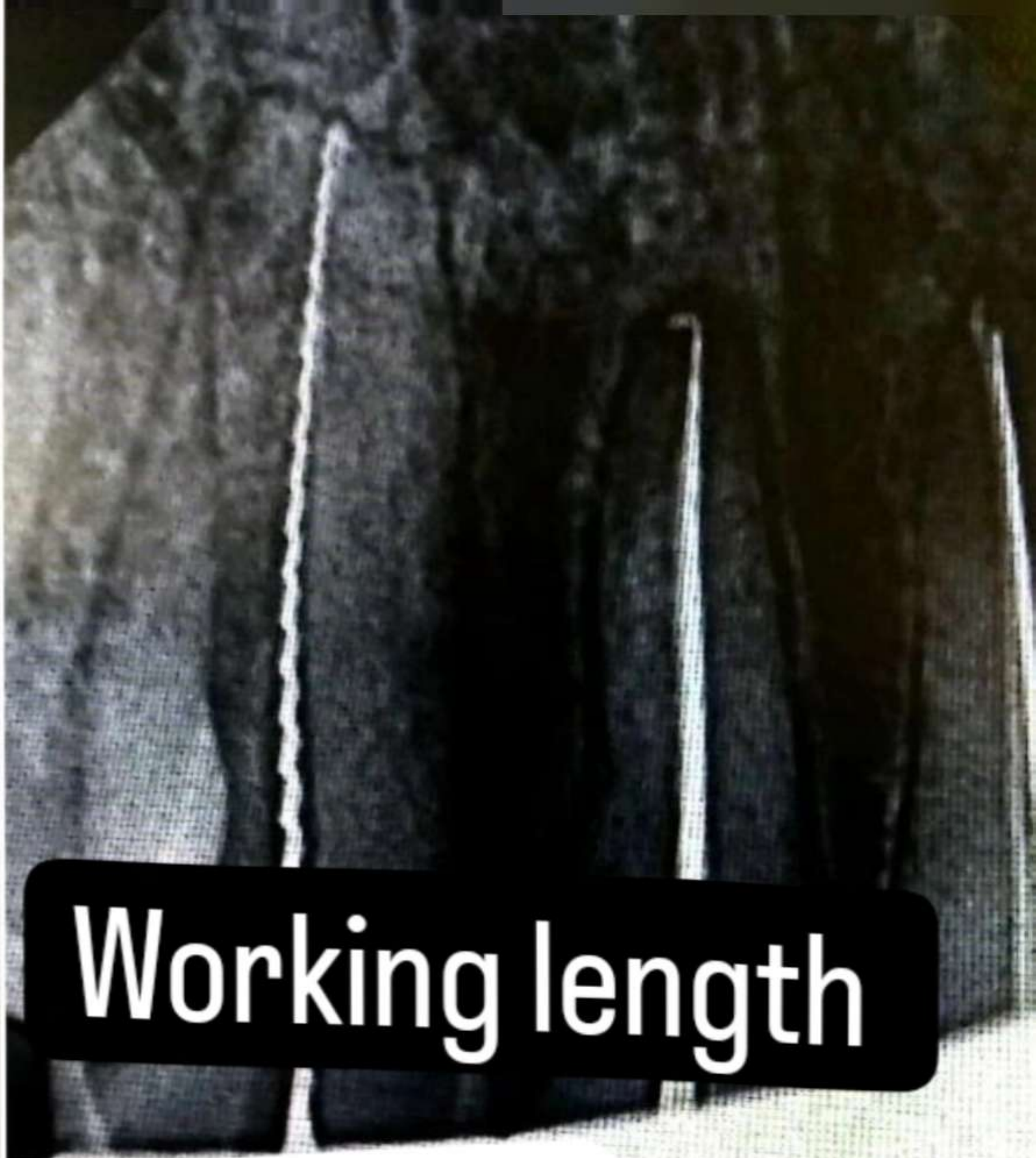




Before

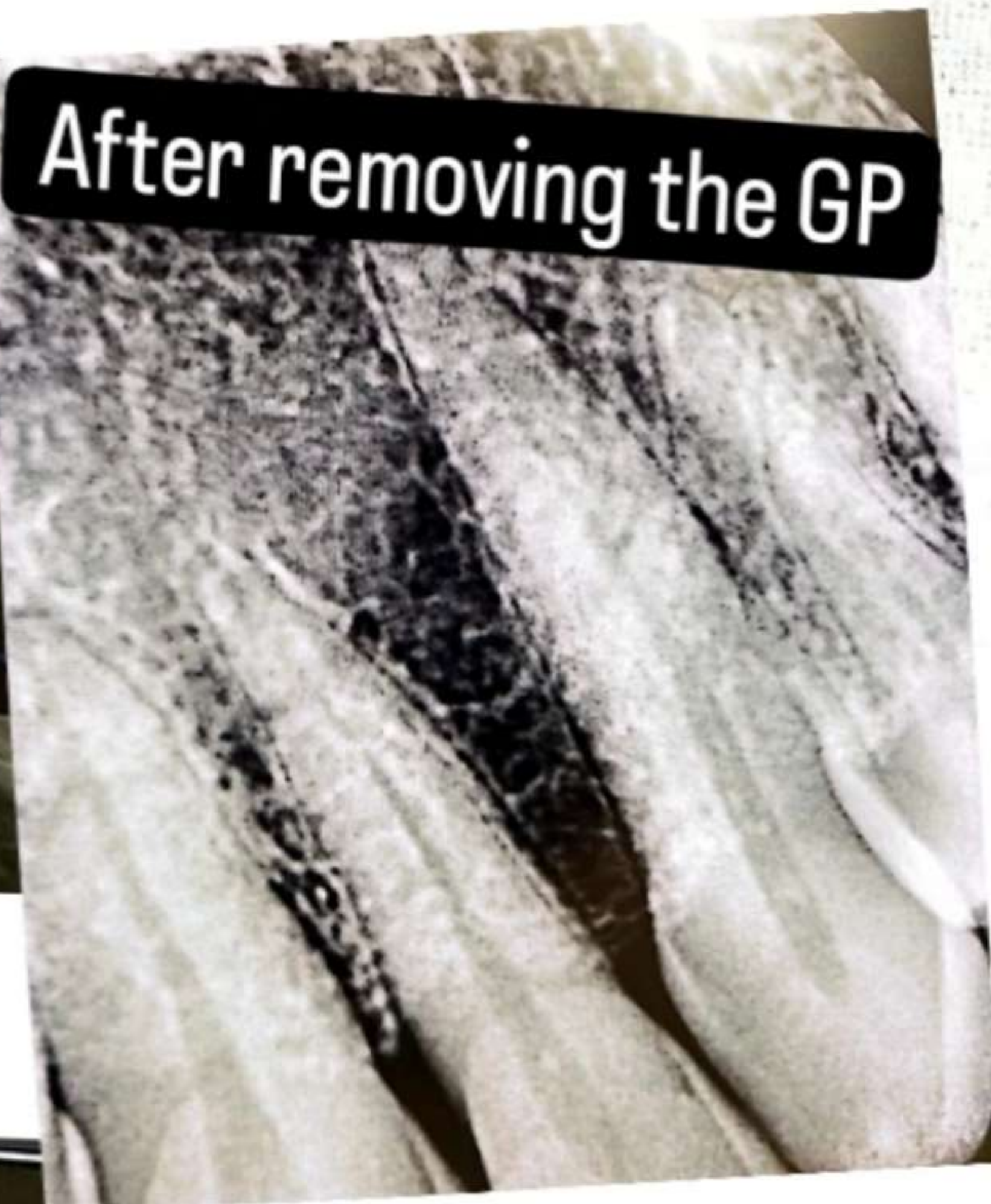حاله جاتني تبغى internal
bleaching للأسنان معموله
لها سحب عصب. تم اعاده
السحب العصب لعدم وجود

coronal seal

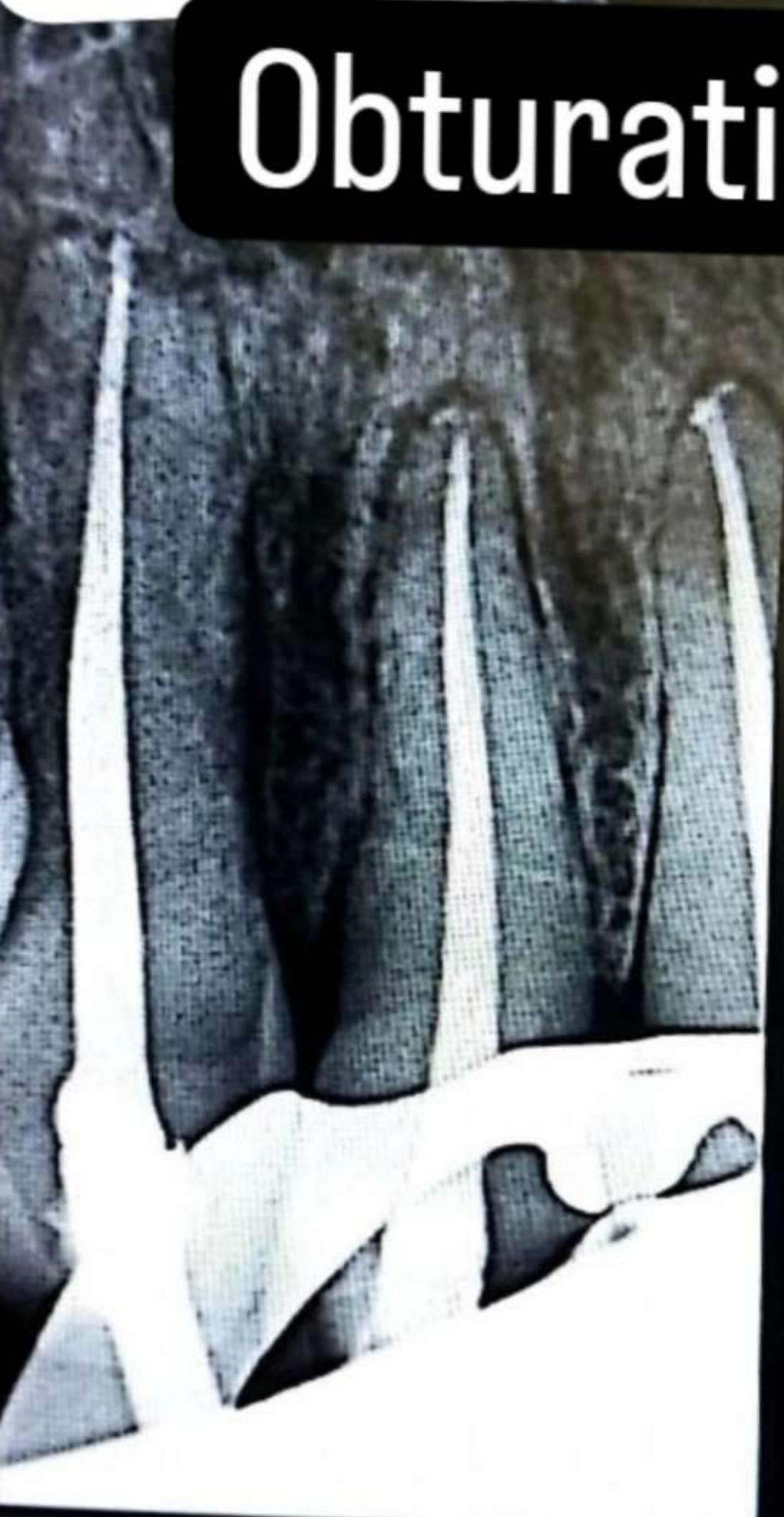

Working length

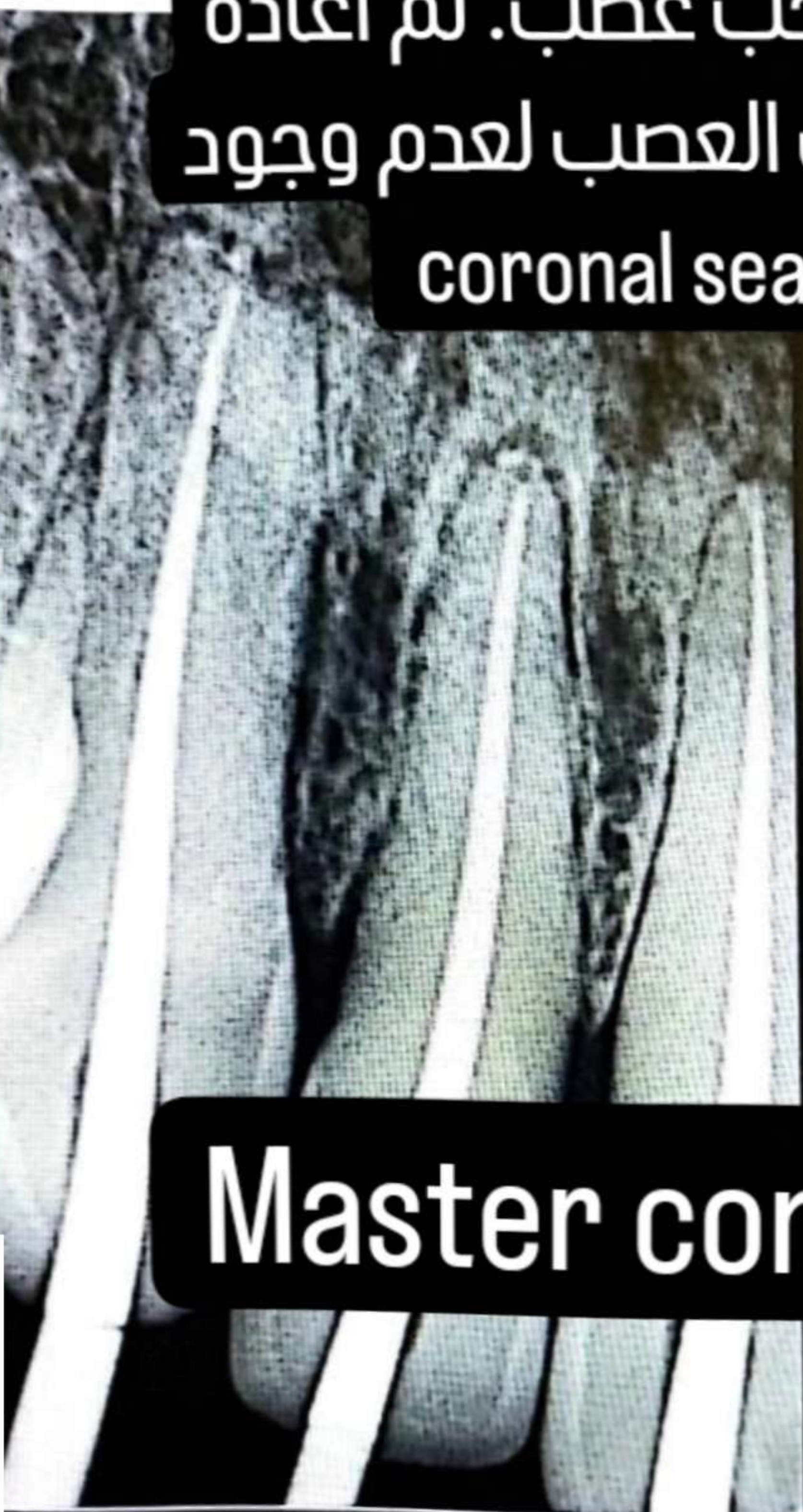After removing the GP

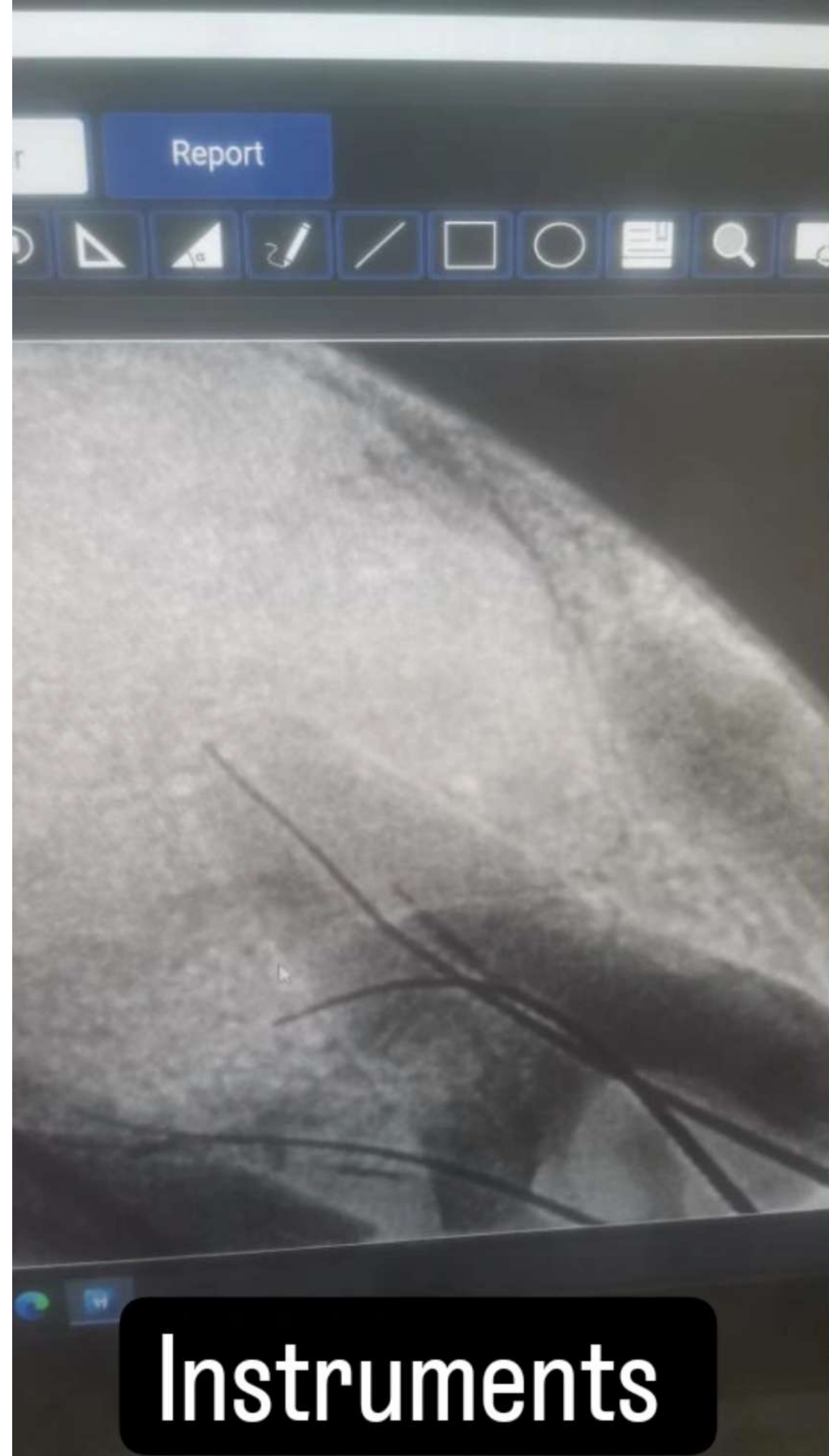

Obturation

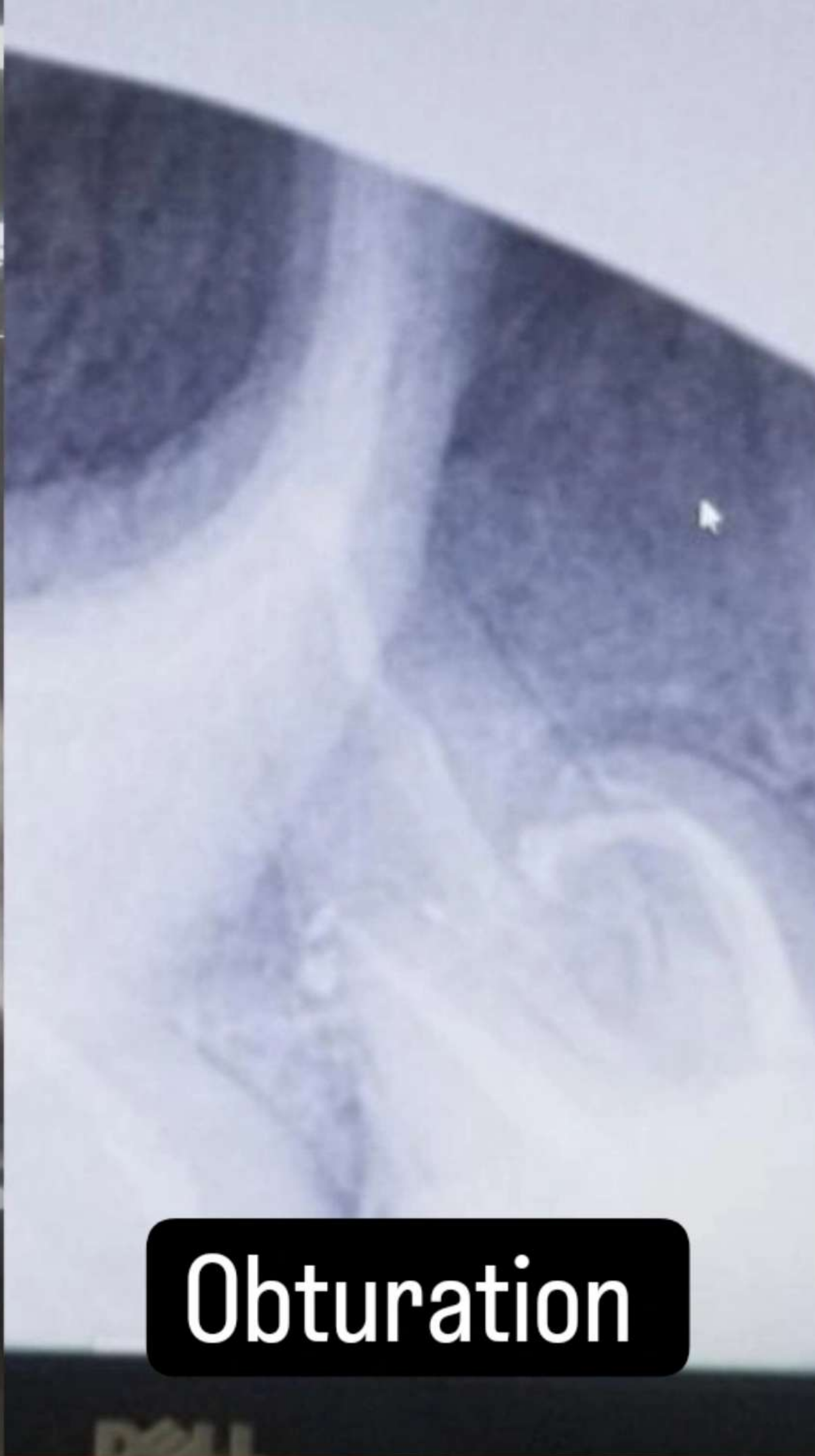


Master cone

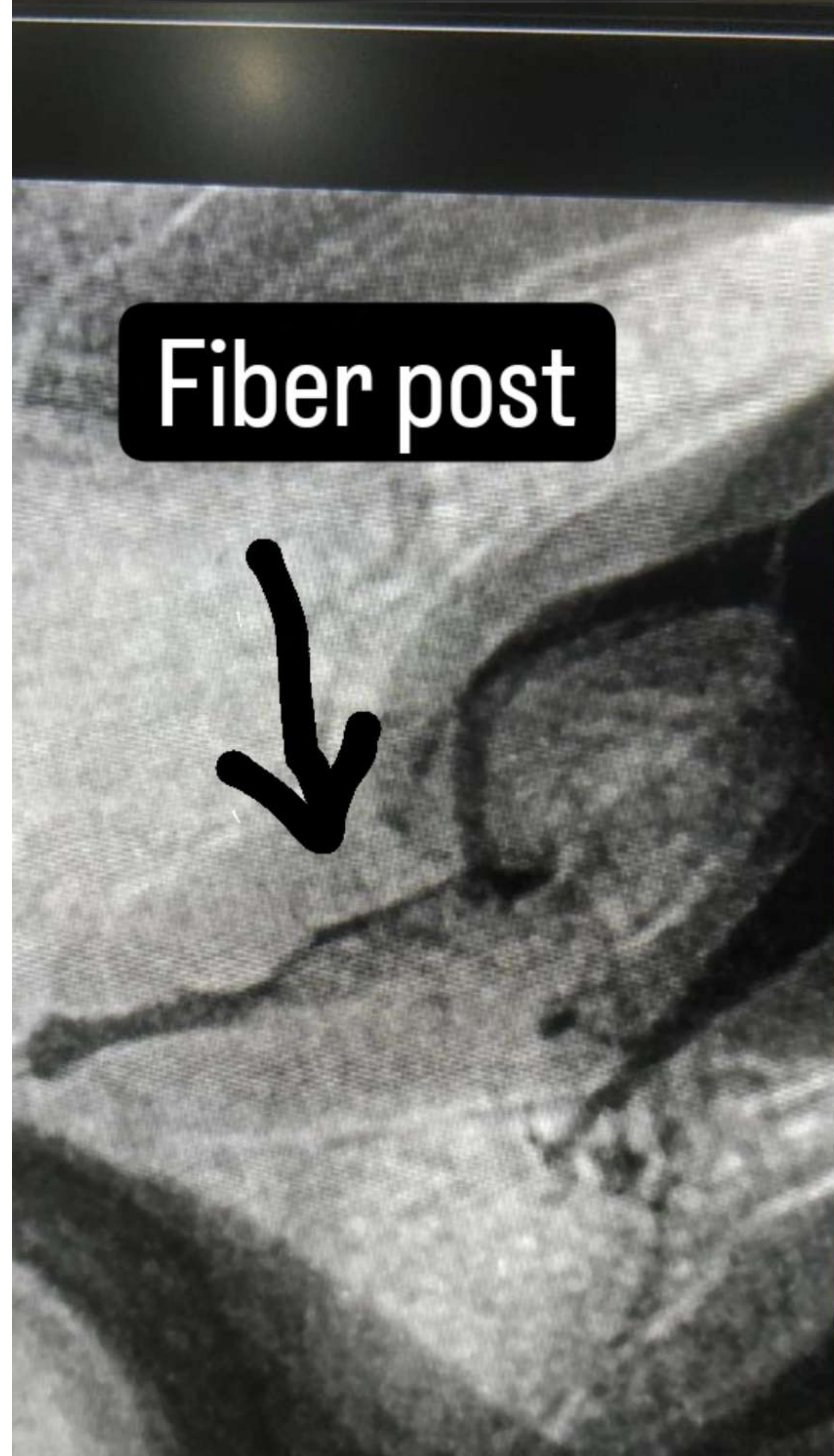




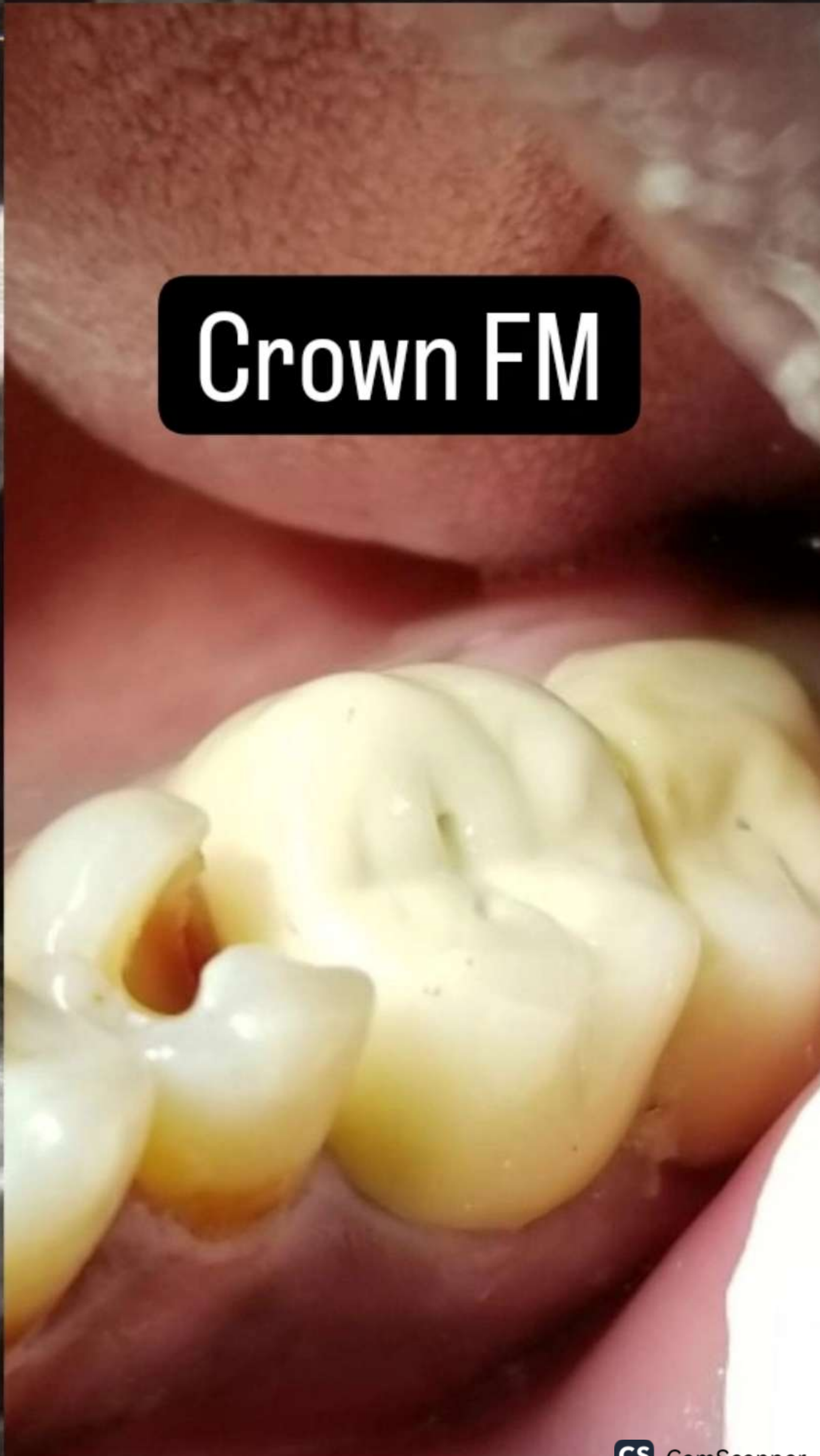Instruments



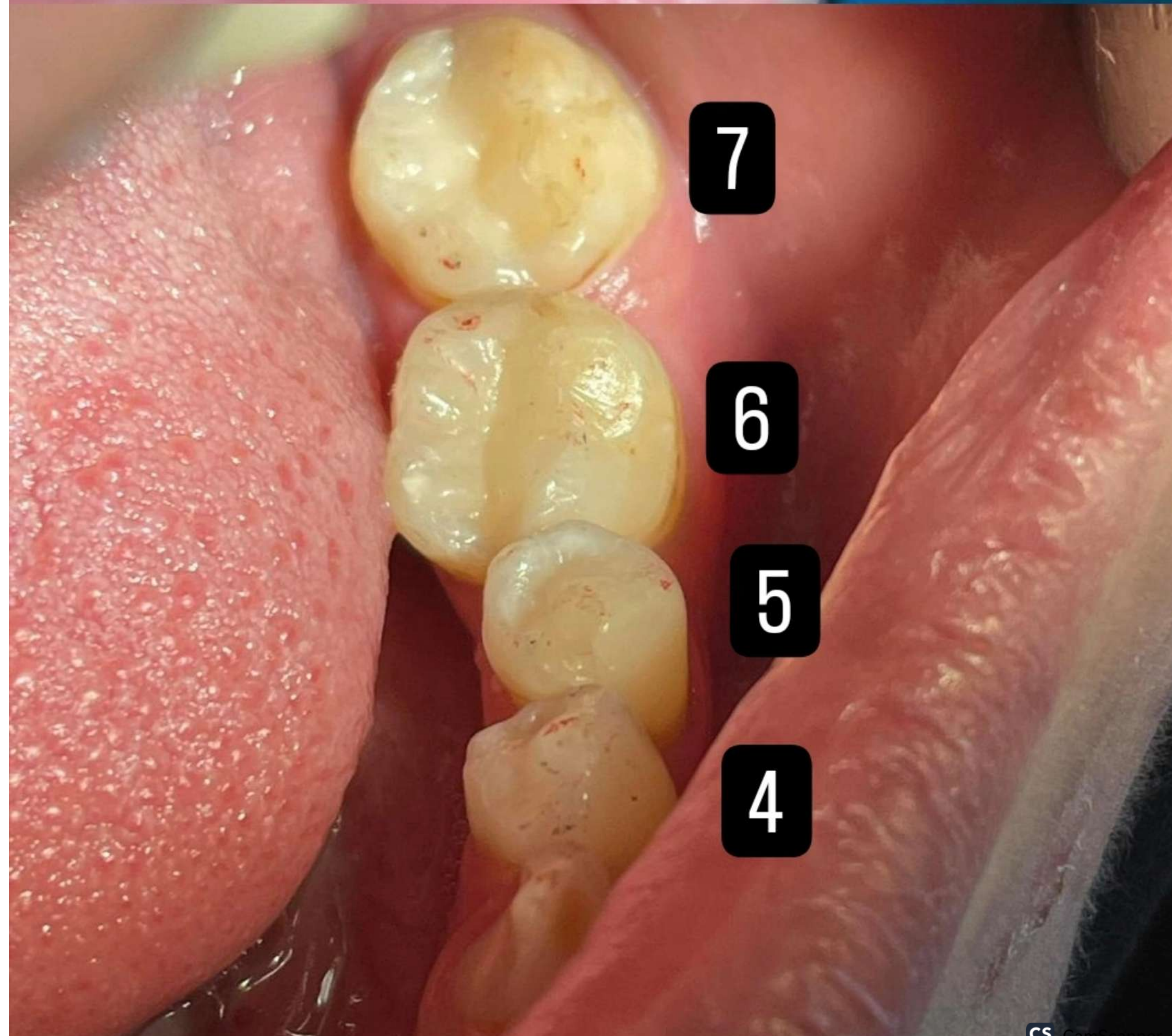
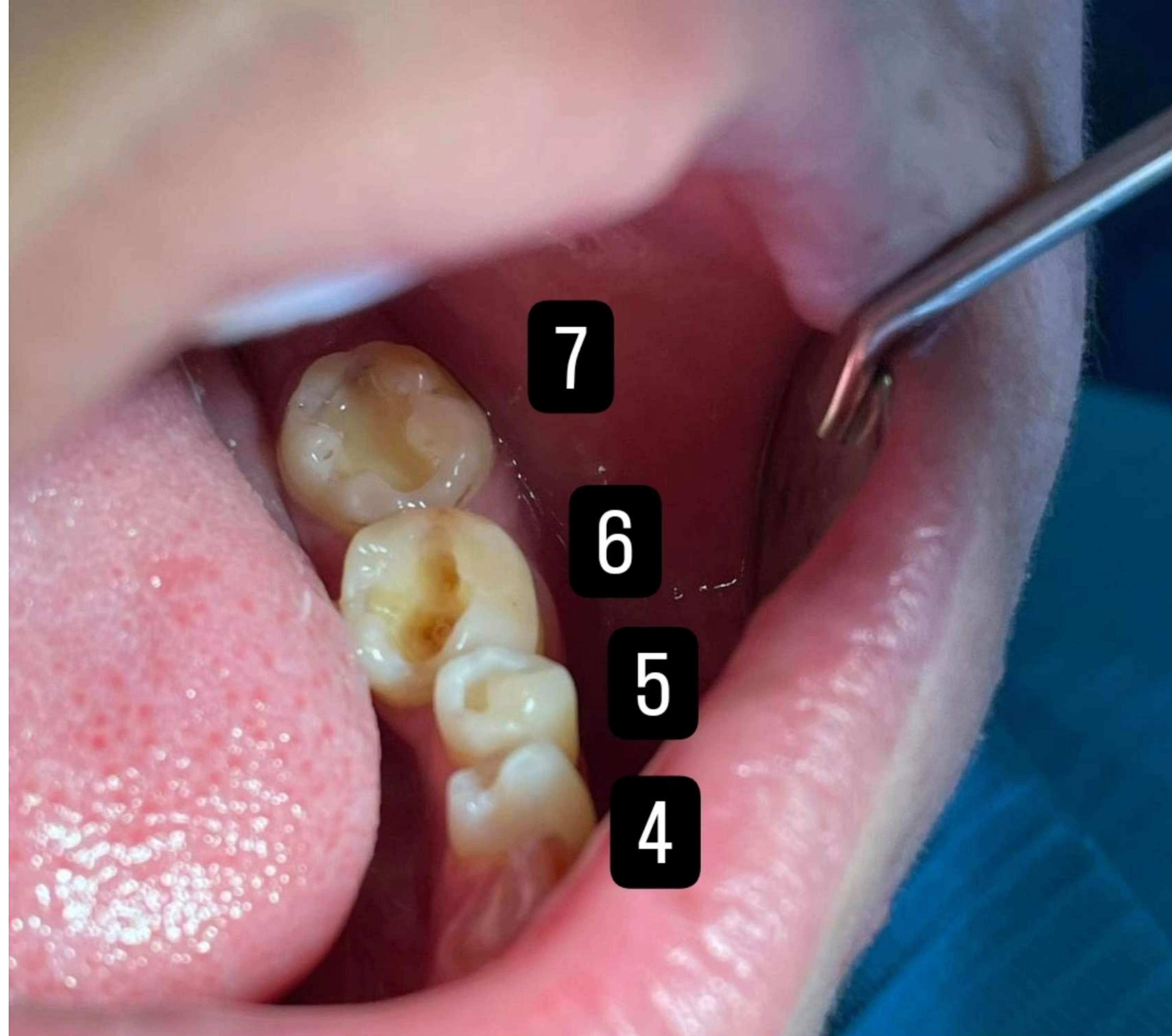
Obturation

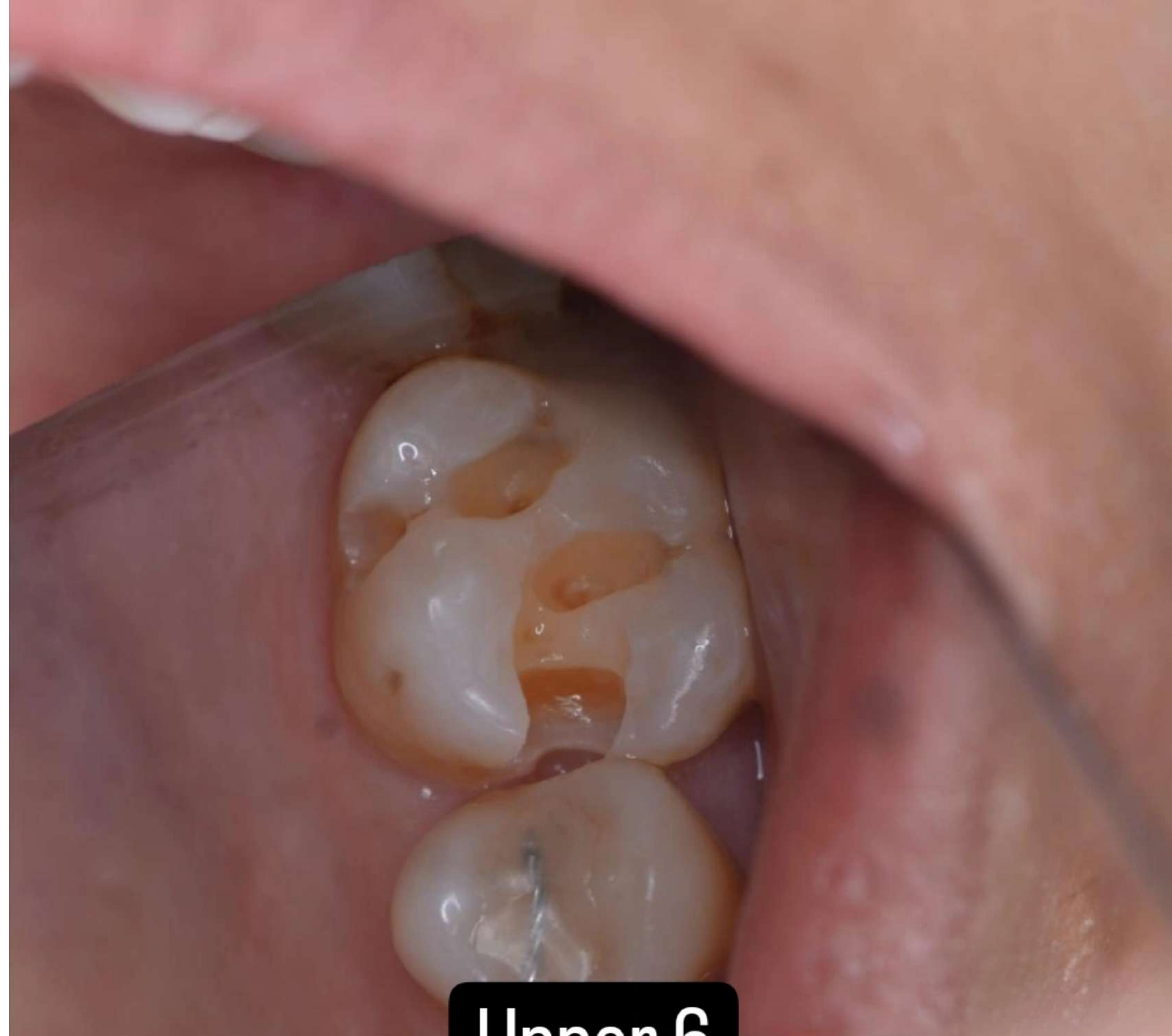

Fiber post

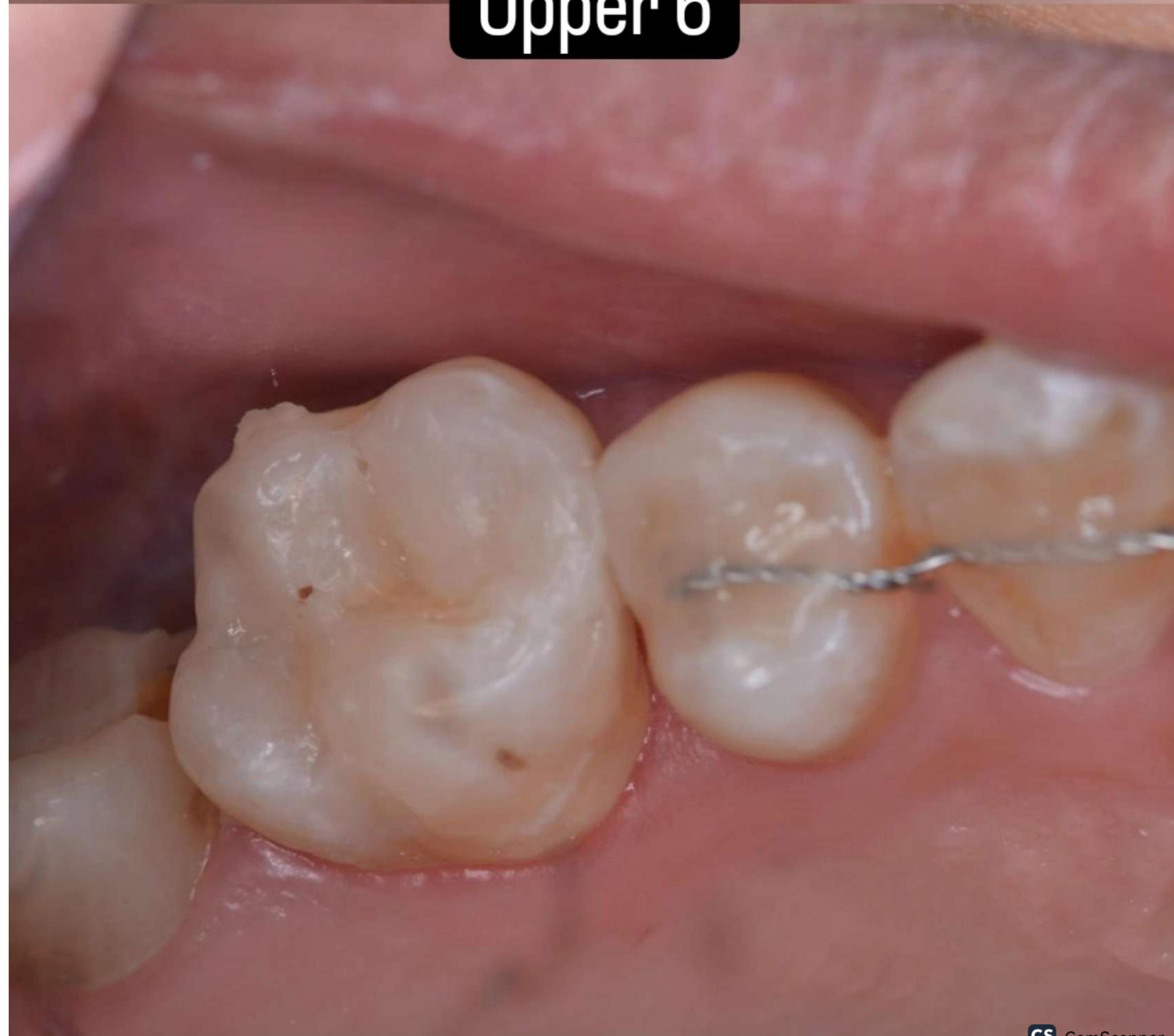

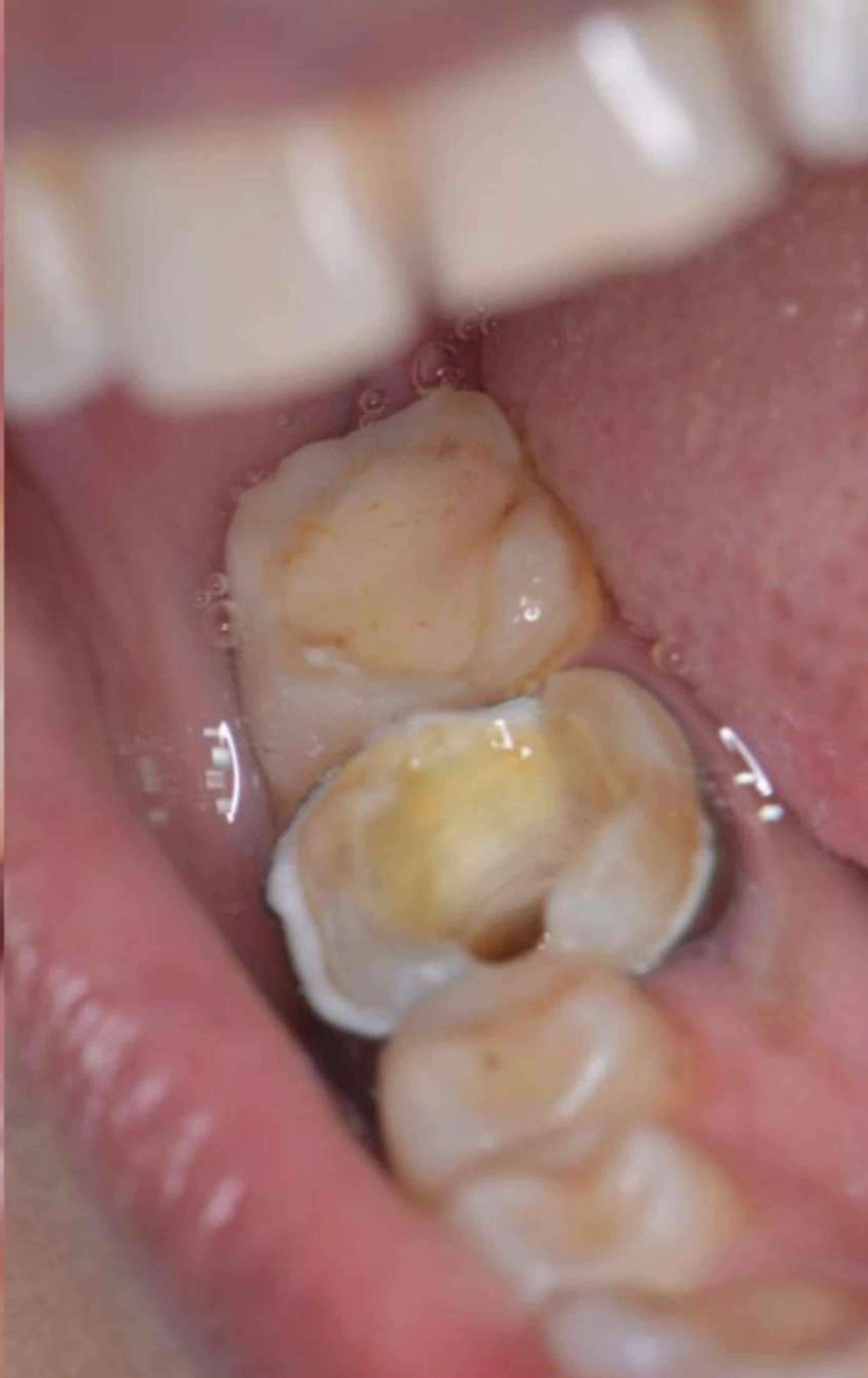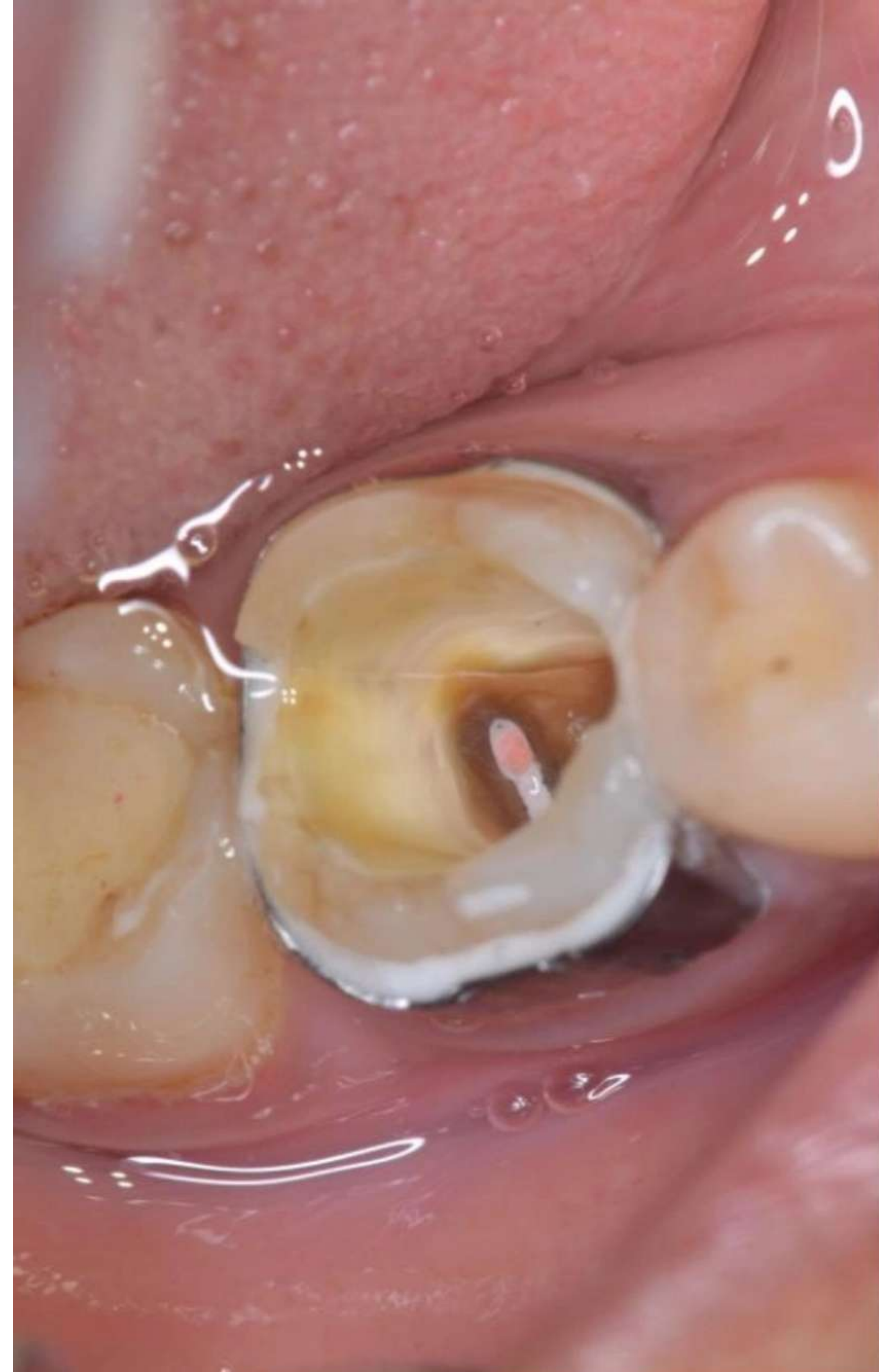Crown FM



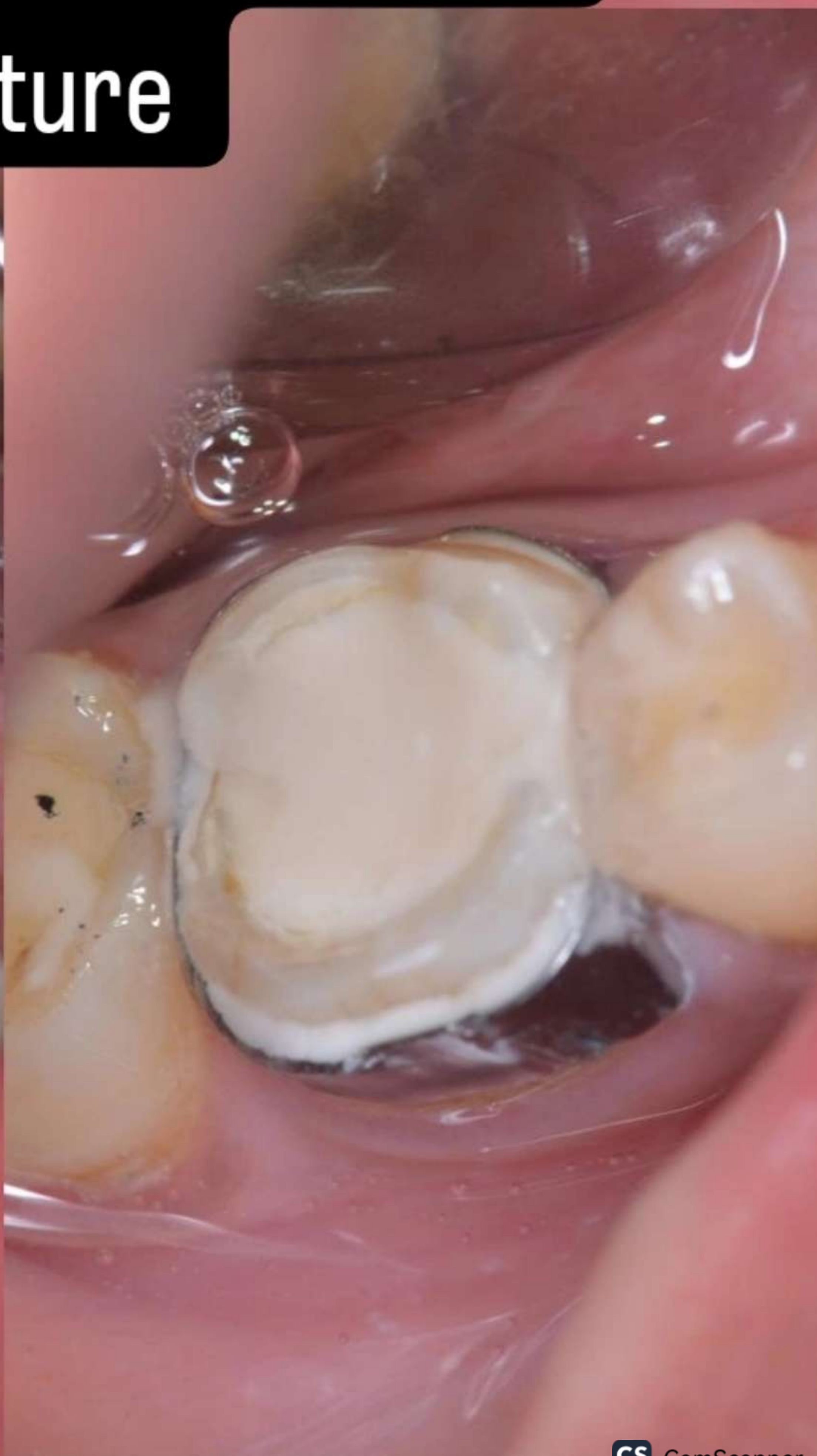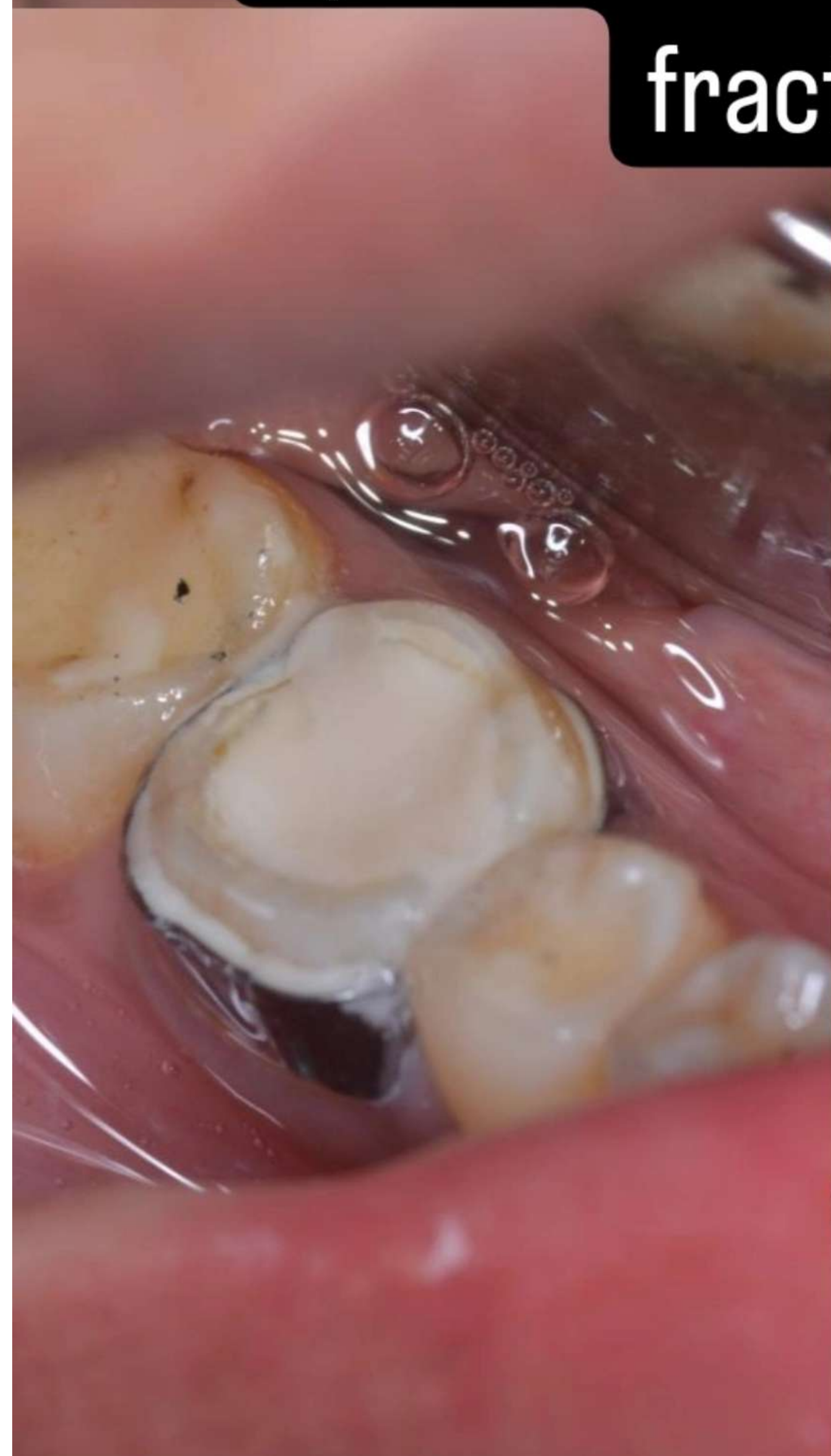


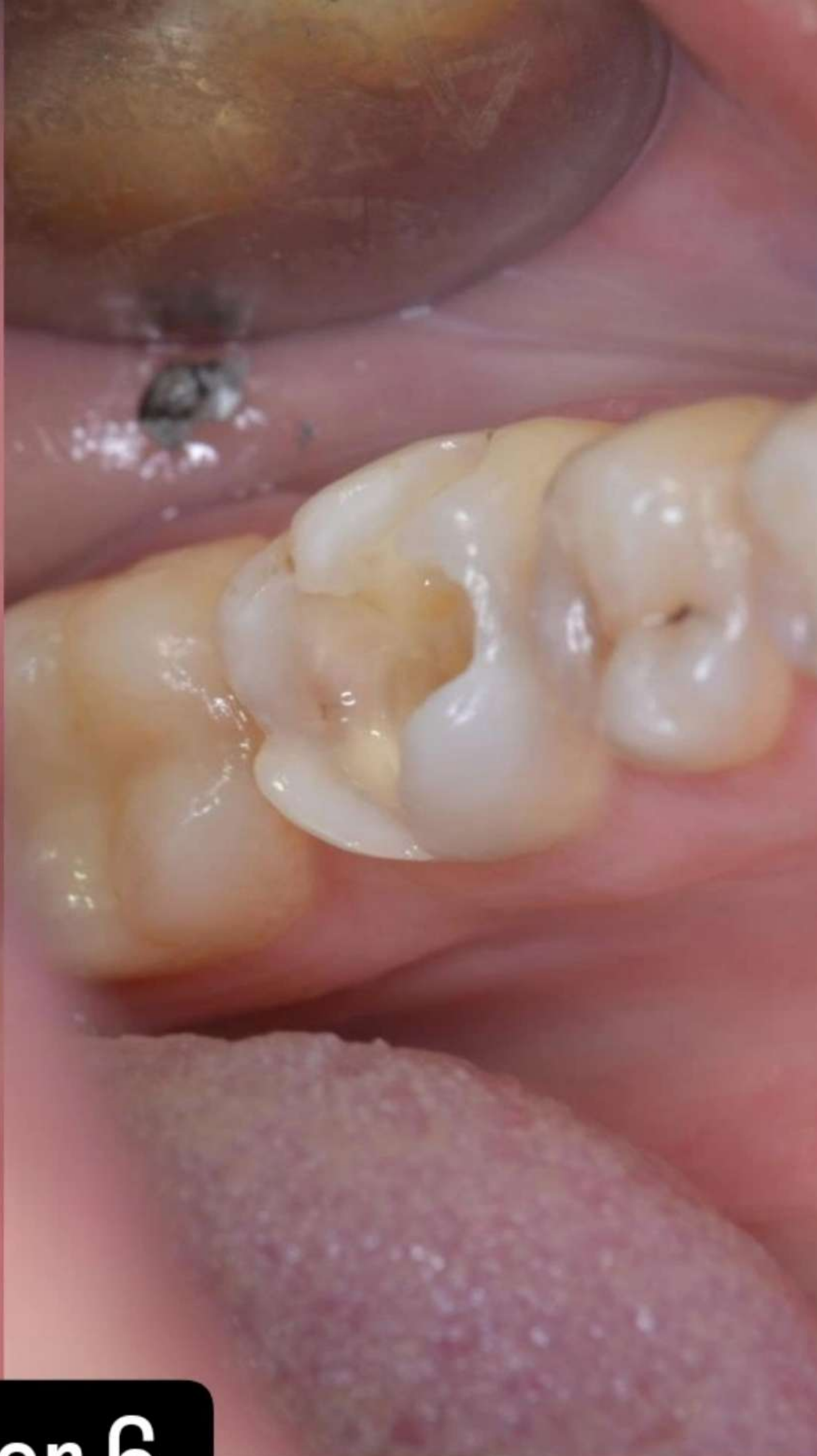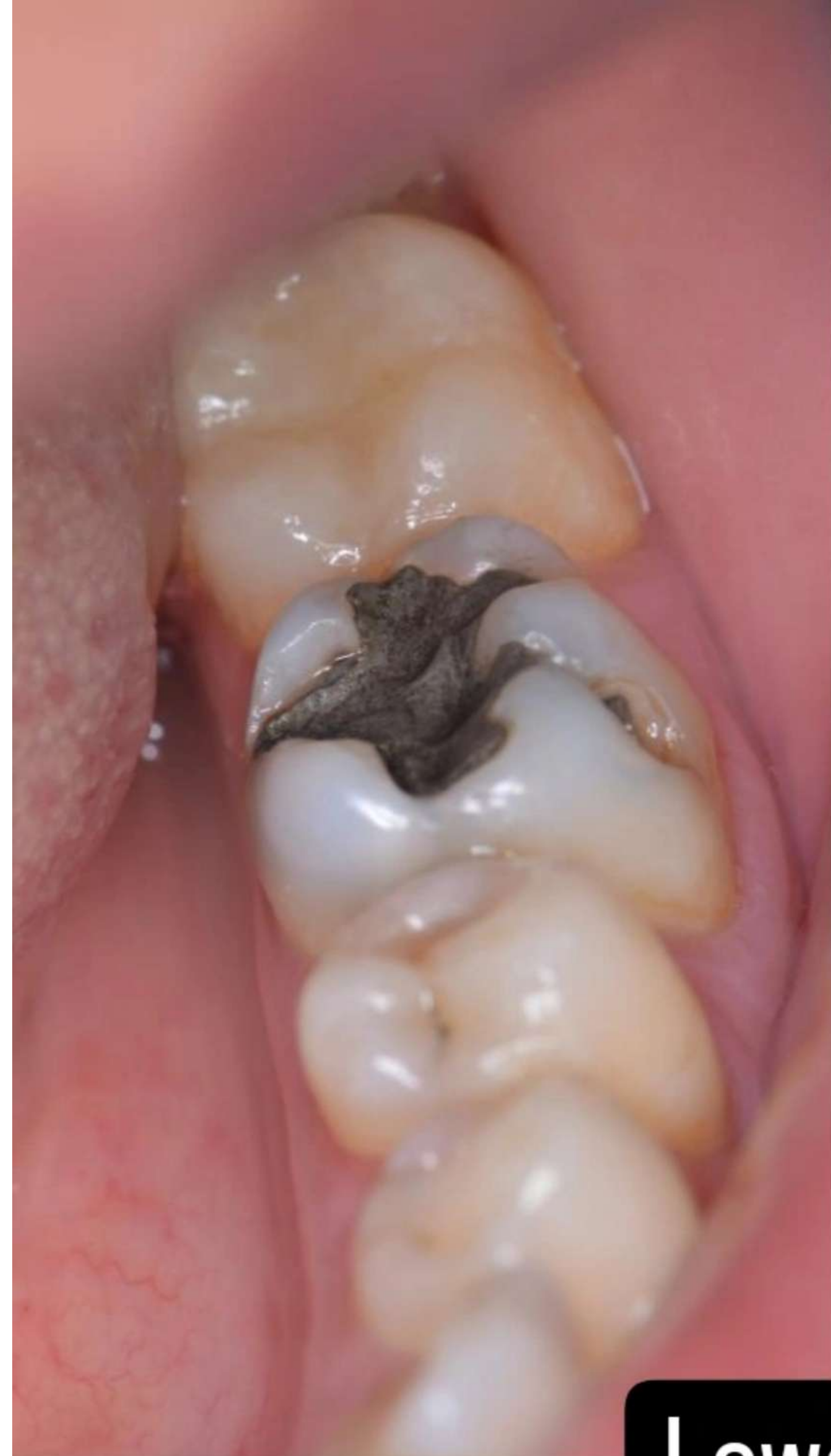
Upper 6



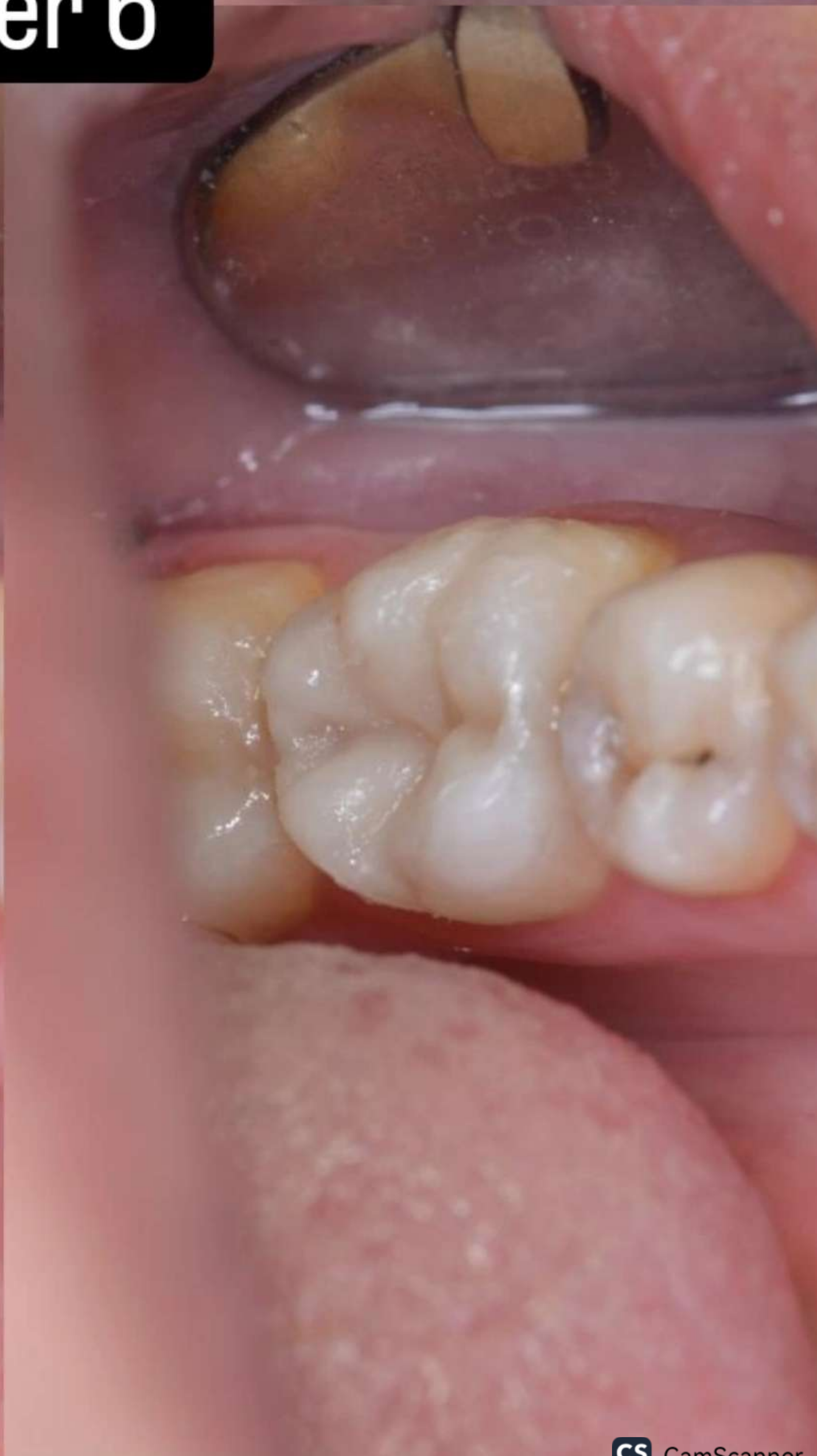
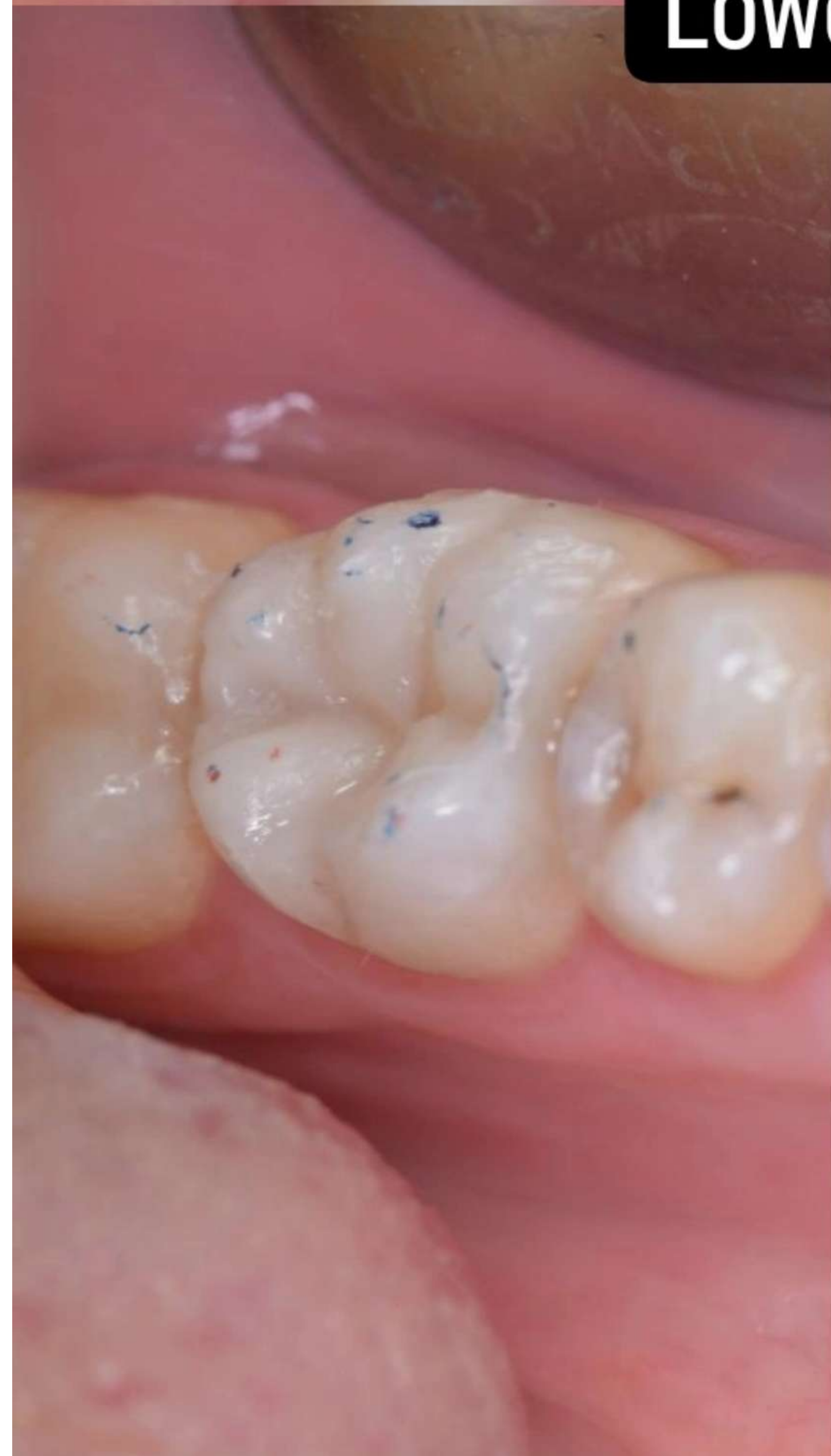
Special case with horizontal fracture

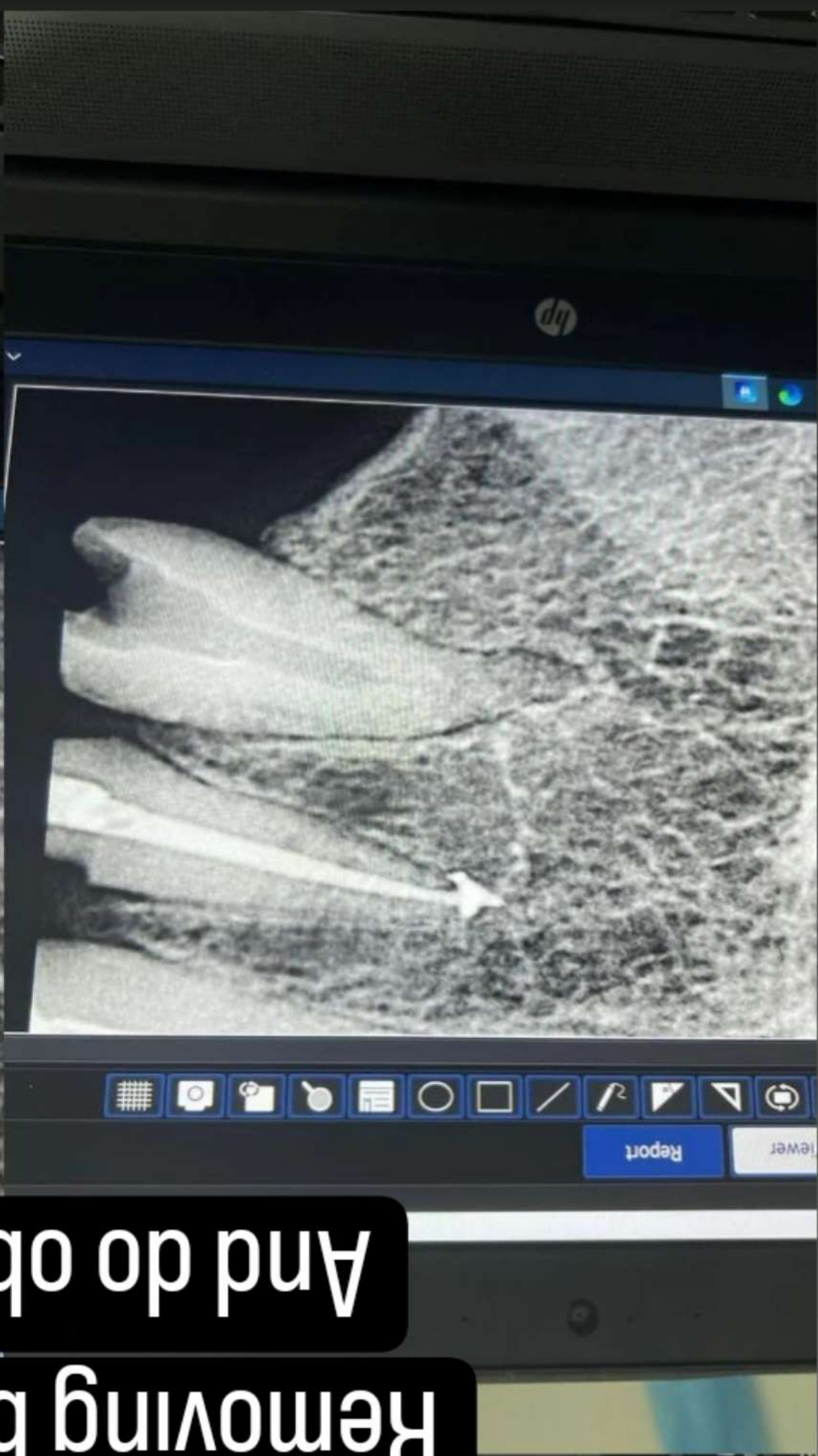
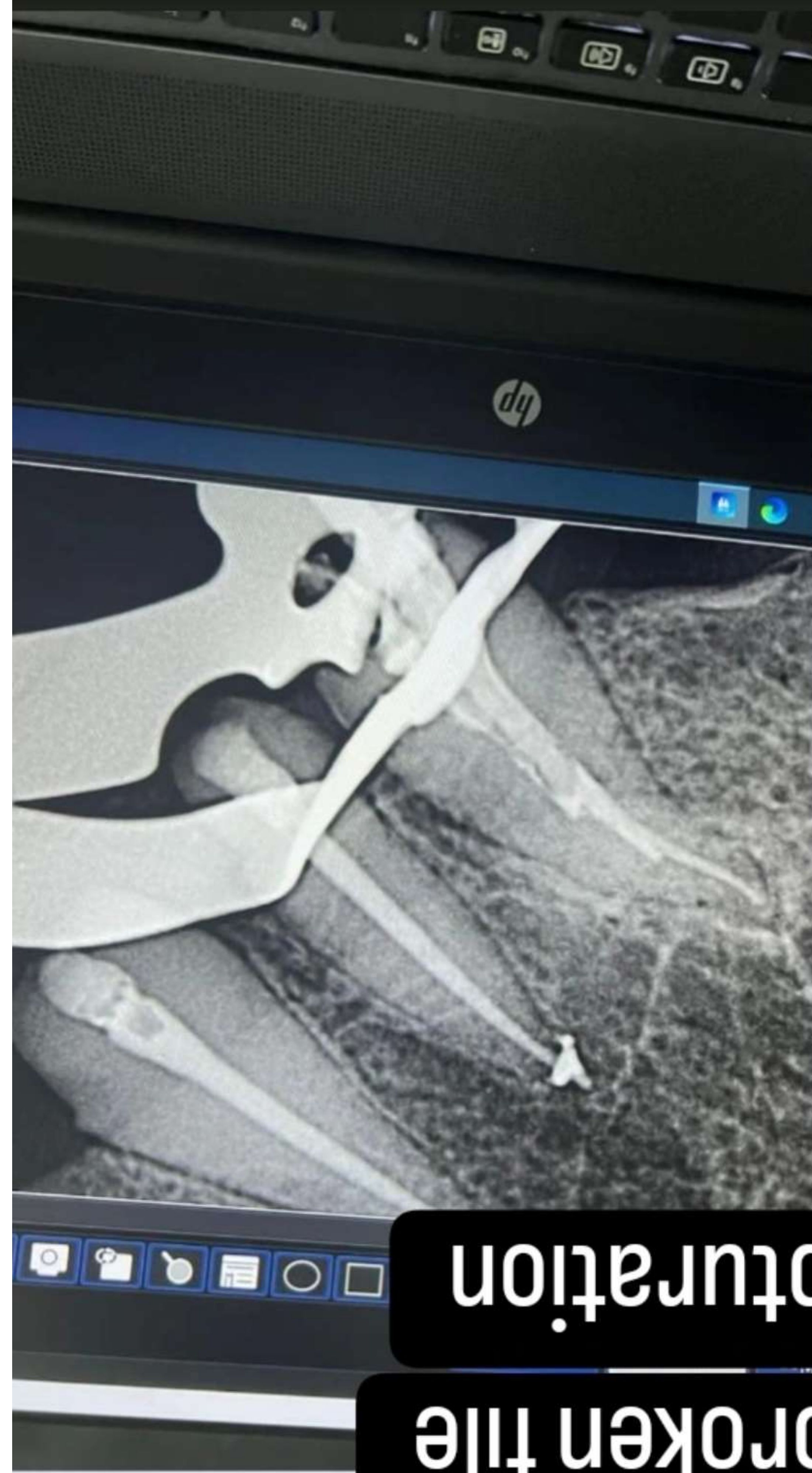
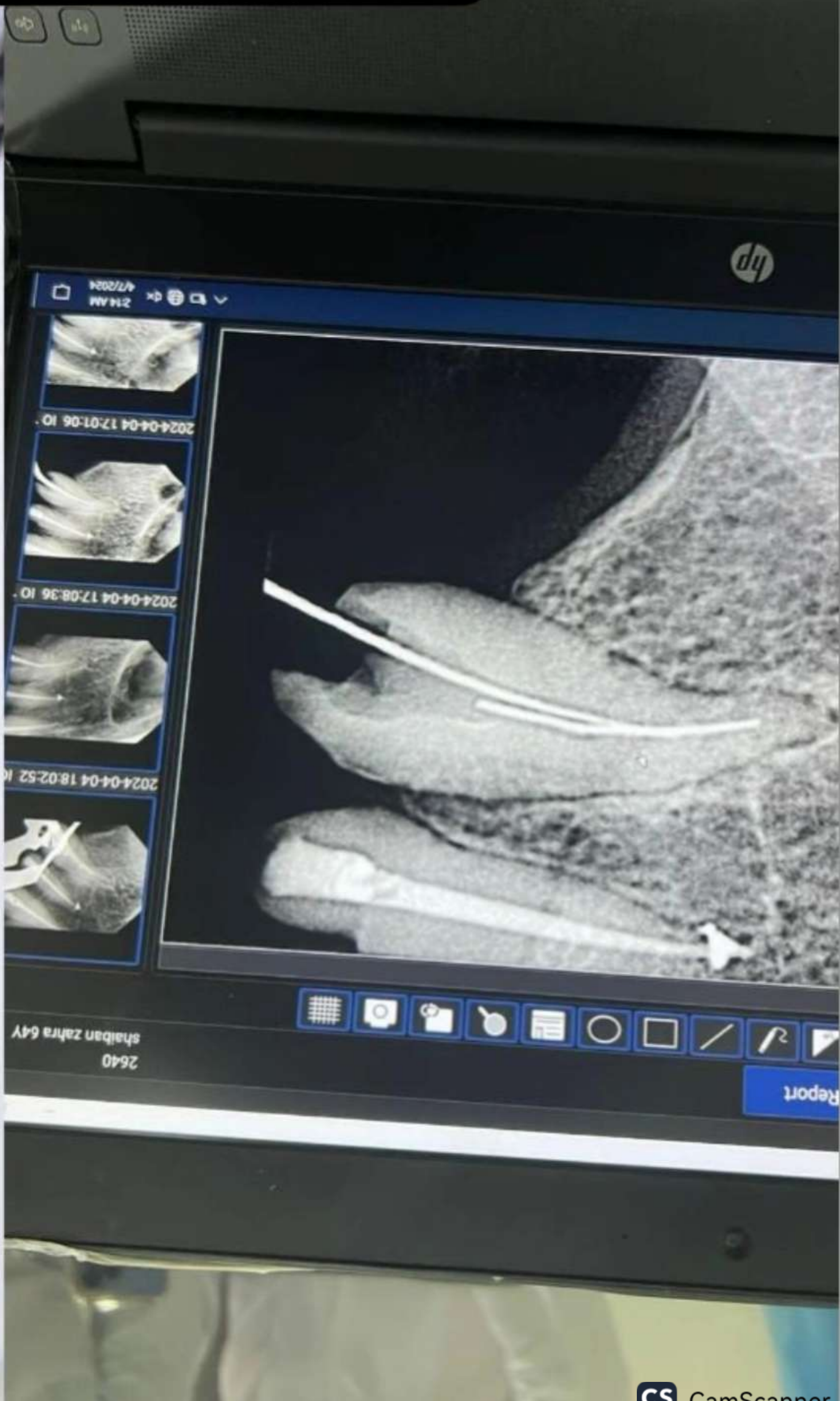

Lower 6



Removing broken file And do obturation

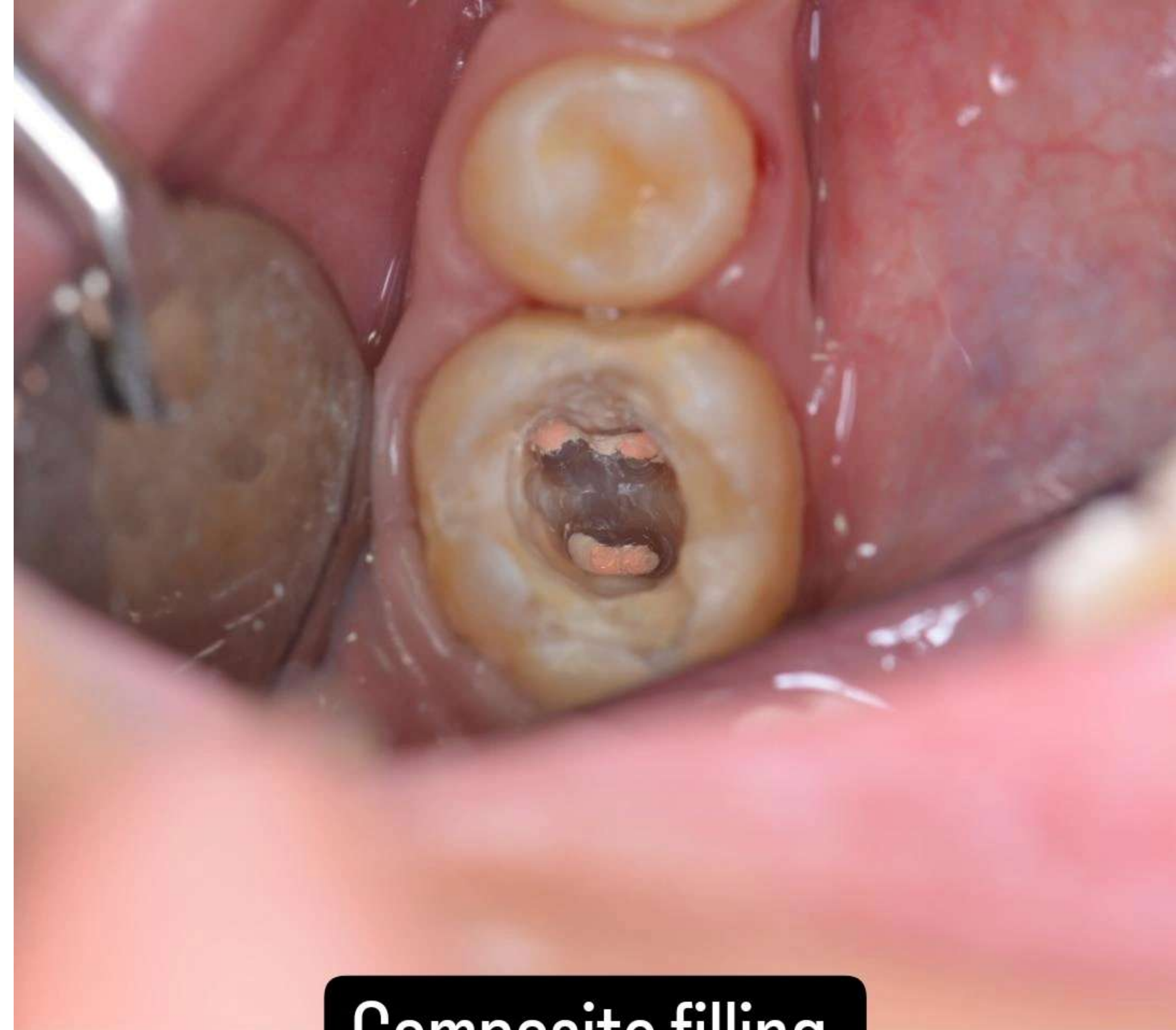



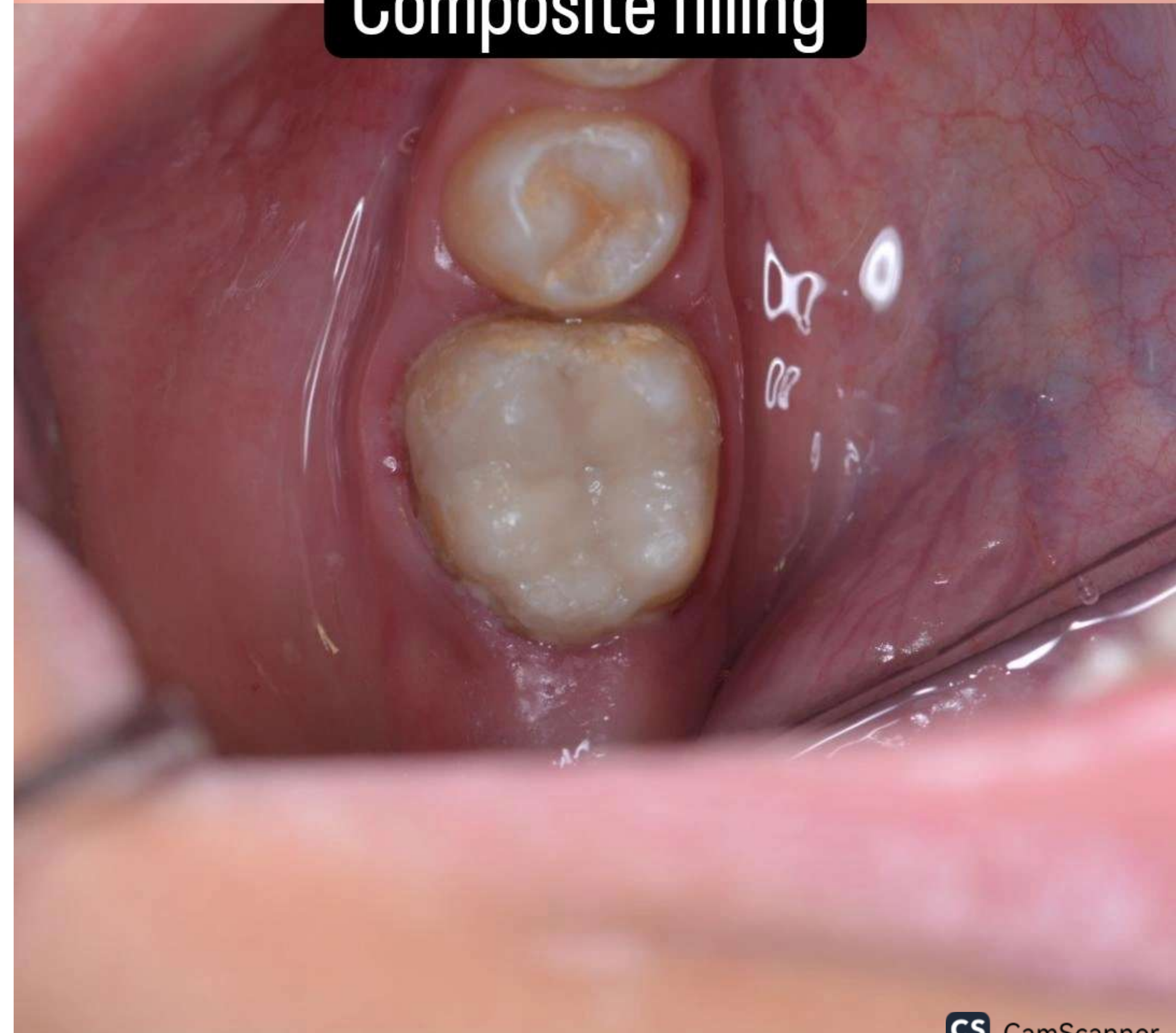Composite filling upper 6

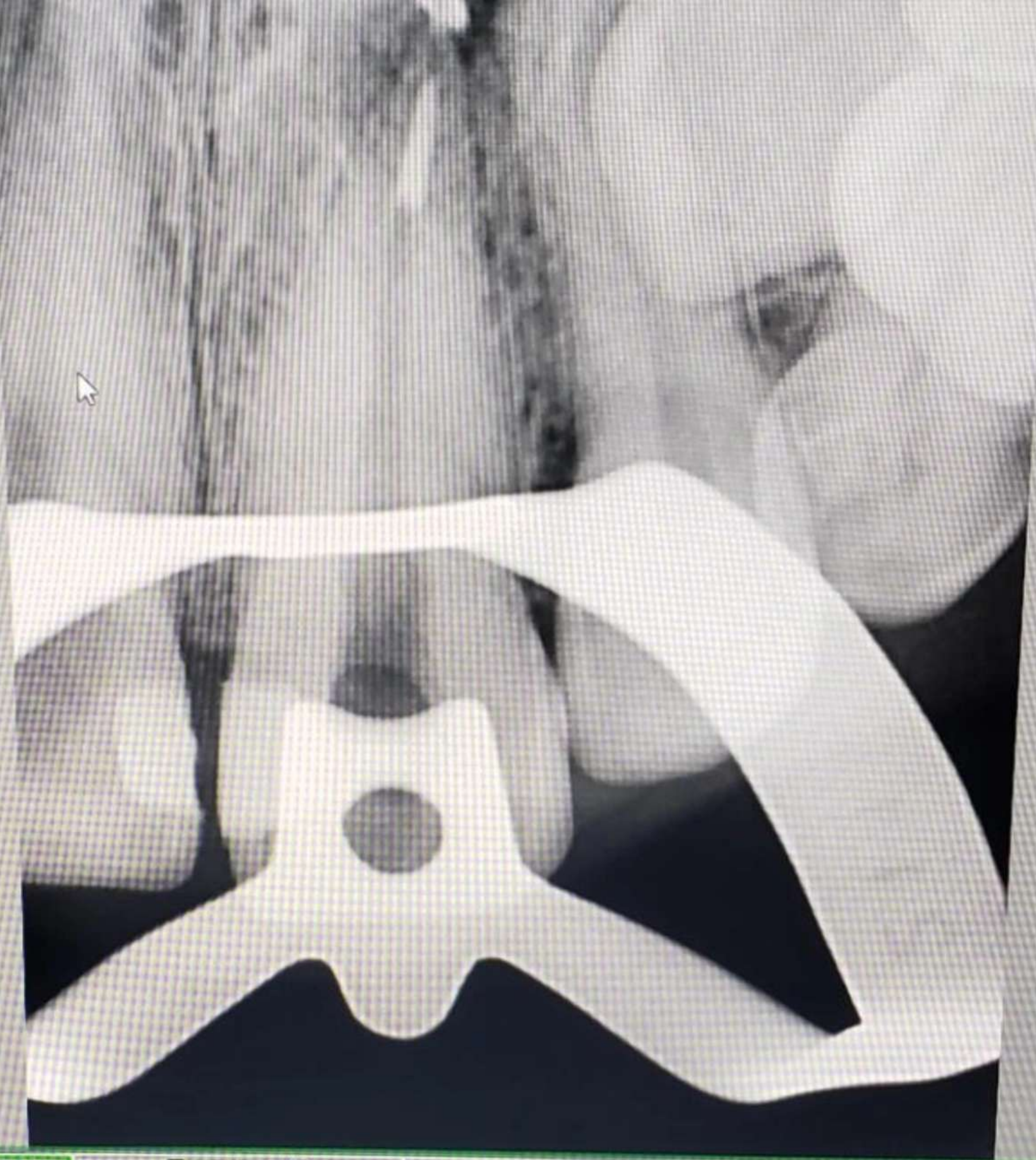

The image is a vertical composite of two close-up photographs of a person's upper teeth. The top photograph shows a central incisor with a large, light-colored composite filling. The filling has a smooth, polished surface and a shape that follows the natural contour of the tooth. The surrounding gingival tissue is pink and appears healthy. The bottom photograph shows the same central incisor, but with a different filling. This filling is also light-colored but has a more textured, slightly irregular surface. There are some small, dark blue or black specks visible on the filling and the adjacent teeth. The gingival tissue in the bottom photograph also appears healthy.



Composite filling





Thermal obturation

